Pelvic Actinomycosis; the Disease for Which Diagnostic and Therapeutic Delay is Still Being Experienced

Pelvik Actinomycosis; Tanısal ve Tedavisel Gecikmenin Halen Yaşandığı Hastalık

Pelvik Actinomycosis / Pelvik Actinomycosis

Dinç Süren[1], Mustafa Yıldırım[2], Arsenal Sezgin Alikanoğlu[1], Ahmet Arda Gökay[1], Cem Sezer[1],
[1]Department of Pathology, [2]Department of Oncology, Antalya Education and Research Hospital, Antalya, Turkey

Bu yayın 21.Ulusal Patoloji Kongresinde poster olarak sunulmuştur (16-20 Kasım 2011 tarihli, İzmir)

Özet

Actinomyces mukozal alanlarda normal flora üyesi olarak bulunan gram-pozitif bakteridir. Beklenmeyen yerleşimden dolayı, pelvik olguların yarısından fazlasında ön tanı malignite olmakta ve bu hastalara gereksiz genişletilmiş cerrahi uygulanmaktadır. Bu yayında, klinik preoperatif tanısı malignite, postoperatif histopatolojik tanısı pelvik Actinomycosis olan abdominal kitlesi bulunan premenopozal kadın olgusunu sunuyoruz. Her ne kadar klinik görünüm maligniteyi andırsa da, rahim içi araç (RİA) kullanım öyküsü bulunan hastada, pelvik Actinomycosis mutlaka düşünülmelidir. Tanı konduktan sonra enfeksiyon odağı olan RİA çıkarılmalı ve uzun dönem yüksek doz penisilin teadavisi uygulanmalıdır. Cerrahi eğer malignite kesin olarak ekarte edilemiyorsa, apse drenajı gerekli ise ve nekrotik dokuların ve sinüslerin çıkarılması gerekliyse yapılmalıdır.

Anahtar Kelimeler

Actinomycosis; Pelvik Kitle; Tümor Benzeri; Tedavi

Abstract

Actinomyces is a gram-positive bacteria, which presents as a normal flora member at mucosal areas. Because of its unexpected localization, malignancy is the clinical prediagnosis for more than half of the pelvic cases, and unnecessary extended surgery is performed in these patients. In this report, we present a case of a premenopausal woman with an abdominal mass, who had a pre-operative diagnosis of malignancy, but a post-operative histopathologic diagnosis of pelvic Actinomycosis. Although the clinical appearance resembles a malignancy, for the patient with intrauterine device (IUD) history, distinctive aspect of the pelvic Actinomycosis should absolutely be considered. After the diagnosis is established, the infection source IUD should be removed and long term high dose penicillin therapy should be administered. Surgery should be considered only if malignancy cannot be certainly excluded, if abscess drainage is necessary and if necrotic tissues and sinuses should be removed

Keywords

Actinomycosis; Pelvic Mass; Mimicking Tumour; Treatment

DOI: 10.4328/JCAM.1150 Received: 13.06.2012 Accepted: 07.07.2012 Printed: 01.09.2015 J Clin Anal Med 2015;6(5): 702-704
Corresponding Author: Dinç Süren, Department of Pathology, Antalya Education and Research Hospital, 07050 Antalya, Turkey.
GSM.: +905304199401 F.: +90 2422494462 E-Mail: dinc_suren@yahoo.com

Introduction

Actinomyces is a non-sporing, slow growing absolute or facultative anaerobic gram-positive bacteria, which presents as a normal flora member at mucosal areas [1]. Actinomyces species secrete a polysaccharide that binds the bacilli's filaments, forming characteristic sulfur granules. These granules are considered diagnostic of Actinomyces, but can only be seen in 50% of cases [1]. They can be isolated as flora member in the oral and bronchial mucosa, gastrointestinal system and female genital tract [1]. From a population-based widespread survey, incidence of Actinomyces infection was obtained as approximately 1/year/100000. When distribution of the cases are examined, the cervicofacial region (42%), pelvis (32%), lachrymal duct (14%), abdomen (11%) and thorax (%2) are the most commonly affected infection focuses [2]. However in the literature, Actinomyces is also encountered at interesting localizations. Among them, breast, liver, thyroid, gallbladder, testis and kidney are remarkable. In more than half of the pelvic Actinomycosis cases, malignancy is the clinical prediagnosis.There are rare pelvic Actinomycosis cases that can be preoperatively diagnosed. We present a pre-menopausal female with an abdominal mass. The preoperative diagnosis was malignancy, but postoperative histopathologic diagnosis is compatible with pelvic Actinomycosis.

Case Report

At physical examination of the 42 years-old premenopausal female patient, who applied to emergency department complaining of severe abdominal pain, a mass in the abdomen was found and acute abdomen were diagnosed. In complete blood count, WBC was obtained as 21000/mm³ (4000-10000/mm³), and Hg as 5.3 g/dL mm³ (11.5-17.0 g/dL). Blood biochemistry was normal except slightly low values of sodium and potassium. The patient had no history of diabetes mellitus, abdominal surgery or appendectomy. Transvaginal ultrasonography revealed a necrotic mass attached to the sigmoid colon suggesting an origin of left ovary. The patient was promptly taken under operation. During the laparotomic exploration, the frozen pelvis appearance were seen and necrotic-purulent mass 7 cm in the biggest diameter were totally excised. In pathologic examination of the specimen, besides the fibroblastic and capillary proliferation, lymphocyte and histyositic aggregates and dense neutrophilic leukocyte infiltration were observed (Figure 1). In between the neutrophilic abscess, sulphure granules compatible with Actinomyces were seen (Figure 2). After exclusion of malignancy findings at the fibroblastic natured cells such as nuclear atypia and mitotic activity, the case was evaluated in compliance with pelvic Actinomycosis. After the diagnosis, the patient was interrogated for IUD usage, and it was learned that she had a history of IUD usage for 6 years. The IUD was removed and the patient, who went through intravenous Ceftriaxone 2x1gr administration for 1 week after the operation, was discharged due to her good general condition who was scheduled 2g/day penicillin V oral therapy for 4 months.

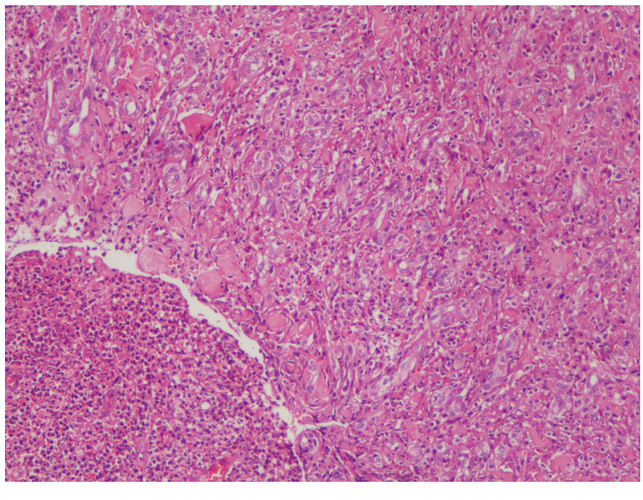

Figure 1. Capillary and fibroblastic proliferation together with abscess focus (Hematoxylin and Eosin x40)

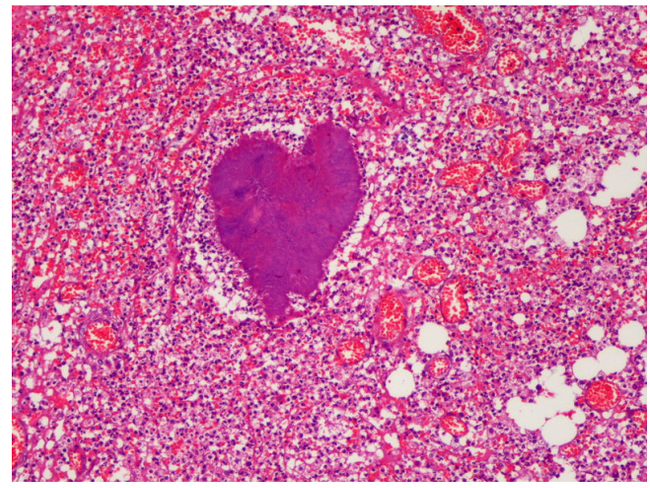

Figure 2. Characteristic sulphure granules formed by Actinomyces (Hematoxylin and Eosin x100)

Discussion

Pelvic Actinomycosis cases have a median patient age of 51 (range, 36-66 years). In 93.8% of the patients IUD usage, in 68.8% of them D/C history and in 31.3% previous abdominal surgery were determined [2]. Actinomyces can be determined via routine vaginal examination in 10% of the asymptomatic IUD users and in 25% of the symptomatic ones [3]. In IUD user women, Actinomyces increases slightly at the end of the second year [3]. Thread part of IUD forms nidus for Actinomyces colonization and erosion developing afterwards as a result of traumatization of endometrium with IUD provides a suitable environment for Actinomyces development [1]. The endometritis and inflammation that developed spread to adjacent structures and form adhesions. Resulting uni-multiloculer cysts and frozen pelvis, mimics the gynecological malignancies, particularly the ovarian tumours. During development of pelvic infection, besides uterus borne ascending development, direct spreading of infection originating from the illeocecal region or diverticulitis are other frequently observed spreading mechanism [1]. Most frequently encountered symptoms of pelvic actinomyces are fever, abdominal pain and abnormal vaginal bleeding and most frequently encountered initial laboratory abnormalities are normochromic anemia and leucocytosis [4]. Also high CA-125 and CA-19.9 levels can be observed in the cases. Clinical impressions and also high level of tumour markers misdirect the surgeons for a diagnosis of malignancy [4]. Diagnosis delay is frequent for these cases (median 5 months) [1]. There are rare cases that can be preoperatively diagnosed. These cases diagnosed by transcutaneous computed tomography guided

needle biopsy. Our patient applied to emergency department with acute abdomen, unfortunately we did not perform a needle biopsy. For the patients who underwent emergent surgery because of peritonitis, median diameter of pelvic mass was determined as 7.0 cm (range, 2.5-10.5). After the diagnosis was established, the infection source IUD should be removed and long term high dose penicillin therapy should be administered. In the series of Sung et al. abdominal Actinomycotic masses were surgically removed and long term antibiotic treatment was administered (mean 4.2 months; range, 0.5-7.0 months). Recurrence was not seen in any patient after a median follow up of 30.0 months (mean 35.5 ± 14.8 months, range, 10.0-70.0 months) [4]. Suggestion of Hamid et al. was 20 million IU/day penicillin G therapy for 4 weeks followed by 2-4 g/day penicillin V oral antibiotherapy for 12 months [5].

In conclusion, although the clinical appearance resembles a malignancy and also tumour indicators like CA-125 and CA-19.9 are in high levels, for the patient with IUD history, distinctive aspect of the pelvic Actinomycosis should absolutely be considered and if possible, screening method guided fine needle biopsy with should be performed. Surgery should be considered only if malignancy cannot be certainly excluded, if abscess drainage is necessary and if necrotic tissues and sinuses should be removed. Thus, treatment related morbidity may be reduced too.

Competing interests

The authors declare that they have no competing interests.

References

1. Garner JP, Nacdonald M, Kumar PK. Abdominal actinomycosis. Int J Surg 2007;5(6):441-8.
2. Baldursdóttir E, Jónasson L, Gottfredsson M. The many faces of Actinomycosis. Results from a retrospective study in Iceland, 1984-2007. Laeknabladid 2010;96(5):323-8.
3. Mali B, Joshi JV, Wagle U, Hazari K, Shah R, Chadha U, Gokral J, Bhave G. Actinomyces in cervical smears of women using intrauterine contraceptive devices. Acta Cytol 1986;30(4):367-71.
4. Sung HY, Lee IS, Kim SI, Jung SE, Kim SW, Kim SY, Chung MK, Kim WC, Oh ST, Kang WK. Clinical features of abdominal Actinomycosis: A 15-year experience of a single institute. Korean Med Sci 2011;26(7):932-7.
5. Hamid D, Baldauf JJ, Cuenin C, Ritter J. Treatment strategy for pelvic Actinomycosis: case report and review of the literature. Eur J Obstet Gynecol Reprod Biol 2000;89(2):197-200.

How to cite this article:
Süren D, Yıldırım M, Alikanoğlu AS, Gökay AA, Sezer C. Pelvic Actinomycosis; the Disease for Which Diagnostic and Therapeutic Delay is Still Being Experienced. J Clin Anal Med 2015;6(5): 653-5.