Oblique MR Imaging in Cervical Spine Surgery

Omurga Cerrahisinde Oblik MR Görüntüleme

Oblik MR / Oblique MR

Şimşek Hakan[1],Saglam Omer[2], Malkoç Ercan[3], Kaya Serdar[4]
[1]Kasımpasa Military Hospital, Neurosurgery Department, Beyoğlu, İstanbul, [2]Kasımpasa Military Hospital, ENT Department, Beyoğlu, İstanbul,
[3]Çorlu Military Hospital, Department of Urology, Tekirdağ, [4]GATA Military Medical Academy, Department of Neurosurgery, Etlik, Ankara, Turkey

Özet

Bu çalışmanın amacı, 45 derece oblik açıda çekilmiş manyetik rezonans (MR) görüntülemenin karmaşık servikal patolojilerde ve ameliyat sonrası değerlendirmedeki faydasını vurgulamaktır. 2002 ve 2007 yılları arasında dejeneratif servikal omurga bozukluklarından dolayı 252 hastaya cerrahi müdahalede bulunduk. Bunların takiplerinde bazı hastalar devam eden kök ağrısından dolayı servikal spinal MR ile değerlendirildiler. Burada, servikal oblik MRın etkinliğini ortaya koymak için dört vaka takdim edilecektir. İlk vaka, ameliyat öncesi dönemde de cerrahi kararında oblik MR görüntülerinin önemini vurgulamaktadır. İkinci vakada, oblik görüntülere dayanarak reoperasyona karar verilmiştir. Üçüncü vaka implantların neden olduğu artefaktlara, ve bu durumda 45 derece oblik MR görüntülerinin faydasına dikkati çekmektedir. Dördüncü olguda, servikal implanta rağmen oblik kesitlerde foramenlerin sağlıklı değerlendirilebildiği görülmektedir. Ameliyat sonrası dönemde, alışılmış MR görüntülerinde herhangi bir patolojiye atfedilemeyen devam eden kök ağrısı olan servikal implantlı hastalar, oblik servikal MR'dan fayda sağlayabilirler.

Anahtar Kelimeler

Servikal Omurga; İmplant; Nöral Foramen; Oblik; Cerrahi

Abstract

Aim of this study was to appraise the efficacy of 45° oblique Magnetic Resonance (MR) Image in complicated cervical spinal pathologies and postoperative evaluation. Between the years 2002 and 2007 we practiced 252 surgical interventions due to degenerative cervical spinal disorders. In their follow-up, some of the patients were evaluated by oblique MR images because of persistent radiculopathy. Four cases were presented to notice efficacy of oblique MR imaging. First case emphasizes its importance also in decision of treatment in the preoperative period. In the second case, reoperation was decided regarding oblique MR images. Third case draws attention to the artifacts due to implants and efficacy of 45° oblique MR images in such circumstances. In the fourth case despite the implants, foramina could be visualized clearly in oblique cuts. Patients with postoperative radiculopathy with implants that could not be ascribed to any pathology visible in the conventional MR sequences might benefit from oblique MR imaging.

Keywords

Cervical Spine; Implant; Neural Foramen; Oblique; Surgery

DOI: 10.4328/JCAM.1157 Received: 15.06.2012 Accepted: 16.07.2012 Printed: 01.09.2015 J Clin Anal Med 2015;6(5): 709-712
Corresponding Author: Hakan Şimşek, Kasımpaşa Asker Hastanesi, Beyin Cerrahisi Kliniği, Beyoğlu, İstanbul, Türkiye.
F.: +90 2122387902 GSM: +905333884087 E-Mail: drhakansimsek@hotmail.com

Introduction

Degenerative cervical spinal disorders usually present with radiculopathy. Natural aging process outcrops imminent degenerative changes in the cervical spine (CS) consisting instability, disc herniation, and spinal stenosis [1]. The neural foramen of the CS has an almost elliptical shape and is oriented in an oblique position [2,3]. Conventional plain radiographs at an oblique view show the neural foramen of the CS, however they are of limited value in evaluating neural foraminal pathology. Therefore, techniques for visualizing cervical neural foramen have been developed.

Improved visualization of anatomic relations has been demonstrated for both Computerized Tomography (CT) and Magnetic Resonance (MR) imaging via oblique plane slices [4,5].

Additional acquisition of oblique MR images, thus, facilitates the identification of disease by providing a second orthogonal imaging plane in the relevant diseased area. Accurate evaluation of the structures within the hourglass-shaped neural foramen is of great importance in the operated levels of the CS as well. Postoperative persistent cervical radiculopathy usually requires MR imaging study. Especially for the cases in which implants (cage, plates and screws, etc.) are used, the artifacts deteriorate quality of images obtained in routine sequences. In this study, it has been aimed to depict the efficacy of 45° oblique MR images in selected patients for delineating foraminal pathology via sample cases particularly in the postoperative period.

Case Report

Between the years 2002 and 2007 we practiced 252 surgical interventions due to degenerative cervical spinal disorders. In their follow-up, some of the patients were evaluated by oblique MR images because of persistent radiculopathy. Using an axial scout image and arranging line cursors perpendicular to one neural foramen and parallel to the opposite foramen, we obtained oblique plane images. This allowed us to discern the nerve root 'en face' on the side studied, that was comparable to a 45° oblique plain radiograph. Because of the physiological lordosis of CS, all of the foramina may not always be visualized in one image, but usually two consecutive images will be sufficient to demonstrate all cervical foramina on each side [2]. Four cases are presented to notice efficacy of oblique MR imaging. First case emphasizes its importance also in decision of surgical treatment.

Case 1

A 37-year-old patient with neck and left upper extremity pain for two months was evaluated with cervical spinal MR images and although sagittal images readily showed C6-7 posterior disc protrusion, axial images did not confirm herniated disc within surgical limits (Figure 1a,b). Hence in addition to the traditional images, 45° oblique MR imaging sequence was performed to clarify the root in neural foramen. Oblique cuts revealed left-sided neural foraminal pathology far more prominent than previously evaluated traditional cuts (Figure 1c).

Case 2

A 68-year-old woman was operated for C5-6/6-7 cervical disc

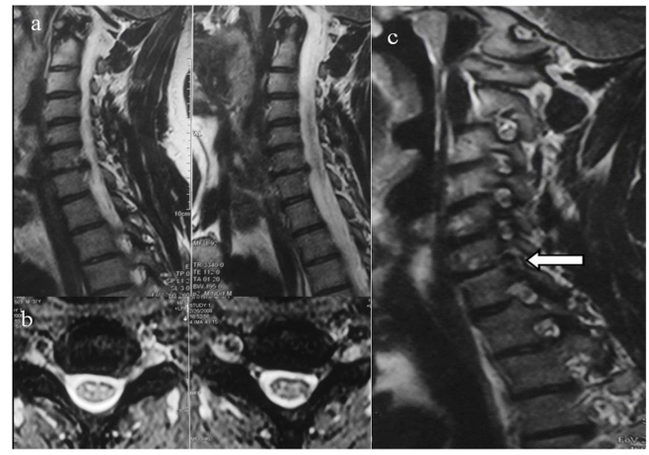

Figure 1. Sagittal cervical MR image of case 1 nearer to the left side suggests herniation of the C6-7 disc. However ventral subarachnoid space seems to be patent(A). Axial MR image of the same patient at the relevant level does not support disc disease(B). However, 45° oblique MR view reveals (arrow) foramina impingement at C6-7 level that explains the complaints of the patient(C).

disease. Anterior discectomy and fusion with polyetheretherketone (PEEK) cages was performed. However, she had neck and left upper extremity pain that began one year after the operation and deteriorated since then. MR imaging study revealed loss of lordosis and sagittal view suggested dural indentation at C5-6 and C6-7 intervertebral disc levels (Figure 2a). 45° sagittal oblique images revealed neuroforaminal stenosis at C56 level on the left side and redo surgery was decided (Figure 2b). En face image on the right side did not reveal any foraminal pathology (Figure 2c).

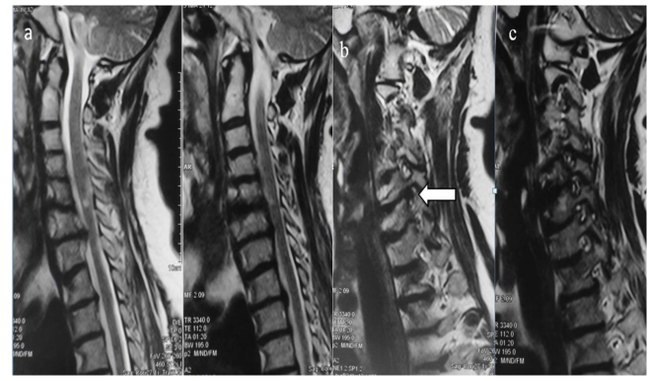

Figure 2. Sagittal MR image of case 2 with implants at C5-6 and C 6-7 levels suggests dural indentation at the operated levels and C6-7 level seems more problematic(A). However, 45° oblique MR view discerns (arrow) C5-6 foramina pathology rather than the consecutive level(B). 45° oblique MR view did not reveal any foramina pathology on the other right side(C).

Case 3

A 58-year-old man who had C6 corpectomy, C5-6/C6-7 discectomy and fusion with expandable cage implant admitted to our hospital. Cervical AP/L radiographs and MR images were obtained. Traditional sagittal and axial MR images were not informative about neural foraminal pathology because of the implant artifact, therefore 45° sagittal oblique sequence was added (Figures 3, 4a,b). Oblique cuts demonstrated neural foraminal structures 'en face' and despite the implant at the operated level, images were clear enough to say that there was not any foraminal pathology (Figure 5). After fortnight's medical treatment, patient's complaints resolved.



Figure 3. Patient with C6 corpectomy, C5-6/C6-7 discectomy and fusion with expandable cage implant.

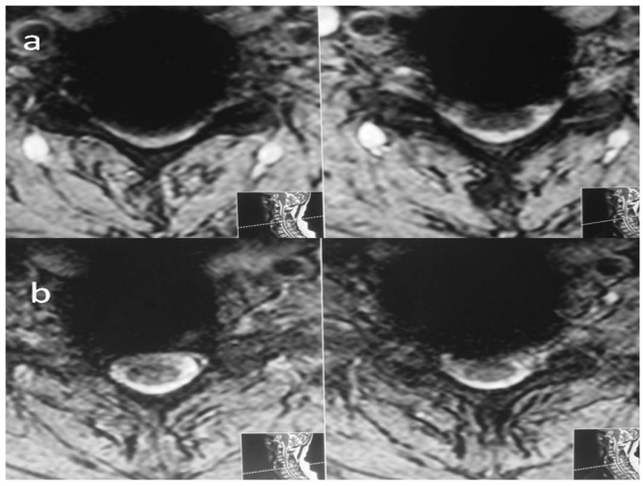

Figure 4. Traditional MR images of both levels were not informative about the operated levels because of the artifact of the implant (A,B).

Case 4

A 22-year-old man with C7 traumatic fracture was operated. C7 corpectomy, iliac autogenous bone grafting and C6 and Th 1 fusion with plate was performed. At his third month follow-up examination, neural structures in the relevant foramina were evaluated via 45°oblique MR images. Artifact because of the implant in the axial view was not present in the oblique sagittal view (Figures 6,7).

Discussion

The compression of the cervical nerve roots in the neural foramen is one of the most common reasons of cervical radiculopathy. Protruded discs and osteophytes are likely to cause nerve root compression anteriorly in the uncovertebral articulation

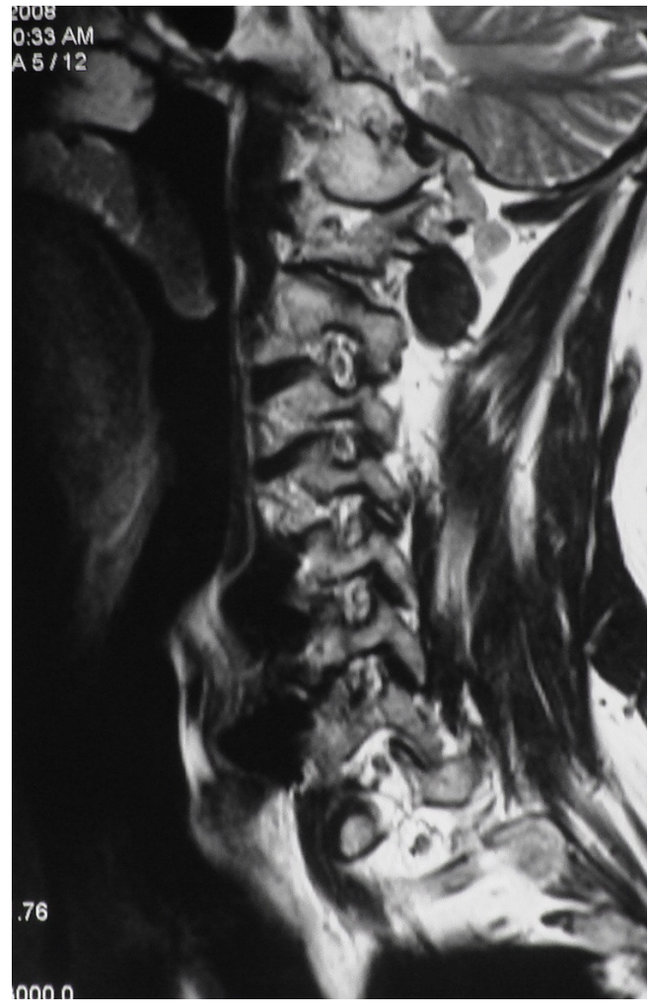

Figure 5. Additional 45° oblique MR sequence was added and oblique cuts demonstrated neural foramina structures 'en face' and despite the implant at the operated level, clear images were obtained. There was not any foramina pathology at the operated levels.



Figure 6. 45° oblique MR sequence discerns that intraforaminal neural structures are untroubled.

region. Superior articular process, the ligamentum flavum, and the fibrous tissue surrounding the radix usually outcrops nerve root compression posteriorly [6]. With MR images, each foramen is outlined by a dark line corresponding to the compact cortical bone of the inferior pedicle cortex superiorly, the superior pedicle cortex inferiorly, the posterior cortical bone of the vertebral bodies anteriorly, and the cortical bone of the posterior elements posteriorly [7]. The exact anatomic struc-

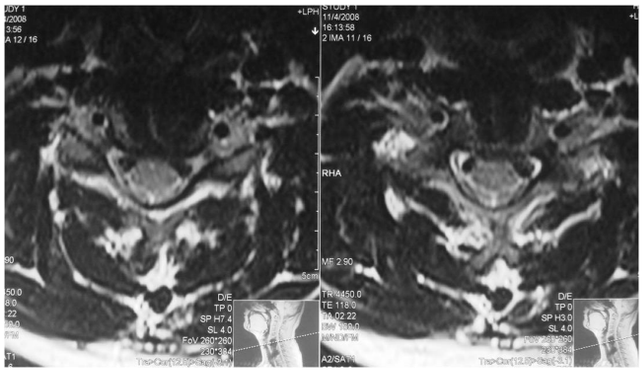

Figure 7. The artifacts caused by the implant deteriorate axial images of case 4. It is hard to assess roots and dural indentation.

tures that affect the nerve root may vary for each individual. However, some pathologies of the cervical root in the relevant foramina may stay quasi concealed because of the limited ability of traditional sagittal MR images in evaluating the neural foramen due to its oblique course. Reformatting standard axial CT images of the CS in an oblique plane produces excellent visualization of bony structures of the neural foramen, but to elucidate the pathology for each individual, MR imaging study is of great use and to the benefit of the patient. Appropriate use of oblique section can improve MR image quality and diagnostic value [8]. By a simple modification of an existing pulse sequence program, oblique images of CS can easily be obtained and spatial orientation can be established so as to asses pertaining foramen and root [9]. MR imaging is considered the gold standard for visualizing soft tissue, whereas CT is still applied for identifying bony abnormalities. Oblique MR has begun to be adopted into the conventional technique for the CS [10].

Oblique MR views can be employed when routine axial and sagittal images fail to clarify the situation [11]. Therefore, electronically activated oblique plane imaging was used to show the nerve roots 'en face' in their respective neural foramina [7]. Despite a successful surgical decompression, osteophytes have the propensity to regenerate in time. Persistent radicular pain in the early postoperative period instigates surgeon to expeditiously evaluate the patient by any attainable means. In such confounding circumstances, to verify sufficient decompression, postoperative anatomic condition of the neural foramen has to be evaluated. Custom MR images on axial and sagittal planes may not depict the pathology clearly because of the fibrous tissue in the region. Likewise, implant artifact impairs axial views. That compels the surgeon to contend with the difficulty of interpreting an unclear view and correlating it with the symptoms of patients. 45° sagittal oblique cuts through the neural foramen that displayed the nerve roots 'en face' within the relevant foramen were preferred. Perpendicular positioning of the images in the axial scouts provided images of the root remote from the foreign body. That gave less artifact and more accurate view of the afflicted structures as described in case 3.

45° oblique MR images more clearly demonstrate the pathology also by making the images less apt to be affected by artifacts, particularly in the patients with cervical implants. This could be ascribed to obtaining images in 45° oblique cuts on a plane some more distant from the instruments compared to the simple sagittal views. That might be namely an escape from deteriorating effect of the implants. Increased time that the patients have to spend in the scanner for the additional images is the only drawback of obtaining 45° oblique views; however, obvious advantage of the 45° sequences in delineating the pathology in the most confusing postoperative cervical spinal ailments makes it commendable.

To conclude, patients with postoperative radiculopathy with implants that could not be ascribed to any pathology visible in the conventional MR sequences might benefit from oblique MR imaging. Despite the artifact of implants in conventional axial MR images, additional 45° oblique MR sequence discerns more accurate root and foramen relation in the cervical spine.

Competing interests

The authors declare that they have no competing interests.

References

1. Holt S, Yates PO. Cervical spondylosis and nerve root lesions: incidence and routine necropsy. J Bone Joint Surg Br 1966;(48): 417-23.
2. Shim JH, Park CK, Lee JH, Choi JW, Lee DC, Kim DH, et al. A Comparison of angled sagittal MRI and conventional MRI in the diagnosis of herniated disc and stenosis in the cervical foramen. Eur Spine J 2009;(18):1109-16.
3. Tomoaki KAF. Morphologic changes in the cervical neural foramen due to flexion and extension. Spine 2004;29(24):2821-5.
4. Goodman BS, Geffen JF, Mallempati S, Noble BR. MRI images at a 45-degree angle through the cervical neural foramina: a technique for improved visualization. Pain Physician 2006;(9):327-32.
5. Yenerich DO, HV. Oblique plane MR imaging of the cervical spine. J Comput Assist Tomogr 1986;(10): 823-6.
6. Tanaka N, Fujimoto Y, An HS, Ikuta Y, Yasuda M. The anatomic relation among the nerve roots, intervertebral foramina, and intervertebral discs of the cervical spine. Spine 2000;25(3):286-91.
7. Flannigan BD, Lufkin RB, McGlade C, Winter J, Batzdorf U, Wilson G, et al. MR Imaging of the Cervical Spine: Neurovascular Anatomy. AJR 1987;(148):785-90.
8. Edelman RR, Stark DD, Saini S, Ferrucci JT Jr, Dinsmore RE, Ladd W, et al. Oblique planes of section in MR imaging. Radiology 1986;(159):807-10.
9. Huber DJ, Mueller E, Heubes P. Oblique magnetic resonance imaging of normal structures. AJR 1985;(145):843-6.
10. Humphreys SC, Hodges SD, Patwardhan A, Eck JC, Covington LA, Sartori M. The natural history of cervical foramen in symptomatic and asymptomatic individuals aged 20-60 years as measured by magnetic resonance imaging: a descriptive approach. Spine 1998;23(20):2180-4.
11. ModicTM, Masaryk TJ, Ross JS, Mulopulos GP, Bundschuh CV, Bohlman H. Cervical radiculopathy: value of oblique MR imaging. Radiology 1987;(163):227-31.

How to cite this article:
Hakan Ş, Omer S, Ercan M, Serdar K. Oblique MR Imaging in Cervical Spine Surgery. J Clin Anal Med 2015;6(5): 660-3.