Idiopathic Sustained Epicardial Ventricular Tachycardia Originating from the Great Cardiac Vein

Büyük Kardiyak Venden Kaynaklanan İdiyopatik Sürekli Epikardiyal Ventriküler Taşikardi

İdiyopatik Sürekli Epikardiyal Ventriküler Taşikardi / Idiopathic Sustained Epicardial Ventricular Tachycardia

Barış Buğan[1], Turgay Çelik[2], Hasan Kutsi Kabul[2], Erkan Yıldırım[2], Atila İyisoy[2]
[1]Malatya Military Hospital, Cardiology Service, Malatya,
[2]Gulhane Military Medical Academy, Department of Cardiology, Ankara, Turkey

1. 5th Congress of Update in Cardiology and Cardiovascular Surgery, 24-28 September 2009, ANTALYA, Abstract No: PP-176. The Heart Surgery Forum. 2009, volume 12: supplement 1. p.100.
2. XV. Ulusal Kardiyoloji Kongresi, İstanbul, Ekim 2009. Abstract No: P-031. Türk Kardiyoloji Derneği Arşivi 2009; 37; suppl 5; p. 127.

Özet

Büyük kardiyak venden kaynaklanan ventriküler taşikardi, nadiren karşılaşılan bir antitedir. Koroner sinus etrafından kaynaklanan ventriküler taşikardinin, prevalansı, elektrokardiyogram özellikleri, esas odak noktası veya bu idiyopatik ventriküler taşikardinin radyofrekans kateter ablasyon ile tedavisinin etkinliği bilinmemektedir. Bu olgu sunumu, büyük kardiyak venden kaynaklanan idiyopatik ventriküler taşikardinin elektrofizyolojik özelliklerini vurgulamaktadır.

Anahtar Kelimeler

Ablasyon; Büyük Kardiyak Ven; İdiyopatik; Ventriküler Taşikardi

Abstract

Ventricular tachycardia arising from the great cardiac vein is a rarely encountered entity. Prevalence, characteristics of electrocardiogram, common sites of ventricular tachycardia origin around the coronary sinus, or efficacy of therapy with radiofrequency catheter ablation of this idiopathic ventricular tachycardia is unknown. This case report emphasizes the electrophysiological characteristics of idiopathic ventricular tachycardia arising from the great cardiac vein.

Keywords

Ablation; Great Cardiac Vein; Idiopathic; Ventricular Tachycardia

DOI: 10.4328/JCAM.1256 Received: 14.08.2012 Accepted: 26.08.2012 Printed: 01.11.2015 J Clin Anal Med 2015;6(6): 850-852
Corresponding Author: Barış Buğan, Malatya Military Hospital, Cardiology Service, Malatya, Turkey.
T.: +90 4223365434 F.: +90 4223362043 E-Mail: bbugan@hotmail.com

Introduction

Idiopathic ventricular tachycardia (VT) and premature ventricular contractions (PVC) mainly originate from the right ventricular outflow tract (RVOT). Idiopathic VT/PVCs originating from the great cardiac vein constitute only a small number of cases. There is little data regarding the prevalence, ECG characteristics, and common sites of tachycardia origin around the coronary sinus and especially its branches, and efficacy of radiofrequency (RF) catheter ablation of these cases. Herein we report a case of symptomatic, sustained idiopathic VT originating from the great cardiac vein in a otherwise healthy female.

Case Report

A 32-year-old female was first admitted to another hospital with palpitation, and syncope two months ago. Electrophysiological study (EPS) and radiofrequency ablation was performed from the left aortic valve cusp (AVC) due to epicardial ventricular tachycardia, but she was admitted to our hospital with the same symptoms. Her physical examination was unremarkable. 12-lead electrocardiogram (ECG) obtained during the clinical tachycardia revealed sustained VT with right bundle branch block (RBBB) QRS morphology and a rightward axis (Figure 1).



Figure 1. A 12-lead ECG showing the sustained ventricular tachycardia with QRS morfology of right bundle branch block accompanied with a right-ward axis.

Echocardiography revealed a normal examination with a global ejection fraction of 68% and no chamber enlargement or valve disease. Magnetic resonance imaging (MRI) showed normal cardiac structures. EPS was performed. During mapping of the coronary sinus in EPS, pace mapping and the earliest ventricular activation site revealed that the origin of the tachycardia was the great cardiac vein. The intracardiac electrocardiographic recordings showed that the ventricular activation was 21 ms before QRS onset (Figure 2). Several RF energy applications (50 ºC, 50 W) were delivered at the site where earliest ventricular activation was recorded. After the procedure, tachycardia completely disappeared and spontaneous or clinical VT/PVCs were not induced by isoproterenol at the end of 20 minutes of monitoring. The electrocardiograms obtained two days after the procedure were normal. Patient was discharged from the hospital without any medication. The patient has remained completely asymptomatic 12 months after the procedure.

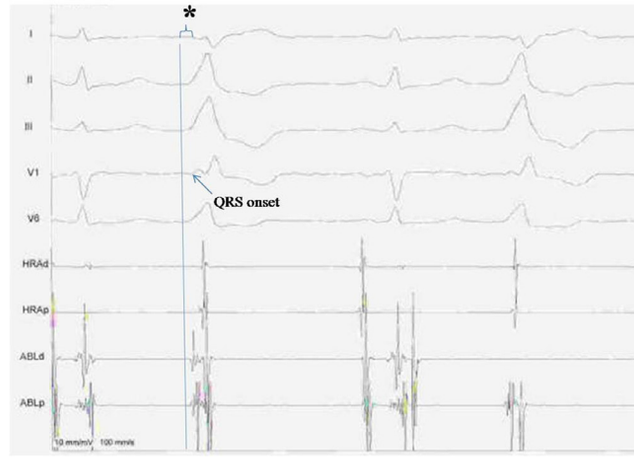

Figure 2. Intracardiac recordings. During the tachycardia, ventricular potential recorded by the distal ablation catheter (ABLd) preceded onset of the QRS complex by 21 ms (*).

Discussion

Idiopathic VT/PVCs may be classified by using several criteria including mechanism, location, and response to pharmacologic agents. Main classification groups are as follows: outflow tract VT, idiopathic left VT, and automatic VT. Outflow tract region describes the RV region between the pulmonary and tricuspid valves, the basal left ventricle including the outflow tract under the aortic valve, the aortic cusps, and the basal left ventricular (LV) epicardium. Most idiopathic VT/PVCs arise from RVOT [1].

ECG is an important guide to rapidly locate the origin of the tachycardia and plan the optimal catheter ablation before the patient is brought to the electrophysiology laboratory [1;2]. Ratio of the idiopathic outflow tract VT/PVCs originating from the epicardium are 9–13% [1-3]. The ECG characteristics of these tachycardia cases are described as follows: significantly greater R wave amplitude in the inferior leads, an S wave in lead I as part of an rS or QS pattern, and greater Q wave amplitude in aVL compared with aVR (ratio >1.4) [1-3]. In this case, ECG characteristics have shown almost the same criteria. In addition, a Q wave in lead I more commonly identify VT from an epicardial origin compared with an endocardial site [1]. Daniels et al [3] reported that a delayed precordial maximum deflection index ≥0.55 confidently localized VT to the epicardium with a sensitivity of 100% and a specificity of 98%.

Medical therapy and ablation are the options for management of these arrhythmias. Frequency and severity of symptoms play a critical role in determining the treatment strategy. Ablative therapy of epicardial VT/PVCs includes percutaneous and transthoracic epicardial approaches [1;3]. Ablation via percutaneous approach is performed from the AVC or coronary venous system and is feasible and often effective in selected patients. The majority of the patients can be successfully treated by this procedure. The transthoracic epicardial approach is recommended in cases in which standard ablation approaches have failed [3]. We performed ablation via the great cardiac vein because the previous ablation attempt via AVC in another hospital had failed. Meininger et al. [4] and Kaseno et al [5] reported successful ablation in patients with drug-refractory nonsustained VTs and PVCs originating from the great cardiac vein, as in our case.

Complications during ablation using CS and its branches consist of venous stenosis, vein rupture, venous thrombosis, and damage to adjacent coronary arteries with resultant stenosis [4;5]. Careful monitoring of catheter position may provide protection from all these complications.

Although idiopathic VT and PVCs mainly originate from the RVOT, uncommon sites of origin are seldom encountered. If the idiopathic VT/PVCs are not localized in the most common origin, epicardial foci including coronary sinus and its branches should be sought by pace-mapping. Careful analysis of the ECG before the procedure will facilitate the electrophysiological study in these patients.

Competing interests

The authors declare that they have no competing interests.

References

1. Latif S, Dixit S, Callans DJ. Ventricular arrhythmias in normal hearts. Cardiol Clin 2008 Aug;26(3):367-80.
2. Tada H, Nogami A, Naito S, Fukazawa H, Horie Y, Kubota S, et al. Left ventricular epicardial outflow tract tachycardia: a new distinct subgroup of outflow tract tachycardia. Jpn Circ J 2001;65(8):723-30.
3. Daniels DV, Lu YY, Morton JB, Santucci PA, Akar JG, Green A, et al. Idiopathic epicardial left ventricular tachycardia originating remote from the sinus of Valsalva: electrophysiological characteristics, catheter ablation, and identification from the 12-lead electrocardiogram. Circulation 2006;113(13):1659–66.
4. Meininger GR, Berger RD. Idiopathic ventricular tachycardia originating in the great cardiac vein. Heart Rhythm 2006;3(4):464-6.
5. Kaseno K, Tada H, Tanaka S, Goto K, Yokokawa M, Hiramatsu S, et al. Successful catheter ablation of left ventricular epicardial tachycardia originating from the great cardiac vein: a case report and review of the literature. Circ J 2007;71(12):1983-8.

How to cite this article:
Buğan B, Çelik T, Kabul HK, Yıldırım E, İyisoy A. Idiopathic Sustained Epicardial Ventricular Tachycardia Originating from the Great Cardiac Vein. J Clin Anal Med 2015;6(6): 790-2.