Orjinal Görüntü
JCAM
Original Image

Saccular Splenic Artery Aneurysm

Sakküler Splenik Arter Anevrizması

Saccular Splenic Artery Aneurysm / Sakküler Splenik Arter Anevrizması

Tolga Demir[1], Hale Bolgi Demir[2], Nuşen Tanrıkulu[3]
[1]Beylikduzu Kolan Hospital, Department of Cardiovascular Surgery, [2]Medicana International Hospital, Department of Cardiovascular Surgery,
[3]Kolan International Hospital, Department of Anesthesiology, Istanbul, Turkey

Visceral artery aneurysms are relatively rare clinical entities, although their detection is rising due to an increased use of cross-sectional imaging. Splenic artery aneurysms (SAA) are the most common visceral aneurysms, accounting for approximately 46 to 60% of cases. Processes directly related to the occurrence of SAAs include: atherosclerosis (the most common), congenital anomalies, Behcet's disease, and polyarteritis nodosa; facilitating processes include: pregnancy, portal hypertension, fibromuscular dysplasia, traumatic injuries, pancreatitis, septic emboli resulting from mycotic aneurysms, and inherited diseases, such as Marfan syndrome. Rupture is the most devastating complication, and is associated with a high risk of morbidity and mortality. In general, splenic artery aneurysms measuring 2 cm or larger, those found in women of childbearing age and in persons undergoing liver transplantation should be treated. 1,2,3

The development of interventional endovascular radiology has provided new therapeutic options for the management of aneurysms, by excluding the sac from the arterial circulation with coil embolisation or with a covered stent. The success rate of these treatments is between 75 and 100% with significantly less morbidity and mortality than with surgical techniques. 4

We present the case of a 42-year-old female who had an asymptomatic SAA detected incidentally by an abdominal ultrasound investigating an abdominal pain. A contrast enhanced computed tomography angiogram revealed a large saccular SAA measuring 3.2 cm × 2.1 cm located in the proximal portion of the splenic artery (Fig 1 and Fig 2). We have planed endovascular exclusion of the aneurysm by transcatheter coil embolization. But the patient refused treatment and preferred conservative approach.



Figure 1. Three-dimensional reconstruction of contrast enhanced spiral CT angiography: presence of splenic artery saccular aneurysm located in the proximal portion of the splenic artery.

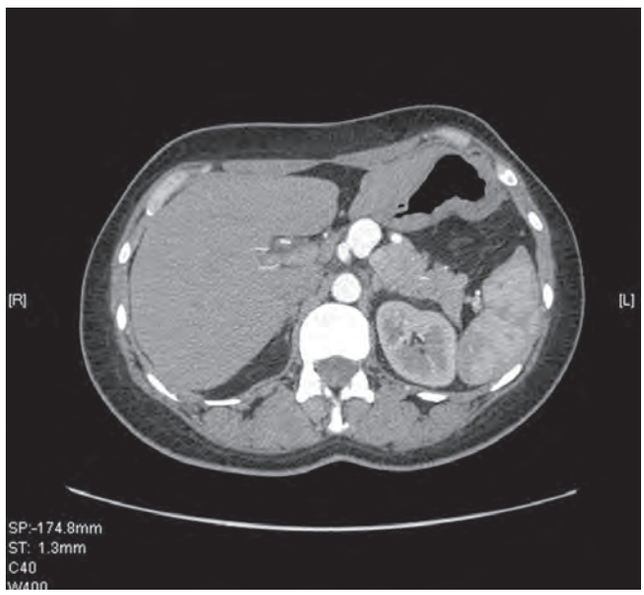

Figure 2. Contrast-enhanced CT scan reveals a large aneurysm of the splenic artery with dimensions of 3.2 × 2.1 cm.

References

1. Sachdev-Ost U. Visceral artery aneurysms: review of current management options. Mt Sinai J Med 2010;77(3):296-303.
2. Guillaumon AT, Chaim EA. Splenic artery aneurysm associated with anatomic variations in origin. J Vasc Bras 2009;8(2):177-81.
3. Ozbudak E, Arikan AA, Yavuz S, Kanko M, Berki T. A case of Behçet's disease with multiple recurrent visceral artery aneurysms. Turk Gogus Kalp Dama 2014;22(1);180-1.
4. Maillard M, Novellas S, Baudin G, Benzaken T, Karimdjee B, Anty R, et al. Splenic artery aneurysm: diagnosis and endovascular therapy. J Radiol 2010;91(11):1103-11.

DOI: 10.4328/JCAM.2905 Received: 08.10.2014 Accepted: 27.10.2014 Printed: 01.02.2015
Corresponding Author: Tolga Demir, Karayollari Mah, Abdi Ipekci Cad, Avrupa Konutlari TEM, A29, D: 57 34390, Gaziosmanpasa, Istanbul, Türkiye.
GSM: +905327491319 E-Mail: dr.tolgademir@gmail.com