# Pulmonary Atresia and Ventricular Septal Defect in a Thirty-Six Year Old Woman

# Otuz Altı Yaşında Bir Kadın Hastada Pulmoner Atrezi ve Ventriküler Septal Defekt Birlikteliği

Pulmoner Atrezi ve Ventriküler Septal Defekt Birlikteliği / Pulmonary Atresia and Ventricular Septal Defect

İbrahim Koç[1], Ayşen Dökme[1], Nesimi Yavuz[2], Gökhan Bulut[3]
[1]Pulmonary Medicine, Viranşehir State Hospital, [2]Cardiology, Viranşehir State Hospital, [3]Radiology, Viranşehir State Hospital, Şanlıurfa, Turkey

**Özet**

Pulmoner atrezi ve ventriküler septal defekt (PA-VSD) konjenital kalp hastalığının nadir görülen bir formudur. Pulmoner arterlere kan akışı patent duktus arterious veya major aorto-pulmoner kollateral arterler (MAPCAs)'le sağlanır. Burada eforla artan nefes darlığı ve senkop nedeniyle kliniğimize refere edilen otuz altı yaşında Suriyeli savaş mağduru bir kadın hasta sunulmaktadır. Sorgulandığında çocukluğundan beri bu şikayetlerinin varlığını, kardiyak kateterizasyon ve ameliyat gerektiren bir hastalığının olduğunu ancak bu işlemleri kabul etmediğini belirtti. Ekokardiyografi ve bilgisayarlı tomografi anjiografide pulmoner atrezi ve ventriküler septal defet saptandı. Pulmoner arterlere kan akışının aortopulmoner kollateral arterlerce sağlandığı gözlendi. Pulmoner atrezili hastaların çoğunluğu ameliyat olmadan otuz yaşını geçememektedir. Burada sunulan olgu cerrahi işlem olmadan otuz yıldan fazla yaşayan nadir olgulardan biridir.

**Anahtar Kelimeler**

Pulmoner Atrezi; Ventriküler Septal Defekt; Senkop; Dispne

**Abstract**

Pulmonary atresia with ventricular septal defect (PA-VSD) is a rare form of congenital heart disease. The blood supply to the pulmonary arteries is provided by a patent arterial duct or by major aorto-pulmonary collateral arteries (MAPCAs). Here we present a thirty six years old Syrian war victim who was referred to our clinic with complaints of dyspnea on exertion and syncope. When questioned she admitted that she was having these complaints since her childhood and had a disease that she was offered cardiac catheterization and operation which she refused. Echocardiographic and computed tomography angiography findings revelaed pulmonary atresia with ventricular septal defect and aortopulmonary collateral arteries provided the blood flow to pulmonary arteries. Most patients without surgery do not live more than three decades. The presented case is one of those surviving more than three decades without surgery.

**Keywords**

Pulmonary Atresia; Ventricular Septal Defect; Syncope; Dyspnea

DOI: 10.4328/JCAM.3551 Received: 28.04.2015 Accepted: 23.05.2015 Printed: 01.10.2015 J Clin Anal Med 2015;6(suppl 5): 617-9
Corresponding Author: İbrahim Koç, Pulmonary Medicine, Viranşehir State Hospital, Şanlıurfa, Turkey.
GSM: +905453142502 E-Mail: İbrahimkoc1981@gmail.com

## Introduction

Pulmonary atresia with ventricular septal defect (PA-VSD) is a rare form of congenital heart disease. The blood supply to the pulmonary arteries is provided by a patent arterial duct or by major aortopulmonary collateral arteries (MAPCAs), which can vary greatly in number and in site of origin [1, 2]. Most of the cases with pulmonary atresia are associated with MAPCAs. It shares similarities with Tetralogy of Fallot (TOF) however, TOF involves pulmonary or infundibular stenosis but there is no pulmonary atresia. PA-VSD now is known as a distinct entity with its typical findings and management issues. The estimated survival rate without surgery is low [3]. PA with MAPCAs is a complex congenital cardiac anomaly and one of the most challenging groups to manage surgically. Echocardiography can be used to assess the presence and size of the central pulmonary arteries in patients with PA-VSD. Here we present a 36 years old woman Syrian war victim who had admitted to our clinic with dyspnea on exertion, low oxygen saturation and syncope and diagnosed with PA-VSD.

## Case Report

A thirty six-year-old woman was admitted to our clinic with complaints of syncope, dyspnea on exertion and at rest. On her physical examination she had blurred consciousness, respiratory rate of 20 breaths per minute and SpO2 of 70% on room air, the patient had cyanotic and cluubbed fingers (Picture 1).



Picture 1. Cyanotic and clubbed fingers of the patient.

The patient was hospitalized for the further evaluation. Even under high oxygen supply SpO2 did not exceed 85%. When questioned she admitted that she was having these complaints since her childhood and had a disease that she was offered cardiac catheterization and operation which she refused. Computed tomography angiography of the chest revealed pulmonary artery atresia and aortopulmonary collateral arteries (Figure 1).

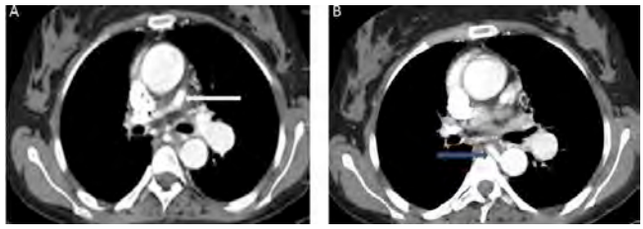


Figure 1. Computed tomography angiography of the chest revealed atresia of right and almost agenesis of left pulmonary artery and aortopulmonary collateral artery (arrows).

Echocardiography revealed a large VSD which lay beneath the dilated aorta (Figure 2). Later on her follow up she admitted that she had two pregnancies which resulted with abortion. In the light of her medical history, computed tomography angiography and echocardiography findings, she was diagnosed with pulmonary atresia and ventricular septal defect.

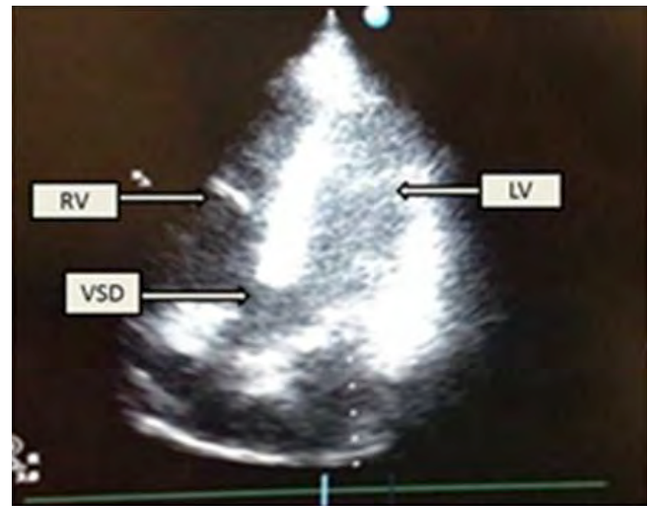


Figure 2. Echocardiography revealed a large VSD which lay beneath the dilated aorta, hypertrophied right ventricle.LV: Left ventricle, RV: Right ventricle, VSD: Ventricular septal defect.

## Discussion

Pulmonary atresia with VSD is the ultimate form of TOF and is estimated to represent 5% to 10% of patients with Fallot tetralogy. Adult survivors of PA-VSD are quite rare: it is reported that the mean life expectancy without operation is not more than 3 decades [4]. Prognosis and survival of PA-VSD patients is dependent on the sufficiency of pulmonary blood flow derived from direct or indirect aortopulmonary collateral vessels. The well developed MAPCAs probably have enabled our patient to survive until this age. Especially left pulmonary atresia is almost agenesia but collaterals have provided the blood flow ( Figure 1). Echocardiography and multidetecter computed tomography are valuable non-invasive imaging modalities to evaluate VSD, the development and sources of MAPCAs in PA-VSD. Our case was a thirty- six years old woman who has been suffering from dyspnea on exertion and sometimes syncope. The patient refused to be operated and had two pragnencies which resulted with abortion. Main procedures are catheterization or surgical intervention. The reported surgical mortality has been relatively low and good functional results have been achieved [5, 6]. In the early stages of the life palliation is done by aortopulmonary shunt. The ultimate goal of surgery is to construct completely separated pulmonary and systemic circulations. This can be achieved as a single or staged procedure, depending on the pulmonary blood supply and complexity of the central pulmonary arteries. The surgical technique employed to repair PA-VSD defect with MAPCAs dependent pulmonary blood supply is variable, and depends upon individual anatomy and surgeon preference. Anatomic variability seen in PA-VSD makes the surgical approach patient specific [7]. Our case was offered surgery but she refused the procedure.

In conclusion patients with pulmonary atresia and ventricular septal defect rarely survive more than three decades, thanks to major aortopulmonary collateral arteries some patients manage to survive as in our patient.

*Competing interests*

The authors declare that they have no competing interests.

**References**

1. Rajeshkannan R, Moorthy S, Sreekumar KP, Ramachandran PV, Kumar RK, Remadevi KS. Role of 64-MDCT in evaluation of pulmonary atresia with ventricular septal defect. AJR Am J Roentgenol 2009;194(1):110-8.
2. Amin Z, McElhinney DB, Reddy VM, Moore P, Hanley FL, Teitel DF. Coronary to pulmonary artery collaterals in patients with pulmonary atresia and ventricular septal defect. Ann Thorac Surg 2000;70(1):119-23.
3. Lee CH, Kwak JG, Lee C, Primary repair of symptomatic neonates with tetralogy of Fallot with or without pulmonary atresia. Korean J Pediatr 2014;57(1):19-25.
4. Babliak OD, Lalyns'ka TA, Kurkevych AK, Maksymenko AV, Rudenko NM, Lemets IM. Pulmonary atresia with ventricular septal defect and major aorto-pulmonary collateral arteries: diagnosis and treatment. Lik Sprava 2015; 5(6): 94-7.
5. Atik, E. Case 3/2014 - 26-year-old man with pulmonary atresia and ventricular septal defect in late postoperative evolution. Arq Bras Cardiol 2014;102(4):34.
6. Perri G, Albanese SB, Carotti A. Airway complications after single-stage unifocalization for pulmonary atresia, ventricular septal defect, and major aortopulmonary collateral arteries. J Card Surg 2015;30(5):453-8.
7. Fouilloux V, Bonello B, Kammache I, Fraisse A, Mace L, Kreitmann B. Management of patients with pulmonary atresia, ventricular septal defect, hypoplastic pulmonary arteries and major aorto-pulmonary collaterals: Focus on the strategy of rehabilitation of the native pulmonary arteries. Arch Cardiovasc Dis 2012; 105(12):666-75.

*How to cite this article:*
Koç İ, Dökme A, Yavuz N, Bulut G. Pulmonary Atresia and Ventricular Septal Defect in a Thirty-Six Year Old Woman. J Clin Anal Med 2015;6(suppl 5): 617-9.