Acute Respiratory Distress Syndrome and Pulmonary Hypertension Induced By Adenovirus Infection: A Child Case

Adeno Virüs Enfeksiyonuna Bağlı Gelişen ARDS ve Pulmoner Hipertansiyon : Bir Çocuk Olgusu

Adeno Virüs Enfeksiyonuna Bağlı Gelişen ARDS / ARDS Induced By Adenovirus Infection

Vildan Güngörer
Çocuk Yoğun Bakım Servisi, Samsun Kadındoğun ve Çocuk Hastalıkları Hastanesi, Samsun, Türkiye

Özet

Adenovirus, çocuklarda akut solunumsal hastalıklarda major patojenlerden biri olup çift sarmallı DNA virüsüdür Adeno virüs asemptomatikten ölümle sonuçlanan ciddi enfeksiyona kadar çok değişik klinik şekillerde karşımıza çıkmaktadır. Bizim olgumuzda prematüre doğmuş olup uzun süre yenidoğan yoğunbakımda yatmış olan 6ay 18 günlük bilinen immünyetmezliği olmayan bir hastada adenovirüse bağlı ARDS ve pulmoner hipertansiyon sunuldu.

Anahtar Kelimeler

Adenovirüs; Akut Solunum Yetmezliği; Pnömoni

Abstract

Adenovirus is a double-stranded DNA virus and one of the major pathogens in acute respiratory diseases in children. Adenovirus may present in many different clinical forms from asymptomatic to fatal serious infections. The present study reported a case of adenovirus-associated ARDS and pulmonary hypertension in a 6-month and 18-day old non-immunodeficient patient who was born premature and hospitalized for a long time in the neonatal intensive care.

Keywords

Adenovirus; Acute Respiratory Distress Syndrome; Pneumonia

DOI: 10.4328/JCAM.3605 Received: 15.05.2015 Accepted: 13.06.2015 Printed: 01.10.2015 J Clin Anal Med 2015;6(suppl 5): 632-4
Corresponding Author: Vildan Güngörer, Çocuk Yoğun Bakım Servisi, Samsun Kadındoğum ve Çocuk Hastalıkları Hastanesi, 55100, Samsun, Türkiye.
GSM: +905069468791 E-Mail: vildan_61183@hotmail.com

Introduction

Adenovirus is a double-stranded DNA virus and one of the major pathogens in acute respiratory diseases in children [1]. Adenovirus may present in many different clinical forms from asymptomatic to fatal serious infections. Although rhinitis, conjunctivitis, pharyngitis, tracheitis, gastroenteritis or keratoconjunctivitis are clinically more common, it also leads to lower respiratory tract infections such as bronchiolitis, croup and pneumonia [1-5]. Adenovirus can be very serious and fatal for very young, very old and immunocompromised patients. Adenovirus-associated pneumonia can lead to a spectrum of problems ranging from a typical bronchopneumonia to fatal acute respiratory distress syndrome (ARDS) [2,6-10]. Serological tests, DNA detection by polymerase chain reaction (PCR) and detection of adenovirus-specific antigen are used for diagnostic purposes; however, adenovirus-specific therapy is limited [11-13].

Case Report

A 6-month and 18-day old baby girl born at 26 weeks weighing 840 grams who was intubated for 78 days and hospitalized for a total of 3 months in the neonatal intensive care unit with the diagnoses of prematurity, respiratory distress syndrome (RDS), retinopathy of prematurity (ROP), bronchopulmonary dysplasia (BPD) was admitted with respiratory distress and cyanosis. The patient's vitals were as follows: body temperature: 38.9°C, blood pressure: 65/30 mmHg, peak heart rate: 165/min, respiration rate: 62/min and So2: 65%. Physical examination indicated that she had tachypnea, subcostal and intercostal retractions, dyspnea and peripheral cyanosis. When listened, lung sounds were coming from deep. Her body weight was 4600 grams (<3p). The results of laboratory analysis were as follows: Hb: 10.7 g/dl, WBC:23790/mm3, PLT:240000/ mm3, and neutrophils: 17030/ mm3. The results of biochemical analysis were as follows: AST: 238 and ALT: 141.The level of C-reactive protein (CRP) was normal. The blood gas values were as follows: pH: 7.28, pCO2: 36 and HCO3: 18. A posteroanterior chest X-ray showed paracardiac infiltrations.

The patient was admitted to the neonatal intensive care with a diagnosis of pneumonia. The monitored patient received normal saline infusion twice due to the low blood pressure. She was administered oxygen therapy using a high-flow oxygen delivery device (flow 15L/min, FiO2: 60%). A broad-spectrum antibiotherapy was initiated (vancomycin + meropenem). Tamiflu was prescribed due to the outbreak of H1N1. Echocardiography showed a secundum atrial septal defect (ASD) of 6.5 mm diameter, tricuspid regurgitation (TY) of 3.5m /sec velocity and pulmonary arterial (PA) pressure of 50mmHg. She was diagnosed with pulmonary hypertension and prescribed enalapril and lasix by pediatric cardiology. The patient's hypoxemia increased despite the high flow of oxygen. The patients with low saturations and respiratory acidosis (pH: 7.21, pCO2: 68) was intubated and put on a ventilator on P-SIMV (Pressure-Synchronized Intermittent Mandatory Ventilation) mode at the eighth hour of hospitalization (PIP: 25, PEEP: 5, rate: 30). Repeated posteroanterior chest X-ray showed a frosted glass pattern associated with ARDS (Figure 1). When the patient's hypoxemia did not improve, PEEP set on the ventilator was gradually increased

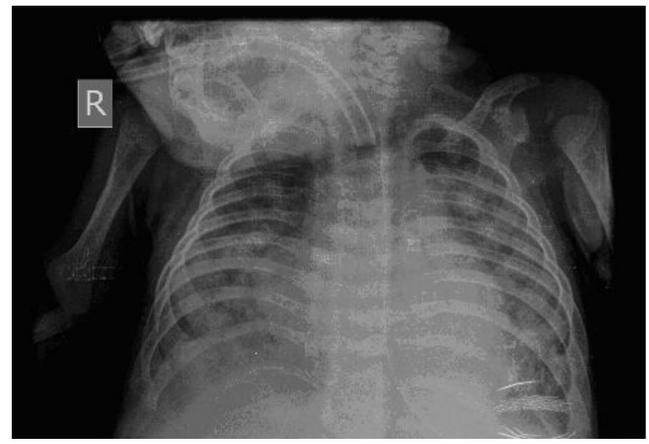

Figure 1. X-ray showed a frosted glass pattern

(PEEP: 7).The patient with a low blood pressure was supported with inotropic agents (adrenaline infusion 0.2mcg/kg/min). An abdominal ultrasonography was conducted on the patient with elevated results of liver function tests. The ultrasonography revealed minimal intraperitoneal fluid. A sputum sample was taken for the Respiratory Virus PCR Panel and a blood sample was also taken for CMV PCR. ARDS began to disappear on the third day of the follow-up. The ventilator settings were gradually reduced and inotropic support was stopped. The patient was extubated on the seventh day of hospitalization. After extubation, the results of respiratory virus panel (RVP) test were PCR positive for adenovirus and PCR negative for cytomegalovirus (CMV). Echocardiography was repeated for control purposes. Pulmonary hypertension disappeared. Minimal pericardial effusion was detected. It was suggested to stop enalapril and lasix. When the liver function tests and chest x-ray of the patent with good oral intake returned to normal, she was discharged on the thirteenth day of hospitalization.

Discussion

Adenovirus infections are quite common in children aged between 6 months and 5 years [1]. The most important cause of hospitalization, morbidity and mortality is viral pneumonia especially in premature babies and in the first 6 months of life. Adenovirus is the underlying pathogen in 10% of respiratory diseases in children. Adenovirus infections often present as rhinitis pharyngitis, tracheitis, gastroenteritis or keratoconjunctivitis while the asymptomatic infection rate approaches nearly 50% [2]. Although it is rare, adenovirus leads to severe clinical manifestations such as ARDS, pulmonary hypertension or disseminated infection especially in newborns, premature infants and immunocompromised persons.

The present study reported a case of adenovirus-associated ARDS and pulmonary hypertension in a 6-month and 18-day old non-immunodeficient patient who was born premature and hospitalized for a long time in the neonatal intensive care. In our case, adenovirus was detected by polymerase chain reaction (PCR) method using sputum samples, and other respiratory viruses (human coronavirus 229E, human bocavirus, human coronavirus OC43, parainfluenza 1/2/3, respiratory syncytial virus A/B, rhinovirus, enterovirus, parechovirus, H1N1, influenza A, influenza B, Human metapneumovirus, parainfluenza 4, human coronavirus HKU1, and human coronavirus NL63) were

excluded using the same method.

In a study involving 80 adenovirus-infected patients, Chen et al. reported that 17 patients were hospitalized in ICU and only one case who was a 1.7-year-old boy with cerebral palsy had ARDS and resulted in death [14]. In another study, only 9 of 617 adenovirus-infected children had serious infection and only one died [15]. Our patient had a history of premature birth and no underlying disease. In the literature, there are disseminated cases of ARDS and fatal cases of adenovirus infection especially in immunocompromised patients and newborns [16-17]. However, it is a rare case that adenovirus-associated ARDS and pulmonary hypertension developed in a patient who had no known disease but a history of premature birth 6 months.

Previous studies have reported fever, cough and rhinorrhea that are typical symptoms of adenovirus-associated pneumonia as well as tachypnea and dyspnea in nearly half of patients [18-21]. In our case, the most obvious symptom was tachypnea and dyspnea. There was also a high fever and a high level of leukocytes. In the study of Chen et al., one quarter of the patients had high levels of leukocyte in a similar way to bacterial infection while half of the patients had high levels of CRP and a high fever [14]. However, in our case, the level of CRP was not markedly high. Although the chest X-ray revealed no obvious infiltration, our patient was prescribed a broad-spectrum antibiotic as the high level of leukocyte and high fever initially suggested bacterial pneumonia. In several studies in the literature, clinicians have difficulty in distinguishing between bacterial infection and adenoviral infection due to similarities in symptoms [14-19]. We believe that the reason for prescribing antibiotics in many hospitalized patients is the clinical confusion of diagnosis. Our patients had also symptoms of acid in the abdomen and minimal pericardial effusion. Previous studies have not reported such symptoms in adenovirus infections.

To conclude, although adenovirus infections rarely show a serious clinical course in healthy children, it should be remembered that it is an infection that can even result in death, and health care providers should be particularly vigilant in adenovirus-associated pneumonia. Adenovirus-associated pneumonia should be considered especially in patients who do not respond to antibiotics as it clinically mimics bacterial pneumonia.

Competing interests

The authors declare that they have no competing interests.

References

1. Cherry JD. Adenoviruses. In: Feigin RD, Cherry JD, Demmler GJ, Kaplan SI, editors. Textbook of pediatric infectious diseases. 6th ed. Philadelphia: WB Saunders; 2009.p.1843–62.
2. Horwitz M. Adenoviruses. In: Fields B, Knipe D,Howley P, Chanok R, Melnick J, Monath T, Roizman B, Straus S, editors. Virology. 3rd ed. Philadelphia: Lippincott-Raven Publishers; 1996.p.2149-63.
3. Pancini DL, Collier AM, Henderson FW. Adenovirus infections and respiratory illness in children in group day care. J Infect Dis 1987;156(6):920–7.
4. Edwards KM, Thompson J, Paolini J, Wright PF. Adenovirus infections in young children. Pediatrics 1985;76(3):420–4.
5. Dominguez O, Rojo P, de Las HS, Folgueira D, Contreras JR. Clinical presentation and characteristics of pharyngeal adenovirus infections. Pediatr Infect Dis J 2005;24(8):733–4.
6. Louie JK, Kajon AE, Holodniy M, Guardia-LaBar L, Lee B, Petru AM, et al. Severe pneumonia due to adenovirus serotype 14: a new respiratory threat? Clin Infect Dis 2008;46(3):421–5.
7. Chuang YY, Chiu CH, Wong KS, Huang JG, Huang YC, Chang LY, et al. Severe adenovirus infection in children. J Microbiol Immunol Infect 2003;36(1):37–40.
8. Carballal G, Videla C, Misirlian A, Requeijo PV, Aguilar Mdel C. Adenovirus type 7 associated with severe and fatal acute lower respiratory infections in Argentine children. BMC Pediatr 2002;2(1):6.
9. Lang WR, Howden CW, Laws J, Burton JF. Bronchopneumonia with serious sequelae in children with evidence of adenovirus type 21 infection. Br Med J 1969;1(5636):73–9.
10. Kuo CY, Lee CY, Kao CL, Hsu YH. A fatal case of viral pneumonia in a child infected with adenovirus type 3. Acta Paed Sin 1990;31(1):40–5.
11. Birenbaum E, Linder N, Varsanon A, Azar R, Kuint J, Spierer A, et al. Adenovirus type 8 conjunctivitis outbreak in a neonatal intensive care unit. Arch Dis Child 1993;68(5 Spec No):610–1.
12. Uhnoo I, Wadell G, Svensson L, Johansson ME. Importance of enteric adenoviruses 40 and 41 in acute gastroenteritis in infants and young children. J Clin Microbiol 1984;20(3):365–72.
13. Van R, Wun CC, O'Ryan ML, Matson DO, Jackson L, Pickering LK. Outbreaks of human enteric adenovirus types 40 and 41 in Houston day care centers. J Pediatr 1992;120(4):516–21.
14. Chen SP, Huang YC, Chiu CH, Wong KS, Huang YL, Huang CG et al. Clinical features of radiologically confirmed pneumonia due to adenovirus in children. Journal of Clinical Virology 2013;56(1):7-12.
15. Chuang YY, Chiu CH, Wong KS, Huang JG, Huang YC, Chang LY, et al. Severe adenovirus infection in children. J Microbiol Immunol Infect 2003;36(1):37–40.
16. Sürmeli-Onay Ö, Karhan A, Güçer Ş, Karagöz T, Yurdakök M. Postmortem tanı alan fatal adenoviral pnömoni: Bir yenidoğan olgusu. Çocuk Sağligi ve Hastaliklari Dergisi 2012;55(2).
17. Pinto A, Beck R, Jadavji T. Fatal neonatal pneumonia caused by adenovirus type 35: report of one case and review of the literature. Arch Pathol Lab Med 1992;116(1):95-9.
18. Hong JY, Lee HJ, Piedra PA, Choi EH, Park KH, Kho YY, et al. Lower respiratory tract infections due to adenovirus in hospitalized Korean children: epidemiology, clinical features, and prognosis. Clin Infect Dis 2001;32(10):1423–9.
19. Lin CH, Huang YC, Chiu CH, Huang CG, Tsao KC, Lin TY. A cluster of adenovirus serotype 3 infections in children in northern Taiwan: clinical features and laboratory findings. J Microbiol Immunol Infect 2007;40(4):302–9.
20. Assaad F, Borecka I. Nine-year study of WHO virus reports on fatal viral infections. Bull World Health Organ 1977;55(4):445–53.
21. Teper AM, Kofman CD, Maffey AF, Vidaurreta SM. Lung function in infants with chronic pulmonary disease after severe adenoviral illness. J Pediar 1999;134(6):730–3.

How to cite this article:
Güngörer V. Acute Respiratory Distress Syndrome and Pulmonary Hypertension Induced By Adenovirus Infection: A Child Case. J Clin Anal Med 2015;6(suppl 5): 632-4.