Breast Cancer with Silent Metastasis to Uterine Cervix

Uterin Servikse Sessiz Metastaz Yapmış Meme Kanseri Olgusu

Meme Kanseri'nin Serviks Uteri Metastazı / Cervical Metastasis of Breast Cancer

Gokhan Pekindil[1], Pinar Solmaz Hasdemir[2], Ayca Tan[3], Gamze Goksel[4]
[1]Department of Radiology, [2]Department of Obstetrics and Gynecology,
[3]Department of Pathology, [4]Department of Medical Oncology,
Celal Bayar University School of Medicine, Manisa, Turkey

Özet

Kadın genital organlarına ekstragenital kanserlerin metastaz yapmasına nadiren rastlanır. Uterin serviks, kadın genital sisteminde en nadir olarak dış organ metastazı alan bölgedir. Bu yazıda, overler ve uterin servikse sessiz metastaz yapmış bir opere meme kanseri olgusu sunulmuştur. Öyküsünde meme kanseri olan olgularda jinekolojik organların metastaz yönünden dikkatlice değerlendirilmesi, özellikle vajinal kanama veya şüpheli ultrasonografik bulguları olan olgularda olmak üzere önem taşımaktadır. Uterin serviks de potansiyel bir metastatik saha olarak mutlaka değerlendirme kapsamına alınmalıdır.

Anahtar Kelimeler

Meme Kanseri; Metastaz; Serviks; Ovaryan Metastaz

Abstract

Metastases to female genital organs from extragenital cancers are uncommon. Uterine cervix is one of the less uncommon site of the genital tract for extragenital organ tumors. We present a case of operated breast cancer who had silent metastases to the ovaries and uterine cervix. Metastatic involvement of the gynecologic organs should be considered in women with a history of breast cancer who present with vaginal bleeding or suspicious changes on transvaginal ultrasound. Uterine cervix should always kept in mind as a part of metastasis.

Keywords

Breast Cancer; Cervix; Metastasis; Ovarian Metastasis

DOI: 10.4328/JCAM.3748 Received: 08.07.2015 Accepted: 31.07.2015 Printed: 01.10.2015 J Clin Anal Med 2015;6(suppl 5): 647-9
Corresponding Author: Pinar Solmaz Hasdemir, Department of Obstetrics & Gynecology, Celal Bayar University School of Medicine, 45000, Manisa, Turkey.
T.: +90 4444228 F.: +90 2362338040 E-Mail: solmazyildiz@yahoo.com

Introduction

Metastasis of distant malignancies to the cervix uteri is a rare occurrence with a frequency of 0,3 % for all tumors [1,2]. However, the frequency of cervical metastasis of breast cancer is much lower and there are only 35 breast cancer with cervical metastasis cases reported in literature [3]. Because of the situation was rather uncommon, it might be difficult to diagnose for the clinician.

Case Report

A 40 years old woman with a history of breast cancer was referred to the gynecology out-patient clinic for routine control. She had a history of left sided total mastectomy and axilllary lymph node dissection operation because of a malign mass in her left breast and 6 courses of TAC (Docetaxel, Adriamycin, Cyclophosphamide) chemotherapy and 25 days of radiotherapy (a total dose of 5000 cGy) after the operation. She was at the 20th months of the adjuvant chemotherapy. Hormonotherapy with Goserelin and Tamoxifen was planned because of the positive (90%) estrogen and progesterone hormone receptors in the pathologic examination of the tumoral tissue. The physical examination and findings at imaging of the genital organs were completely normal (Figure 1). Total hysterectomy with



Figure 1. No finding is seen in servix (arrowed) on sagitally reformatted pelvic MDCT.

bilateral adnexectomy was planned because of the patient's anxiety about the breast tumor and willingness for the operation. The appearance of the intraabdominal organs including the uterus and the adnexes were normal. The pathologic investigation revealed that metastasis of invazive lobular breast cancer in bilateral ovaries and the uterine cervix. The microscopic tumor areas was found in the exocervical area and in the lymphatic vessels. On macroscopic examination there was not any mass in the uterine cervix, uterus and bilateral ovaries. Endometrium and myometrium had no significant pathological findings. However, beneath the normal squamous epithelium of the cervix and in more deeper stromal areas there were multiple foci of non-cohesive cells having hyperchromatic nuclei and scanty cytoplasm, some with signet ring-cell appearance. These cells formed no organoid pattern (Figure 2). In some areas the tumor cells were seen in lymphatics forming thrombi. On sections from both ovaries, similar cells were found to diffusely infiltrated ovarian stroma (Figure 3). Immunohistochemical (IHC) analysis revealed reactivity for cytokeratin, estrogen

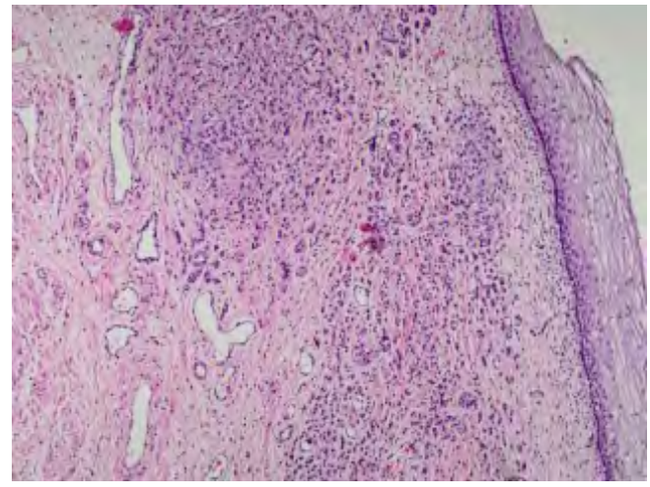

Figure 2. Foci of tumor comprising with non-cohesive cells just beneath the squamous epithelium of the uterine cervix (H&EX100).

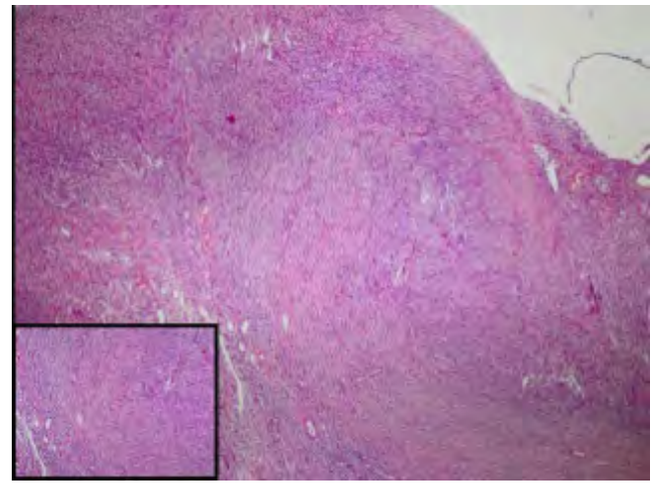

Figure 3. Diffusely infiltrating tumor cells of in the ovary (H&EX40), inset (H&EX100).

receptor (ER), progesterone receptor (PR), mammoglobulin and gross cystic disease fluid protein-15 (GCDFP-15), whereas the cells were negative for E-cadherin (Figure 4-5). All these findings were consistent with the patient's history having lobular carcinoma in her breast . The result of the pathologic investigation was consulted with medical oncology department and additional chemotherapy with Gemcitabine and Kapesitabin (1-8/ 28 days) was decided to start. The patient is under the 4th course of chemotherapy with normal imaging on computerized tomographic examination.

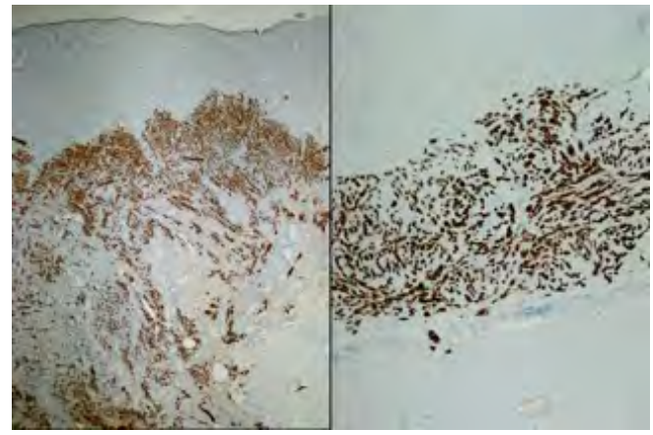

Figure 4. Positivity of tumor cells with cytokeratin, left side-ovary (X40) and right side-uterine cervix (X100).

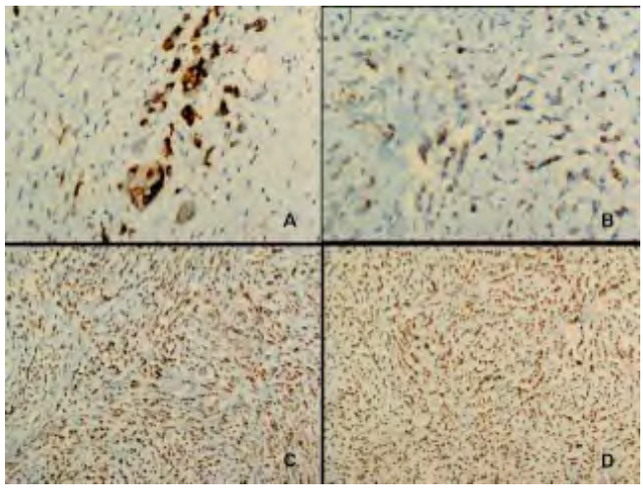

Figure 5. Tumor cells infiltrating uterine cervix showing positivity with A) mammoglobulin (X400) B) GCDFP-15 (X400) C) PR (X200) D) ER (X200).

Discussion

Uterine cervix is a curious area for extragenital tumor metastases. Mazur et al collected a series of 149 cases metastases to the female genital tract from extragenital cancers and only 3,4% (5/149) cases were found to be metastasized to uterine cervix [4]. The most common sites of the primary tumor were the breast and the stomach in cervical metastasis from the extragenital organ cases [5].

Although genital organs are not common sites for the metastatic spread of the extragenital tumours, if a metastatic spread is being discussed, the ovaries are the most common gates to the genital tissues because of the intrinsic features of ovarian stroma. It is thought that, the uterus and cervix might be possibly influenced by lymphatic spread from the ovary to the other genital sites [3].

The most common presenting symptom was abnormal vaginal bleeding (57%) followed by suspicious changes of the cervix on transvaginal ultrasound [6]. However, no clinical sign was present in 32% of the patients in literature and 41% of the reported cases were found only at autopsy [7]. Cervical cytology could diagnosed the neoplastic cells in only 50% of these cases [1]. No gynecologic sign or symptom was found in our patient and the result of the cervical cytologic was clear, as well. The only indication for operation was patient's anxiety and persistence for the operation. Prophylactic gynecologic operations in patients with predisposition to cancer are shown to be reduced the overall cancer risk. However, early onset menopause is an adverse effect which had to be discussed with the patient [8].

Metastatic involvement of the genital organs including the cervix should be considered in women with a history of breast cancer who present with vaginal bleeding or abnormal ultrasound. It should be kept in mind that sometimes these metastases might be asymptomatic and patient's desires should be taken into account while giving decision about her disease.

Competing interests

The authors declare that they have no competing interests.

References

1. Pérez-Montiel D, Serrano-Olvera A, Salazar LC, Cetina-Pérez L, Candelaria M, Coronel J, et al. Adenocarcinoma metastatic to the uterine cervix: a case series. J Obstet Gynaecol Res 2012;38(3):541-9.
2. Abrams HL, Spiro R, Goldstein N. Metastases in carcinoma: analysis of 1000 autopsied cases. Cancer 1950;3(1):74-85.
3. Bogliolo S, Morotti M, Valenzano Menada M, Fulcheri E, Musizzano Y, Casabona F. Breast cancer with synchronous massive metastasis in the uterine cervix: a case report and review of the literature. Arch Gynecol Obstet 2010;281(4):769-73.
4. Mazur MT, Hsueh S, Gersell DJ. Metastases to the female genital tract: analysis of 325 cases. Cancer 1984;53(9):1978-84.
5. Piura B, Yanai-Inbar I, Rabinovich A, Zalmanov S, Goldstein J. Abnormal uterine bleeding as a presenting sign of metastases to the uterine corpus, cervix and vagina in a breast cancer patient on tamoxifen therapy. Eur J Obstet Gynecol Reprod Biol 1999;83(1):57-61.
6. Famoriyo A, Sawant S, Banfield PJ. Abnormal uterine bleeding as a presentation of metastatic breast disease in a patient with advanced breast cancer on tamoxifen therapy. Arch Gynecol Obstet 2004;270(3):192-3.
7. Hepp HH, Hoos A, Leppien G, Wallwiener D. Breast cancer metastatic to the uterine cervix: analysis of a rare event. Cancer Invest 1999;17(7):468-73.
8. Rosen B, Kwon J, Fung Kee Fung M, Gagliardi A, Chambers A. Systematic review of management options for women with a hereditary predisposition to ovarian cancer. Gynecol Oncol 2004;93(2):280-6.

How to cite this article:
Pekindil G, Solmaz Hasdemir P, Tan A, Goksel G. Breast Cancer with Silent Metastasis to Uterine Cervix. J Clin Anal Med 2015;6(suppl 5): 647-9.