Pulmonary Embolism Mimicking Community Acquired Pneumonia: A Case Report

Toplum Kökenli Pnömoniyi Taklit Eden Pulmoner Emboli Olgusu

Pnömoniyi Taklit EdenPulmoner Emboli / Pulmonary Mimicking Pneumonia

İbrahim Koç[1], Yusuf Doğan[2], Onur Çakmak[3], Gökhan Bulut[4]
[1]Pulmonary Medicine, [2]Microbiology, [3]Internal Medicine, [4]Radiology, Viranşehir State Hospital, Sanlıurfa, Turkey

Özet

Akut pulmoner emboli venöz tromboembolinin sık görülen bir formu olup bazı olgularda fatal seyredebilmektedir. Hastalar sıklıkla özgün olmayan şikayet ve klinik bulgularla başvurmakta dolayısıyla tanı koymak zor olabilmektedir. Burada otuz yaşında bir erkek hastada ilk etapta toplum kökenli pnömoni saptanan ancak ileri incelemede pulmoner emboli olduğu anlaşılan bir olguyu sunmayı amaçladık. Otuz yaşında erkek hasta kliniğimize plörötik tarzda sağ yan ağrısı ve nefes darlığı şikayeti ile başvurdu. Akciğer grafisinde sağ akciğerde konsolidasyon ve plevral efüzyon saptandı. Fizik muayenede ateşi 38°C, oda havasında oksijen saturasyonu % 85 olan hastada uygulanan antibiyoterapi ve oksijen tedavisine cevap alınamadı. Akciğerin bilgisayarlı tomografi anjiografisinde sağ akciğerde pnömoni ve pulmoner emboli ile uyumlu bulgular saptandı. Kan ve balgam kültürlerinde üreme olmadı. Kardiyo-Vasküler Hastalıklara Yatkınlık (CVD) panelinde protrombin G20210A ve metilentetrahidrofolat redüktaz (MTHFR) C677T'de heterozigot mutasyon saptandı. Sonuç olarak pulmoner emboli toplum kökenli pnömoniyi taklit edebilmekte dolayısıyla klinisyenlerin tanı sürecinde dikkatli olması gerekmektedir.

Anahtar Kelimeler

Bilgisayarlı Tomografi Anjiografi; Pnömoni; Pulmoner Emboli

Abstract

Acute pulmonary trombo embolism is a form of venous thromboembolism that is common and sometimes even may be fatal. Patients might present with variable clinical presentation and often have non-specific complaints which make the diagnosis challenging. Here we aimed to report a thirty years old male who was diagnosed with community acquired pneumonia but further investigations revealed pulmonary embolism. A thirty years old male presented to our clinic with right sided chest pain and shortness of breath. Chest radiograph revealed right sided consolidations and pleural effusion. His physical examination revealed high body temperature (38 C°) and oxygen saturation on room air was 85 %. The patient did not respond to the antibiotherapy and oxygen supply. Computed tomography angiography of the chest revealed right sided pulmonary embolism with pneumonia. Blood and sputum cultures revealed no bacteria. Cardiovascular disease panel revealed heterozygous mutation in prothrombine G20210A and metilentetrahidrofolate reductase (MTHFR) C677T. In conclusion pulmonary embolism may mimic community acquired pneumonia thus clinicians must be carefull during the diagnostic process.

Keywords

Computed Tomography Angiography; Pneumonia; Pulmonary Embolism

DOI: 10.4328/JCAM.3770 Received: 14.07.2015 Accepted: 06.08.2015 Printed: 01.10.2015 J Clin Anal Med 2015;6(suppl 5): 662-4
Corresponding Author: İbrahim Koç. Pulmonary Medicine, Viranşehir State Hospital, Sanlıurfa, Turkey.
GSM: +905453142502 E-Mail: İbrahimkoc1981@gmail.com

Introduction

Pulmonary embolus (PE) refers to obstruction of the pulmonary artery or one of its branches by material (eg, thrombus, tumor, air, or fat) that originated elsewhere in the body. Acute pulmonary embolism is a form of venous thromboembolism (VTE) that is common and sometimes even may be fatal. Patients may present with different variable clinical presentations and often have nonspecific complaints which make the diagnosis challenging. The reported annual incidence of VTE differs ranging between 23-69 cases per 100,000 population, [1, 2] with approximately one third of patients presenting with acute PE and two thirds with deep vein thrombosis [3]. The evaluation of patients with suspected PE should be efficient so that patients can be diagnosed and therapy administered quickly to reduce the associated morbidity and mortality. Community acquired pneumonia may be complicated by pulmonary thromboembolism, but prevalence is low. The basic difficulty is sometimes to differ whether there is pneumonia or it is PE. Here we report a 30 years old male who was admitted to our clinic and had pulmonary embolism mimicking community acquired pneumonia.

Case Report

A thirty years old male was admitted to our hospital with complaints of right sided chest pain and shortness of breath. His medical and family histories were unremarkable. His physical examination revealed high body temperature (38o C), heart rate of 110 beats per minute, respiratory rate of 20 breaths per minute, blood pressure of 110/80 mm Hg, and SpO2 of 85% on room air. Physical examination of the chest revealed diminished movement of the right hemithorax and dullness over the right lung base along with diminished lung sounds in the right lover zone. His initial blood analyses were as follows: White blood cells;13040/uL (78.7% granulocytes, 8.1% lymphocytes, 12.5% monocytes, 0.7% eosinophils); Hb 12 gm/dL; Hct 36 %; platelets, 580,000/uL, ESR 50 mm/1st hour and serum CRP 200mg/L. Chest X-ray at admission was compatible with right sided pneumonia and pleural effusion. The patient was hospitalised and antibiotherapy started. About 20 mL of serofibrinous pleural fluid was obtained by thoracentesis from the right side under local anesthesia. Biochemical analysis of the pleural fluid revealed an exudative pleural effusion with LDH 320 U/L (normal range: 240-480 U/L), glucose 98 mg/dL, total protein 5.3g/dL and albumin 2.9 g/dL. Pleural fluid pH was 7.4. Low oxygen saturation, shortness of breath, previously no medical history and sudden onset of the disease aroused suspicion of acute PTE. Computed tomography angiography (CTA) of the chest revealed right sided pulmonary embolism, infiltration and pleural effusion (Figure 1-2). Blood, sputum and pleural fluid cultures revealed no bacteria. Hyperacute onset, no isolation with cultures else more no clinical, radiological and laborotory findings improvement after antibiotherapy was suggestive of pulmonary embolism other than pneumonia. Genetical analysis must be performed when PTE is seen before the age of 40 especially in those who has no previous medical or surgical history and immobilisation. CVD panel of our patient revealed heterozygous mutation in prothrombine G20210A and metilentetrahidrofolate reductase (MTHFR) C677T.

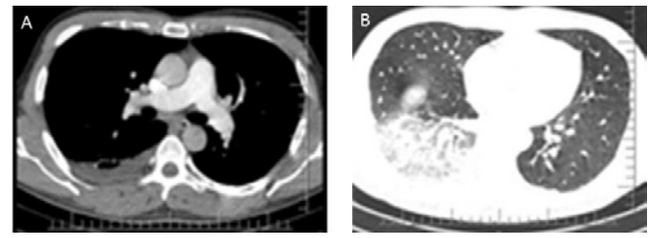

Figure 1. Computed tomography angiography of the chest revealed right sided pleural effusion (A) and pneumonic consolidation (B).

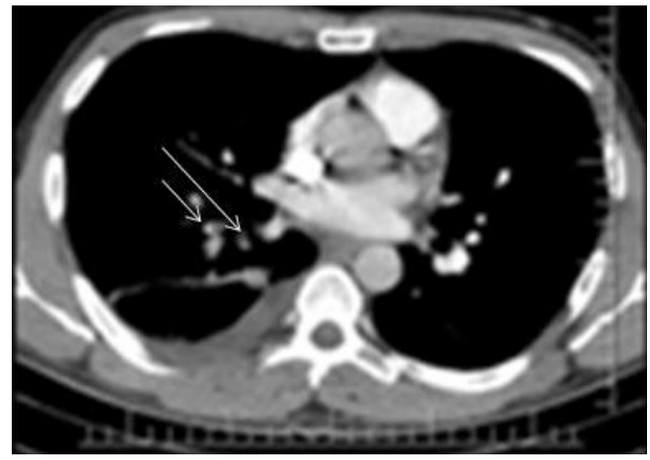

Figure 2. Computed tomography angiography of the chest revealed pulmonary tromboembolism in the right middle pulmonary artery (arrows).

Discussion

PTE is a disease that can frequently cause dyspnea, chest pain, fainting, and hemoptysis which can be mimicked by other pulmonary and cardiac diseases. Radiologic features of PTE on plain film are Fleishner sign: enlarged pulmonary artery (20%), Hampton hump: peripheral wedge of airspace opacity and implies lung infarction (20%), Westermark's sign: regional oligaemia (10%), pleural effusion (35%)[4]. On computed tomography angiography; webs or bands, intimal irregularities, abrupt narrowing or complete obstruction of the pulmonary arteries, "pouching defects" which are defined as chronic thromboemboli organised in a concave shape that "points" toward the vessel lumen [4]. It has been reported that prevelance of PTE in patients with pneumonia as high as 10% [5]. It has been shown that recent respiratory infection, acute infection and raised inflammatory markers, are associated with increased risk of thromboembolic disease [6]. Another study has proven that there are strong associations between recent respiratory infection and VTE which may be related to the severity of the infection [6, 7]. Community acquired pneumonia can be complicated by pulmonary thromboembolism, but prevalence is low. Eventhough they may co-exist also may be confused with each other. Our case was a young officer who had no previous medical history and risk factors for PTE. Low oxygen saturation, shortness of breath, previously no medical history and sudden onset of the disease aroused suspicion of acute PTE. Pulmonary embolism may mimic pneumonia, especially in those patients who has no a previos medical history and with acute onset of symptoms. On the other hand there are reported cases with co-existance of both diseases [8]. Clinicians must be carefull, acute onset of symptoms like shortness of breath, pleuritic chest pain, and hypoxemia should arouse suspician.

In conclusion pulmonary embolism may mimic community ac-

quired pneumonia thus clinicians must be careful during the diagnostic process.

Competing interests

The authors declare that they have no competing interests.

Refereances

1. Silverstein MD, Heit JA, Mohr DN, Petterson TM, O'Fallon WM, Melton LJ, 3rd. Trends in the incidence of deep vein thrombosis and pulmonary embolism: a 25-year population-based study. Arch Intern Med 1998 ;158:585-93.
2. Anderson FA Jr, Wheeler HB, Goldberg RJ, Hosmer DW, Patwardhan NA, Jovanovic B, et al. A population-based perspective of the hospital incidence and case-fatality rates of deep vein thrombosis and pulmonary embolism. The Worcester DVT Study. Arch Intern Med 1991;151:933-8.
3. White RH. The epidemiology of venous thromboembolism. Circulation 2003;107(23 Suppl 1):14-8.
4. Han D, Lee KS, Franquet T, Muller NL, Kim TS, Kim H, et al. Thrombotic and nonthrombotic pulmonary arterial embolism: spectrum of imaging findings. Radiographics 2003;23:1521-39.
5. Rohacek M, Szucs-Farkas Z, Pfortmuller CA, Zimmermann H, Exadaktylos A. Acute cardiac disorder or pneumonia and concomitant presence of pulmonary embolism. PLoS One 2012; DOI: 10.1371/journal.pone.0047418.
6. Clayton TC, Gaskin M, Meade TW. Recent respiratory infection and risk of venous thromboembolism: case-control study through a general practice database. Int J Epidemiol 2011;40:819-27.
7. Schmidt M, Horvath-Puho E, Thomsen RW, Smeeth L, Sorensen HT. Acute infections and venous thromboembolism. J Intern Med 2011;271:608-18.
8. Rokusz L. Case of Legionella pneumonia complicated with pulmonary thromboembolism. Acta Microbiol Immunol Hung 2010;57:401-6.

How to cite this article:
Koç İ, Doğan Y, Çakmak O, Bulut G. Pulmonary Embolism Mimicking Community Acquired Pneumonia: A Case Report. J Clin Anal Med 2015;6(suppl 5): 662-4.