# Cervical Myelopathy Induced by Ossification of Posterior Longitudinal Ligament

# Posterior Longitüdinal Ligament Osifikasyonuna Bağlı Servikal Miyelopati

PLLO'ya Bağlı Servikal Miyelopati / Cervical Myelopathy Induced by OPLL

Hidayet Sari[2], Hamza Sucuoglu[1], Sarmad Hussain[2], Ülkü Akarırmak[2]
[1]Department of Physical Medicine and Rehabilitation, Private Bagcilar Medicine Center,
[2]Department of Physical Medicine and Rehabilitation, Istanbul University, Cerrahpasa Medical Faculty, Istanbul, Turkey

**Özet**

Posterior longitüdinal ligament ossifikasyonu (PLLO), Asya kökenli kişilerde servikal miyelopatinin yaygın nedenlerinden biri olmasına rağmen, diğer ırklarda daha az da olsa görülebilmektedir. PLLO etiyolojisi halen net olmamakla birlikte genetik, hormonal ve çevresel faktörlerle ilişkili olduğu kabul edilmektedir. Servikal miyelopati oluşumunda ayrı bir klinik antite olarak karşılaşılan PLLO hiçbir belirti oluşturmayabileceği gibi, ilerleyici nörolojik hasarlara, denge ve yürüme bozukluklarına kadar bir dizi klinik belirtilerle de seyredebilmektedir. PLLO tanısı, tedavi planlaması ve takibi açısından direkt grafi, BT ve MRG önemli yardımcı yöntemlerdir. Tedavide ilerleyici nörolojik bozukluğu olmayan veya hafif miyelopati belirtilerine sahip hastalarda konservatif yaklaşımlar denendiğinde başarılı sonuçlar alınabilmektedir. Ancak, ilerleyici miyelopati bulguları olanlarda cerrahi yaklaşım esas olup, cerrahi yöntemin seçimi hala oldukça tartışmalı bir konudur. Biz de bu amaçla, yaşlı erkek Türk hastamızda servikal miyelopati oluşumuna neden olan PLLO'nun tanı ve tedavisini olgumuz eşliğinde tartışarak sunuyoruz.

**Anahtar Kelimeler**

Servikal Miyelopati; Posterior Longitüdinal Ligament; Ossifikasyon; Rehabilitasyon

**Abstract**

Ossification of Posterior Longitudinal Ligament (OPLL), despite being one of the common causes of cervical myelopathy in Asian subjects it also can be seen less in other races. Although OPLL etiology is still unclear, it is considered to be related to genetic, hormonal and environmental factors. As OPLL; that is encountered as a distinct clinical entity in the formation of cervical myelopathy; may not cause any symptom, it also can be presented with a serie of clinical symptoms like progressive neurological damage and disturbance of balance and gait. Direct X-ray, CT and MRI are important auxiliary method in terms of OPLL diagnosis, treatment planning and follow-up. In patients with no progressive neurological damage or mild symptoms of myelopathy conservative approach can be successful in the treatment. However, surgical approach is the main in patients with progressive myelopathy, the choice of surgical technique is still quite controversial. We therefore offer to discuss the diagnosis and treatment of OPLL that induced cervical myelopathy in our old aged male Turkish patient.

**Keywords**

Cervical Myelopathy; Posterior Longitudinal Ligament; Ossification; Rehabilitation

DOI: 10.4328/JCAM.3804 Received: 01.08.2015 Accepted: 01.09.2015 Printed: 01.10.2015 J Clin Anal Med 2015;6(suppl 5): 685-8
Corresponding Author: Hamza Sucuoglu, Fatih Neighborhood, Maslak Street, Ilke Street, No. 1 Bagcilar, Istanbul, Turkey.
GSM: +905056297688 F.: +90 2125784677 E-Mail: hamzasucuoglu@mynet.com.tr

## Introduction

Ossification of the posterior longitudinal ligament (OPLL) of the cervical spine, although reported at 1839 its relation with cervical myelopathy was described at 1960's and in recent years has been considered as a distinct clinical entity [1]. This case is common in Japan and reported rarely in other communities. The etiopathogenesis of OPLL is poorly explained and it is thought to be the result of genetic or geographical factors [2]. Of those presenting with OPLL of the cervical spine, the majority tend to be between 50 and 60 years of age with a male to female ratio of about three to one [1,2]. Cervical myelopathy (CM) is a medulla spinalis injury that results from cervical spondylosis and stenosis caused most often by degenerative causes such as osteophyte, disc calcification and facet hypertrophy. Despite that CM related to OPLL is primarily seen in Asian populations it is also reported in other populations in the literatures [3]. The most common complaint is upper limb weakness and decreased dexterity [4]. Examination consists of a mixture of first and second motor neuron signs. The first motor neuron signs are located under the lesion level and weakness, spasticity, increase in the DTR, pathological reflexes (clonus, Babinski, Hoffman) can be seen [4]. In the diagnosis of CM and OPLL cervical X-ray, computed tomography (CT) and magnetic resonance imaging (MRI) are very helpful. In the treatment of CM cases surgical decompression and / or immobilization is firstly recommended [3]. Conservative treatment methods can be tried in patients with no fast progression, mild myelopathy symptoms or whom refuse undergoing surgery [3,5]. The aim of this case report is to discuss the etiopathogenesis, diagnosis and treatment of OPLL in our Turkish patient with cervical myelopathy due to OPLL.

## Case Report

A 65 aged male patient presented with walking difficulty, balance disturbance and weakness in left arm and leg. The weakness of the left arm started 1,5 year ago then the walking and balance disturbance were added. Patient was admitted to different clinics with these complaints. When the cervical MRI showed that the patient's spinal cord was under pressure he was admitted in our ward for further investigations and treatment. It was learned that our patient had undergone a lumbar disc herniation surgery and left foot drop had developed after that and 23 years ago he had a car traffic accident. In the physical examination; left foot drop and walking with a cane due to balance impairment was observed. Cervical range of motion in all directions was moderately limited and painless. Neurological examination and EMG findings are shown in Table 1. In the laboratory examination hemogram and biochemistry were normal. Cervical X-ray and CT showed that OPLL was extended towards the spinal canal between C3 and C7 levels (Figure 1,2), and spinal compression and myelopathy were seen in the MRI (Figure 3). With these findings the patient was diagnosed with cervical spondylotic myelopathy related to mixed type OPLL. According to Japanese Orthopaedic Association classification [6], our patient was evaluated as grade 1 (JOA Score: 12/17). Accordingly, a conservative treatment was decided to be applied due to the mild myelopathy findings in our patient, symptoms with no rapid progression and the operation refusal by the patient. Treatment of patient : Cervical collar , infrared (500 watt,

Table 1. Neurological Examination and EMG findings

| Neuorological Examination |
|---|
| Muscle strength*: Right upper extremity 5/5, left upper extremity 4/5, in lower extremities; left ankle dorsiflexion and toe extension 1/5, others were 5/5 |
| Sensory: Left Cervical (C), C6-C7-C8 and L2-L3-L4-L5 dermatomes were hypoesthetic |
| DTR: upper extremities were normoactive, left patellar reflex was hyperactive and achilles reflexes bilaterally absent |
| Pathologic reflexes: Babinski and Hoffman were bilaterally positive. |
| **EMG Findings** |
| Nerve conduction study is normal. Signs of chronic anterior horn cells damage. SEP has low amplitude. |

*Muscle strength: Evaluated according to Oxford scale.
DTR: Deep tendon reflexes. EMG: Electromyography. SEP: Somatosensory evoked potential.



Figure 1. Lateral cervical x-ray: Mixed type (segmental+continuous) OPLL narrowing the spinal canal between C3-C7.

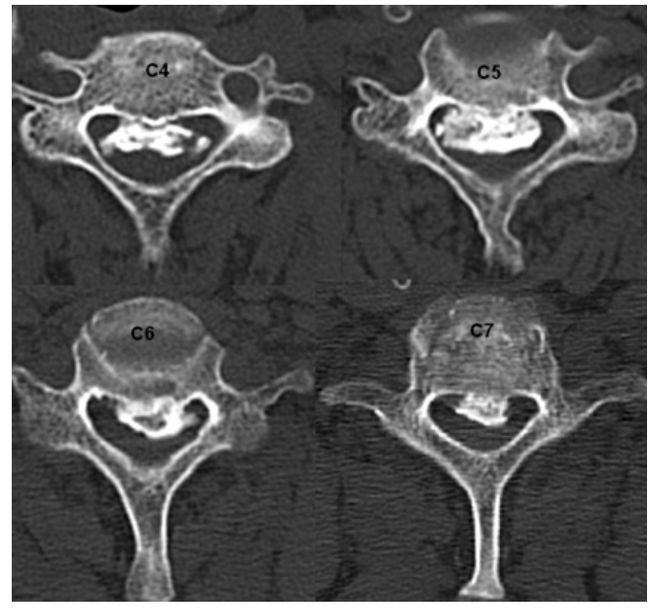


Figure 2. Cervical axial CT: Severe spinal canal narrowing at C3, C4, C5, C6 and C7 vertebral body levels due to OPLL.



Figure 3. Cervical MRI, saggital T2 sequences: Severe spinal canal narrowing, spinal cord thinning and myelomalacic changes due to OPLL between C3-C7.

20 minutes each session, lamp positioned perpendicular to the neck with the patient in sitting position) and ultrasound ( frequency of 1MHz, 1.5 W/cm2 intensity, 10 minutes each session) for the neck region, transcutaneous electrical nerve stimulation (TENS ) (in conventional mode, frequency of 100Hz, 100μs pulse duration, 20 minutes each session), left upper extremity and the ankle dorsiflexion muscle group electrostimulation (frequency of 20-50Hz, amplitude: 0-100 mA, pulse duration: according to optimal contraction, 15 minutes each session), balance - coordination and walking exercises with a rehabilitation program involving the left upper and lower extremity strengthening exercises were applied. Although there was no significant difference in muscle strength after thirty treatment sessions (5 sessions/ week for 6 weeks), patient had significant improvement in balance and coordination that helped him to walk unaided.

**Discussion**

Ossification of the posterior longitudinal ligament (OPLL) is most commonly found in men, in the elderly patients [3]. The incidence of OPLL is 2.4% in the Asian population, and 0.16% in the non-Asian population [7]. While our patient was of a Turkish race despite being an old male. The pathogenesis of OPLL is still unknown. There is some evidence that ligament cells from OPLL patients have osteoblast-like characteristics. Many factors are thought to be the cause of the formation and progression of OPLL like genetic, hormonal, environmental factors and life style but there is no consensus of opinion about this [3]. Although spinal cord injury secondary to road traffic accidents proved to be a predisposing factor for OPLL development, the role of previous traffic accidents in the formation of OPLL is still unclear [8].

OPLL is formed mainly through enchondral ossification, and part of it develops through membranous ossification [3]. In most OPLL cases there is no complaint or mild pain and numbness can be found in the early period. With the progression of neurologic deficits, lower extremity symptoms, such as gait disturbance may appear. OPLL patients show symptoms of myelopathy caused by spinal cord compression rather than radicular pain due to nerve roots compression [3]. In the examination; at the compression level radicular symptoms and below the compression level upper motor neuron symptoms as DTR increasment, pathological reflexes and spasticity are frequently encountered. Also, walking and balance disturbance forms an important problem [3]. For this purpose, for determining the functional status of patients with cervical myelopathy, a scoring system by the Japanese Orthopaedic Association (JOA Score) is determined [6]. By this scoring system upper and lower extremity motor function, upper and lower extremities and trunk sensory function with bladder and bowel function are evaluated. JOA total score is 0–17. The lower the score the more severe is the deficit. Normal function 16 - 17, Grade 1: 12–15, Grade 2: 8–11, Grade 3: 0–7. According to this scoring system our patient was evaluated as JOA score 12 with grade 1. Direct X-ray, CT and MRI are important auxiliary method in terms of CM and OPLL diagnosis, treatment planning and follow-up [3]. Plain radiography is the simplest method to detect OPLL, but it has some limitations especially in the early stages of the disease [3]. OPLL is classified into the following: local type, segmental type, continuous type, and mixed type based on plain radiographic findings. Our patient had a mixed type OPLL according to this classification. Although CT is very successful in terms of viewing osteophytes and calcified discs and evaluating the dimensions of the spinal canal but it does not properly evaluate the spinal cord and cervical roots. In this respect, MRI is highly useful in evaluating spinal cord pressure and the relation between soft tissues and adjuvant bone [4]. In our case, spinal canal narrowing related to mixed type OPLL at the levels between C3 and C7 was obviously seen in x-ray and CT scan while in MRI severe narrowing of the spinal canal at the same level, medulla spinalis thinning and myelomalasic changes were seen. When CM symptoms are mild and not progressive conservative treatment and close follow-up may be good enough. As symptomatic treatments, pain medication, anti-inflammatory drugs, antidepressants, anticonvulsants, and opioid can be applied, and physical therapy such as a brace, are recommended for local stabilization. But when myelopathy findings and neurological symptoms are progressive the surgical treatment is preferred to relieve the spinal cord compression. Surgical approach can be selected based on the degree of myelopathy, the number of involved segments, the location of the primary pathology, the sagittal balance of cervical spine and surgeon's experiences [3]. We applied a conservative treatment to our patient because the myelopathy symptoms are mild and without rapid progression and also the patient did not want a surgical operation. After the treatment our patient became able to walk independently and an improvement in balance and coordination was seen.

**Conclusion**

OPLL, despite being one of the common causes of cervical myelopathy in Asian subjects it can be seen albeit less in other races. OPLL etiology is still unclear. Direct X-ray, CT and MRI are important auxiliary method in terms of OPLL diagnosis and treatment planning. The treatment planning must be done by understanding the advantages and limitations of each method and by considering the neurological condition and the prior medical history of the patient.

*Competing interests*

The authors declare that they have no competing interests.

**References**

1. Terayama K. Genetic studies on ossification of the posterior ligament of the spine. Spine 1989;14:1184-91.
2. Epstein N. The surgical management of ossification of the posterior longitudinal ligament in 51 patients. J Spinal Disord 1993;6:432-55.
3. Choi BW, Song KJ, Chang H. Ossification of the posterior longitudinal ligament: A review of literature. Asian Spine J 2011;5(4):267-76.
4. Göçmez C, Kamaşak K. Önemli bir tetraparezi nedeni: Servikal spondilotik miyelopati. Dicle Tıp Derg 2013;40(3):513-20.
5. Sari H, Sucuoglu H, Ornek NI, Misirlioglu TO, Uludag M. The development of upper thoracic myelopathy due to posterior vertebral osteophyte and ossification of ligamentum flavum in patient with diffuse idiopathic skeletal hyperostosis. Turk J Phys Med Rehab 2012;58:342-3.
6. Yue WM, Tan SB, Tan MH, Koh DC, Tan CT. The Torg-Pavlov-ratio in cervical spondylotic myelopathy: a comparative study between patients with cervical spondylotic myelopathy and a nonspondylotic, nonmyelopathic population. Spine 2001;26(16):1760-4.
7. Tsuyama N. Ossification of the posterior longitudinal ligament of the spine. Clin Orthop Relat Res 1984;184:71-84.
8. Gu Y, Chen L, Dong RB, Feng Y, Yang HL, Tang TS. Laminoplasty versus conservative treatment for acute cervical spinal cord injury caused by ossification of the posterior longitudinal ligament after minor trauma. Spine J. 2014;14(2):344-52.

*How to cite this article:*
Sari H, Sucuoglu H, Hussain S, Akarırmak Ü. Cervical Myelopathy Induced by Ossification of Posterior Longitudinal Ligament. J Clin Anal Med 2015;6(suppl 5): 685-8.