Cubital Tunnel Syndrome Due to Synovial Cyst: A Case Report

Sinovyal Kistin Neden Olduğu Kubital Tünel Sendromu: Bir Olgu Sunumu

Periferik Tuzak Nöropati / Peripheral Entrapment Neuropathy

Zahir Kizilay[1], Ali Yilmaz[1], Nusret Ok[2]
[1]Neurosurgery Department, Adnan Menderes University Medicine Faculty, Aydın,
[2]Orthopaedics and Traumatology Department, Pamukkale University Medicine Faculty, Denizli, Turkey

Özet

Sol dirsek ekleminden köken alan bir sinovyal kistin neden olduğu nadir bir ulnar sinir tuzak nöropatisi vakasını sunuyoruz. Elli yedi yaşında erkek bir hasta, 7 aydır sol dirsekte ağrı ve sol elde ilerleyici ve artan bir uyuşukluk ve güçsüzlük şikayetiyle kliniğimize başvurdu. Hastanın yapılan nörolojik muayenesinde 4. ve 5. parmakta güçsüzlük ve his kaybı olduğu tespit edildi. Özellikle hastanın sol dirseği fleksiyon pozisyonuna getirdiğinde Tinel işareti ve Phalen testinin positifti. Elektromiyografi de sol kubital tünel alanında aksonal yaralanma ve tuzak nöropati olduğu tespit edildi. Cerrahi tedavi olarak, total sinovyal kist eksizyonu ve ulnar sinir anterior subkutanöz transpozisyonu yapıldı. Hastanın ağrı şikayeti cerrahiden hemen sonra azaldı. Bu vaka sunumunda, sinovyal kistin neden olduğu kubital tünel sendromunun patofizyolojisi ve bu gibi vakalarda hangi cerrahi tekniğin uygun olabileceği tartıştık.

Anahtar Kelimeler

Ulnar Sinir; Kübital Tünel; Sinovyal Kist; Tuzak Nöropati

Abstract

We report a rare case of ulnar nerve entrapment caused by a synovial cyst derived from the left elbow joint. A 57-year-old male patient with a seven-month history of pain in his left elbow and a progressive and increasing numbness and weakness complaints in his left hand came to our clinic. Weakness and sensory loss of the 4th and 5th fingers were determined in neurological examination. The results of Tinel's sign and Phalen's Test were positive, especially when his left elbow was flexed. In electromyelography, axonal damage and entrapment neuropathy were determined in the left cubital tunnel area. Total excision of the synovial cyst and ulnar nerve anterior subcutaneous transposition were performed in surgical treatment. The patient's pain decreased immediately after the surgery. In this report, we have discussed the pathopysiology of cubital tunnel syndrome due to synovial cyst and which surgical technique may be suitable as our case report.

Keywords

Ulnar Nerve; Cubital Tunnel; Synovial Cyst; Entrapment Neuropathy

DOI: 10.4328/JCAM.3826 Received: 08.08.2015 Accepted: 31.08.2015 Printed: 01.10.2015 J Clin Anal Med 2015;6(suppl 5): 692-4
Corresponding Author: Zahir Kizilay, Neurosurgery Department, Adnan Menderes University Medicine Faculty, 09100 Aytepe, Aydin, Turkey.
T.: +90 2564441256 F.: +90 2562148395, +90 2562142040 E-Mail: zahir.kizilay@adu.edu.tr

Introduction

Ulnar nerve entrapment is the second most-frequent entrapment neuropathy after median nerve entrapment in upper limbs [1]. The ulnar nerve can be compressed at many point, but it is most often observed in the cubital tunnel. The dynamic anatomy and biomechanics of the cubital tunnel affect the ulnar nerve, and result in relative regional ischemia on the nerve. Dynamic and static compression can develop from lesions occupying the space in a limited area such as the cubital tunnel [2]. In this study, we present a rare case of a synovial cyst which was derived from the left elbow joint. The patient's complaints increased when his elbow joint was flexed.

Case Report

The case was a 57-year-old male patient with a seven-month history of pain, and progressive and increasing numbness and weakness in his left hand. Weakness and sensory loss of the 4th and 5th fingers were determined in neurological examination. The Tinel's Sign and Phalen's Tests were performed, and his pain was observed as being positive, especially when his left elbow was flexed. The sensory response of the left ulnar nerve could not be detected, the potential amplitude of the compound muscle action was very low, and electromyography showed ulnar nerve entrapment neuropathy with axonal damage at the elbow into the cubital tunnel. Therefore we decided to perform surgery. After obtaining the Informed Patient Consent, we performed an incision in the subcutaneous tissue and opened the cubital tunnel ceiling. During the dissection of the base surface of the cubital tunnel, we observed a cyst which was filled with gelatinous fluid compressing the ulnar nerve (Figure 1). The cyst was totally resected and the ulnar nerve anterior subcutaneous transposition was performed. The patient's pain was relieved immediately after the surgery. Pathological examination was evaluated in favor of a synovial cyst (Figure 2).

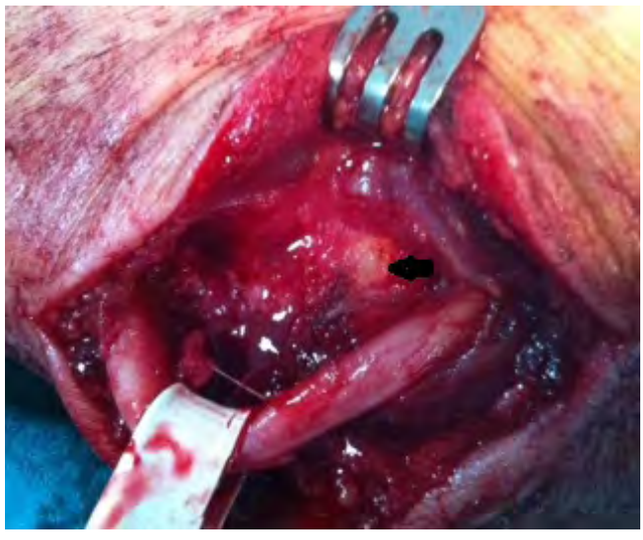

Figure 1. Image of the synovial cyst (black arrow) coming from the left elbow joint and located in the cubital tunnel base surface.

Discussion

Cubital tunnel syndrome is the second most-frequent upper limb entrapment neuropathy after carpal tunnel syndrome [1]. Many ethological factors have been reported in the literature

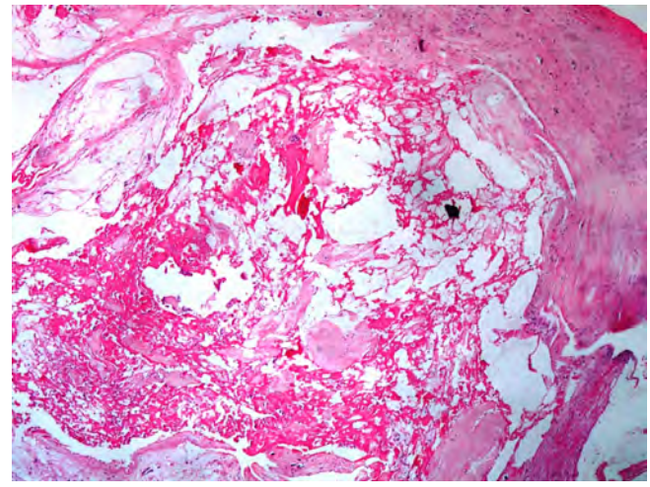

Figure 2. Pathological examination of the synovial cyst with haematoxylin and eosin x 10, synovial membrane and its mucinous content.

such as external traumas in progress, muscles irregulate, subluxation of the ulnar nerve on the medial epicondyle, cubitus valgus, tenosynovitis of rheumatoid arthritis, elbow fractures or dislocations [3]. In addition, soft tissue bulks such as ganglion cysts, synovial chondromatosis and synovial cysts may be considered among rare factors [2]. However, most of the reported cases are idiopathic [4].

The cubital tunnel is defined as an oval tunnel in the elbow through which the ulnar nerve passes. Its upper part is formed by Osborne's Ligament, and its base surface is formed by the elbow joint capsule. The lateral border is formed by the olecranon, and the medial border is formed by the medial epicondyle. The simultaneous effects of elbow movements on the cubital tunnel and the ulnar nerve have been shown in many previous studies. It has been demonstrated in these studies that the cubital tunnel is flattened during the flexion of the elbow, and when the volume of the cubital tunnel decreases by 55%, the pressure in the tunnel increases seven-fold. When contraction of the flexor carpi ulnaris muscle accompanies elbow flexion, the pressure in the tunnel increases more than 20-fold [5, 6]. In addition, the ulnar nerve moves, and is elongated by stretching during the flexion of the elbow with the decrease in the volume of the cubital tunnel [7]. Therefore, it has been claimed that there might be two mechanisms in the pathogenesis of the syndrome that appears due to the trapping of the ulnar nerve in the cubital tunnel in the elbow. These are claimed to be the stretching of the nerve, and the dynamic compression or the repetitive trauma. The dynamic compression, or the repetitive trauma, has been defined as being distal to the cubital tunnel entrapment or being within this entrapment [8].

In our case, the reason for the cubital tunnel syndrome was observed to be the synovial cyst in the elbow; however, the fact that the complaints increased when the elbow of the patient was flexed suggested that it had an effect on the stretching and dynamic compression in pathophysiology. In our study, when the synovial cyst, which is causing the pressure, is related to the elbow joint, the pressure in the cyst may also increase as secondary to the intra-joint pressure with the flexion of the joint, and this may result in the growth of the cyst into the tunnel. As a natural result of this, the cubital tunnel, which has been narrowed in the flexion, may even become narrower, possibly

leading to a secondary damage with the dynamic compression of the nerve. In addition, the cyst growing in the flexion may push the nerve upwards from the cubital tunnel ceiling surface, and this may lead to the compression of the nerve as well as suspension of it, thus increasing the tension in the nerve and eventually leading to a secondary injury to the nerve. Actually, this process is similar to the pathological process in radiculopathy formation based on disc herniation. As a result, this increasing compression and tension may destroy the intra-neuronal micro-circulation and axonal transportation and thus lead to clinical findings.

The in situ decompression with mini incision, and endoscopic decompression have both become popular recently, because they are minimally invasive methods. These methods are more suitable for selected cases. On the other hand, when the reason for the cubital tunnel syndrome is a synovial cyst which may originate from the elbow joint, as in our study, these two minimal invasive methods may be insufficient as the pressure on the nerve comes from the base surface of the cubital tunnel, and the patient will eventually need revision surgery. For this reason, we chose the anterior subcutaneous transposition of the ulnar nerve in our case.

Finally, although rare, synovial cysts originating from the elbow joint may be among the ethological reasons for cubital tunnel syndrome. It must be kept in mind that there might be an etiological factor in patients whose complaints increase when the elbow is in flexion. Ulnar nerve damage in the cubital tunnel may be influenced not only by dynamic compression but also by a damage mechanism based on stretching. Anterior subcutaneous transposition is one of the most suitable methods for pathologies originating from the cubital tunnel base surface.

We have no financial interest in this manuscript, and we certify that there is no actual or potential conflict of interest in relation to this article.

Competing interests

The authors declare that they have no competing interests.

References

1. Asamoto S, Böker DK, Jödicke A. Surgical treatment for ulnar nerve entrapment at the elbow. Neurol Med Chir 2005; 45:240-5.
2. Li Y, Lao J. The cubital tunnel syndrome caused by the two synovial cysts. J Plast Reconstr Aesthet Surg 2012; 65(6):827-9.
3. Andreisek G, Crook DW, Burg D, Marincek B, Weishaupt D. Peripheral neuropathies of the median, radial, and ulnar nerves: MR imaging features. Radiographics 2006;26(5):1267-87.
4. Erol B, Tetik C, Sirin E. The mid-term results of minimal medial epicondylectomy and decompression for cubital tunnel syndrome. Acta Orthop Traumatol Turc 2004;38(5):330-6.
5. Apfelberg DB, Larson SJ. Dynamic anatomy of the unlar nerve at the elbow. Plast Reconstr Surg 1973;51.79-81.
6. Werner CO, Ohlin P, Elmqvist D. Pressures recorded in ulnar neuropathy. Acta Orthop Scand 1985;56:404-6.
7. Gökay NS, Bagatur AE. Subcutaneous anterior transposition of the ulnar nerve in cubital tunnel syndrome. Acta Orthop Traumatol Turc 2012;46(4):243-9.
8. Simsek S, Er U, Demirci A, Sorar M. Operative illustrations of the Osborne's ligament. Turk Neurosurg 2011; 21(2):269-70.

How to cite this article:
Kizilay Z, Yilmaz A, Ok N. Cubital Tunnel Syndrome Due to Synovial Cyst: A Case Report. J Clin Anal Med 2015;6(suppl 5): 692-4.