

Non-Operative Management of Isolated Pneumoperitoneum Due to Severe Blunt Abdominal Trauma

Şiddetli Künt Karın Travmasına Bağlı İzole Pnömoperitonyumun Cerrahi Dışı Yönetimi

Künt Karın Travmasında İzole Pnömoperitonyum / Isolated Pneumoperitoneum in Blunt Abdominal Trauma

Murat Özgür Kılıç[1], Mikdat Bozer[1], Ahmet Türkan[1], Yeliz Kılıç[2]
[1]Department of Surgery, Faculty of Medicine, Turgut Ozal University,
[2]Clinic of Anesthesiology and Reanimation, Dr. Abdurrahman Yurtarslan Oncology Training and Research Hospital, Ankara, Turkey

An abstract of this article was presented as a poster in 19. National Surgery Congress, 2014.

Özet

Künt karın travmasının cerrahi dışı yönetimi hemodinamik olarak stabil hastalarda tercih edilen tedavi yöntemidir. Cerrahi dışı yönetimin sonuçları, içi boş organ yaralanmasına göre, karaciğer ve dalak gibi izole solid organ yaralanmalarında daha başarılıdır. Bu yaklaşımda, hem hastanın klinik seyri hem de bilgisayarlı tomografi bulguları önemli bir rol oynar. Künt karın travmasında serbest peritoneal hava klinisyenler için cerrahi bir zorluk olabilir çünki genellikle içi boş organ perforasyonu için önemli bir radyolojik işarettir. Burada, ciddi bir künt karın travmasına maruz kalan genç bir erkekte, bilgisayarlı tomografide saptanan ve cerrahisiz yönetilen, izole pnömoperitonyum olgusu sunuyoruz. Amacımız, künt karın travmasında, diğer radyolojik bulguların yokluğunda, pnömoperitonum varlığının yönetim sorunlarına cerrahların ilgisini çekmektir.

Anahtar Kelimeler

Abstract

Nonoperative management of blunt abdominal trauma is the treatment of choice for hemodynamically stable patients. The results of nonoperative management are more successful in isolated solid organ injuries such as the liver and spleen than hollow viscus injury. In this approach, both the clinical course of the patient and the computed tomography findings play an important role. Isolated pneumoperitoneum in blunt abdominal trauma may be a surgical challenge for clinicians because it is usually a significant radiological sign for hallow viscus perforations. Here, we report a case of isolated pneumoperitoneum detected on computed tomography and managed non-surgically, in a young man suffered from a severe blunt abdominal trauma. Our aim is to attract the attention of surgeons to the management problems of the presence of pneumoperitoneum in the absence of other radiological findings in blunt abdominal trauma.

Keywords

DOI: 10.4328/JCAM.3847 Received: 21.08.2015 Accepted: 02.08.2015 Printed: 01.10.2015 J Clin Anal Med 2015;6(suppl 5): 698-700
Corresponding Author: Ahmet Türkan, Department of General Surgery, Faculty of Medicine, Turgut Ozal University, Ankara, Turkey,
Gsm: +905055951637 E-Mail: draturkan@gmail.com

Introduction

In recent years, there have been significant changes in the approach to blunt abdominal trauma. Conservative approaches have been increasingly used according to the improvements in radiological methods such as ultrasonography (US) and computed tomography (CT), interventional radiology, and critical care [1]. Although many cases with blunt abdominal injury can be managed non-surgically, this decision may not be always received easily. In some cases with blunt injury, free peritoneal air detected by radiological methods, may be the single imaging finding and may not always indicate perforation of hollow viscus. In this condition, such patients should be evaluated as a whole with repeated physical examinations, laboratory findings and advanced radiological tests before taking a decision of emergent surgery.

Case Report

A 42-year-old man was brought to emergency room with severe crush injury on the upper half of his body caused by an accident during the repair of lift. The patient was hemodynamically stable and the laboratory findings were all within normal limits. On clinical examination, the abdomen was soft and painless. Chest x-ray revealed pneumothorax, 1 cm in size, in both hemithorax. On abdominal plain radiography, peritoneal free air was not determined. US showed no abnormality. Computed tomography (CT) visualized peritoneal free air in right subphrenic space in the absence of free fluid and solid organ injury (figure). Additionally, there was no evidence of traumatic rupture of the diaphragm. However, fractures were detected in three ribs with minimal pneumothorax. The patient had also minor fractures in lombar 1-4 vertebras and left scapula. Pneumoperitoneum was thought to derive from pneumothorax. The patient was closely monitored at the intensive care unit without any surgical intervention. The subsequent course was uneventful and the patient was discharged on tenth day.

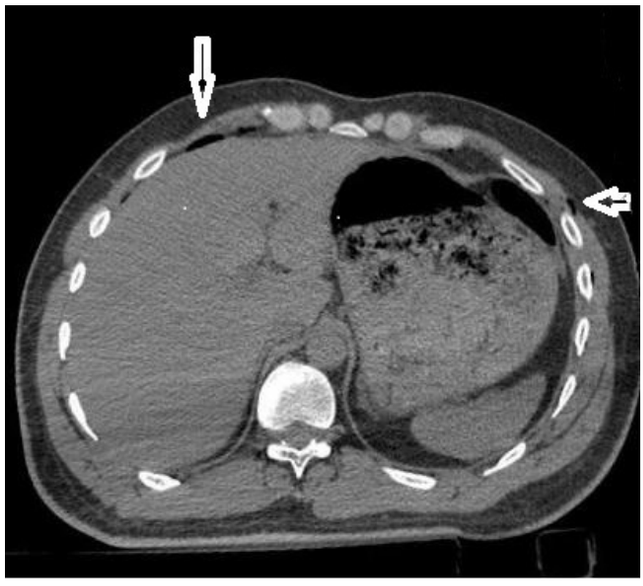

Figure. Tomographic image of free subdiaphragmatic peritoneal air (arrows)

Discussion

In blunt trauma, the clinical findings are usually not reliable. The management of blunt abdominal trauma is quite difficult and requires much attention. CT scan has become the diagnostic modality of choice in the management of patients with blunt abdominal injury [2,3]. Use of CT scan has dramatically changed the methods for diagnosing blunt abdominal trauma and refined the surgeon's decisions. It is mainly indicated for hemodynamically stable patients with equivocal findings on physical examination. In addition, drugs, alcohol, head trauma and spinal cord injury are the other endications for CT use [3]. CT is very useful in defining the severity of solid organ injury such as liver, spleen and kidney and guiding the NOM and decisions for laparotomy. In blunt abdominal trauma, gastrointestinal perforation is one of the most common causes of intraperitoneal free air. These perforations are emergency conditions requiring an early recognition and a timely surgical treatment. CT is the best imaging method of detecting it but no clear consensus exists on its role especially in hollow viscus and mesenteric injuries. Although the presence of pneumoperitoneum in blunt abdominal trauma was a certain indication of laparotomy previously, effective and commonly use of CT in blunt abdominal trauma enabled surgeons to select patients for conservative treatment, and therefore the rate of conservative approaches has began to increase in recent years. Neverthless, missed hollow viscus injuries still remain a significant problem, as they considerably increase morbidity and mortality in patients with multiply trauma. It should be noted here that pneumoperitoneum detected by CT scan, is not always result from perforation of the gastrointestinal tract and thus may not require laparotomy [4]. Because only 45% of patients with gastrointestinal perforation have free peritoneal air on imaging methods [5]. This condition is called as spontaneous, nonsurgical, or idiopathic pneumoperitoneum, and usually poses a dilemma to the surgeon. Mechanical ventilation, cardiopulmonary resuscitation and pneumomediastinum are the other causes of free intraperitoneal air [6]. Hamilton et al. also reported that pneumoperitoneum can be developed secondary to dissection of interstitial air from the chest [7]. Similarly, in our case, free intraperitoneal gas was thought to derive from pneumothorax, according to the normal clinical findings and the absence of radiological findings indicating any abdominal organ injury.

In conclusion, the presence of free intraperitoneal air in blunt abdominal trauma without a detectable solid organ injury is a significant surgical dilemma for most surgeons. It should be kept in mind that free peritoneal gas may occur as a result of extra-abdominal conditions as was in our case. Although surgery is the main treatment in the presence of pneumoperitoneum previously, hemodynamically stable patients with normal abdominal examination findings can be managed conservatively in blunt abdominal trauma, with closed monitoring.

Competing interests

The authors declare that they have no competing interests.

References

1. Ozoğul B, Kısaoğlu A, Aydınlı B, Oztürk G, Bayramoğlu A, Sarıtemur M et al. Non-operative management (NOM) of blunt hepatic trauma: 80 cases. Ulus Travma Acil Cerrahi Derg 2014;20(2):97-100.
2. Thorelius L. Emergency real-time contrast-enhanced ultrasonography for the detection of solid organ injuries. Eur Radiol Suppl 2007;17(Suppl.6):107–12.
3. Peitzman AB, Makaroun MS, Slasky BS, Ritter P. Prospective study of com-

puted tomography in initial management of blunt abdominal trauma. J Trauma 1986;26(7):585–92.
4. Marek AP, Deisler RF, Sutherland JB, Punjabi G, Portillo A, Krook J et al. CT scan-detected pneumoperitoneum: An unreliable predictor of intra-abdominal injury in blunt trauma. Injury 2014;45(1):116-21.
5. Kumar A, Muir MT, Cohn SM, Salhanick MA, Lankford DB, Katabathina VS. The etiology of pneumoperitoneum in the 21st century. J Trauma Acute Care Surg 2012;73(3):542-8.
6. Mularski RA, Sippel JM, Osborne ML. Pneumoperitoneum: a review of nonsurgical causes. Crit Care Med 2000;28(7):2638-44.
7. Hamilton P, Rizoli S, McLellan B, Murphy J. Significance of intra-abdominal extraluminal air detected by CT scan in blunt abdominal trauma. J Trauma 1995;39(2):331-3.

How to cite this article:
Kılıç M.Ö, Bozer M, Türkan A, Kılıç Y. Non-Operative Management of Isolated Pneumoperitoneum Due to Severe Blunt Abdominal Trauma. J Clin Anal Med 2015;6(suppl 5): 698-700.