Comparison of Catether Angiography with Magnetic Resonance Angiography in the Diagnosis of Renal Artery Stenosis

Renal Arter Stenozunda Kateter Anjiografi ile Manyetik Rezonans Anjiyografi Bulgularının Karşılaştırılması

Mustafa Çetin[1], Aykut Recep Aktaş[2], Özhan Özgür[1], Kamil Karaali[1], Emel Alimoğlu[1], Ahmet Alparslan[1], Timur Sindel[1]
1Dept. of Radiology, Akdeniz University Faculty of Medicine, Antalya,
2Dept. of Radiology, Suleyman Demirel University Faculty of Medicine, Ispart, Turkey

Özet

Amaç: Tüm hipertansiyonlu olgular göz önüne alındığında, bunların %1–5'inde neden renal arter stenozudur (RAS). Renovasküler hastalığın erken tanı ve tedavisi, renal fonksiyonların korunması bakımından önemlidir. RAS yönünden klinik kuşku taşıyan hasta dağılımında RAS varlığı açısından yüksek doğrulukta araştırma yapmaya olanak veren, non-invaziv, güvenli ve kolay uygulanabilir yöntemler tercih edilmelidir. Gereç ve Yöntem: Ocak 2007 ile Aralık 2011 tarihleri arasında RAS ile uyumlu ya da RAS açısından kuşkulu klinik, fizik muayene ve laboratuar bulguları nedeniyle 4 ayrı merkezde yapılan MRA'da RAS saptanan ve sonrasında kliniğimizde DSA yapılan ve verilerine ulaşılabilen 17-83 yaşları arasında (Ortalama yaş 47,97), 30'u (%42,9) erkek, 40'ı (%57,1) kadın toplam 70 hasta çalışmaya dahil edildi.70 hastada toplam 149 ana renal artere ait MRA ve DSA bulguları retrospektif olarak değerlendirildi. Bulgular: MRA'da 149 renal arterin 89'unda RAS saptanırken DSA'da gerçekte 49 tanesinde RAS olduğu tespit edilmiştir. MRA'nın RAS'ı saptamadaki duyarlılığı %87.8 seçiciliği %54'tür. Duyarlılık literatürle benzer olmakla birlikte seçicilik daha düşük bulunmuştur. Bunun nedeni MRA'nın teknik sınırlamaları ve artefaktlarına bağlıdır. Çalışmada 70 hastada (139 renal ünite) DSA'da 78'i sağ 71'i sol olmak üzere toplam 149 ana renal arter saptanırken, MRA'da 72'si sağ, 68'i sol olmak üzere toplam 140 ana renal arter izlenmiştir. Yine MRA'da toplam 1 hastada 1 adet aksesuar renal arter saptanabilirken DSA'da 12 hastada 17 adet aksesuar renal arter saptanmıştır. Aksesuar arterlerin ve aksesuar arterler kadar ince kalibrasyondaki renal arterlerin saptanması ve bu arterlerdeki stenozların doğru tanınma oranı halen düşüktür. Bunun başlıca sebebi ince kalibredeki arterlerde görüntü rezolüsyonunun sınırlayıcı faktör olmasıdır. Tartışma: Nefes tutmalı 3 boyutlu kontrastlı renal MRA, özellikle otomatik enjektör kullanımı ile bolus zamanlaması yapılarak elde olunduğunda, tekniğin sınırlılıkları ve artefaktlarının bilinip bunların ışığında değerlendirme yapıldığında ve bu sınırlılıklar ile artefaktları minimuma indirecek önlem ya da teknikler kullanıldığında yüksek doğrulukta renal arter stenozlarını belirleyebilen gereksiz radyasyon alımına sebep olan invaziv anjiografik görüntülemelerin önüne geçen noninvaziv bir yöntemdir. Özellikle sensitivitesinin oldukça yüksek oranlarda olması bu tekniğin RAS taramasında güvenle kullanılabileceğini göstermektedir.

Anahtar Kelimeler

Hipertansiyon; Renal Arter Stenozu; Manyetik Resonans Anjiografi; Dijital Çıkarımlı Anjiografi

Abstract

Aim: Renal artery stenosis (RAS) is a cause of 1-5% of all cases of hypertension. The early diagnosis and treatment of renovascular disease is important in terms of the protection of renal function. Noninvasive, safe, simple and accurate imaging methods should be preferred in the diagnosis of RAS. Material and Method: Seventy patients aged between 17-83 years (average age 47.97 years), including 30 males (42.9%) and 40 females (57.1%) that were diagnosed with RAS by Magnetic Resonance Angiography (MRA) were included in the study. The MRA examinations were performed in 4 different centers between January 2007 and December 2011. Physical examination and laboratory findings of all patients were consistent with RAS. Following the MRA evaluation, the Digital Subtraction Angiography (DSA) examinations of all cases were performed in our clinic. A total of 149 main renal artery MRA and DSA findings from 70 patients were evaluated retrospectively. Results: While 89 out of 149 renal arteries were diagnosed with RAS by using MRA, 49 of them were diagnosed by using DSA. In the diagnosis of RAS the sensitivity and selectivity of MRA were 87.8% and 54%, respectively. Comparison with the literature showed that while sensitivity of MRA was similar to the literature, although the selectivity was lower, which might be due to the technical restrictions and artifacts of MRA. In this study we examined 149 main renal arteries in 70 patients by using DSA. Seventy-eight of were right and seventy-one were left renal arteries. Meanwhile, the evaluation with MRA revealed a total of 140 main renal arteries. Seventy-two of these were right, while sixty-eight were left renal arteries. The MRA showed 1 accessory renal artery in 1 patient, whereas DSA showed 17 accessory renal arteries. The detection and correct evaluation of the degree of stenosis of accessory arteries and finely calibrated renal arteries that are similar to accessory arteries is still low. The main reason for this is the relatively low image resolution as a restrictive factor in thinner arteries. Discussion: Breath-hold three-dimensional (3D) contrast enhanced renal MRA is a noninvasive method preventing invasive angiographic examinations that cause unnecessary radiation exposure. MRA can also determine renal artery stenosis with high accuracy, especially with the use of an automatic injector and bolus timing. However, one should be aware of the limitations and artifacts of the technique and precautions should be used to minimize these artifacts. In conclusion, MRA can be used in the screening of RAS confidently because the sensitivity of this method is considerably high.

Keywords

Hypertension; Renal Artery Stenosis; Magnetic Resonance Angiography; Digital Subtraction Angiography

DOI: 10.4328/JCAM.3527 Received: 17.04.2015 Accepted: 04.05.2015 Printed: 01.12.2015 J Clin Anal Med 2015;6(suppl 6): 737-42
Corresponding Author: Aykut Recep Aktas, Department of Radiology, Medical Faculty, Suleyman Demirel University, Isparta, Turkey.
GSM: +905324747281 T.: +90 2462112050 F.: +90 2462112050 E-Mail: aykutraktas@gmail.com

Introduction

Hypertension is a major public health problem affecting approximately one fifth of the world population [1]. Renal artery stenosis (RAS) is a cause of hypertension in 1-5% of patients [2-5]. Renovascular hypertension (RVH) has been reported to affect 15-30% of cases whose clinical data support renovascular disease [6, 7]. Early diagnosis and treatment of renovascular disease is important for the preservation of renal function. Non-invasive, safe and easily applicable methods that allow detection of RAS with high accuracy should be preferred in patients whose clinical findings are suggestive of this disease entity [1].

In our study, we evaluated the three-dimensional contrast-enhanced magnetic resonance angiography (MRA) and digital subtraction angiography (DSA) images of patients whose clinical findings suggested RVH. The images were taken in our clinic as well as in other clinics. We aimed to investigate the comparative diagnostic value of these methods and to determine which method is superior.

Material and Method

Seventy patients, including thirty (42.9%) males and forty (57.1%) females with a mean age of 47.9 years (17-83 years) and whose RAS were detected using MRA and DSA were included in the study (Figure). A total of 149 main renal artery

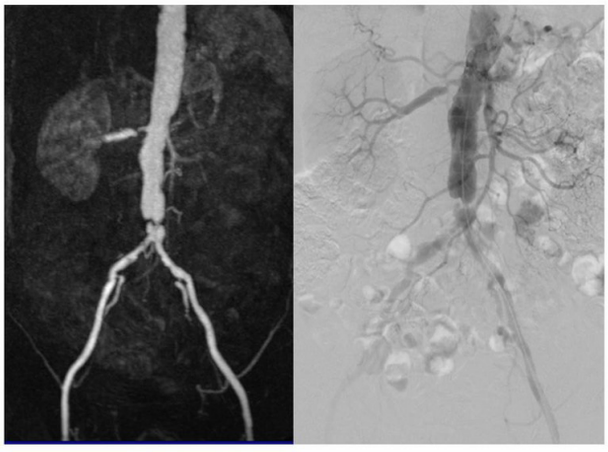

Figure. MRA and DSA images of right renal artery stenosis.

MRA and DSA findings were retrospectively evaluated in the 70 patients. The DSA imaging was performed by using a TOSHIBA Infinix (Toshiba Inc., Tokyo, Japan) angiography device. First, abdominal angiography was performed using the Seldinger method and entering through the femoral or axillary artery and then the renal arteries were selectively catheterized and displayed. Prior to the procedure, the patients' blood pressure was measured and it was investigated whether the patients had bleeding diathesis. Patients were informed about the procedure and their informed consents were obtained. Angiograms were evaluated by a radiologist specialized in this field. The patients' renal parenchymal staining, number of main renal arteries, number of accessory renal arteries, presence of stenosis, location of stenosis, degree of stenosis, etiology of stenosis, and presence of lesions in other vessels within the image range were investigated. In cases of necessity (stenosis of 50% or above), endovascular therapy was done in patients with RAS in the same or at a later session. The MRA imaging was carried out in four different centers. The 1.5 T imaging device (Magnetom Avanto, Siemens, Erlangen , Germany) body total imaging matrix (TIM) coil was used for MRA imaging in our center (Center 1). The breath-hold contrast-enhanced 3D-FSGR (fast spoiled gradient-recalled) sequence MRA imaging was performed by using a 1.5 T device (Intera, Philips, Netherlands) with Q body matrix coil in Center 2, Magnetom Maestro (Siemens, Erlangen, Germany) in Center 3, and in Center 4. In our center the injection of contrast material was performed by using an MR compatible automatic injector (Ulrich, Ulm, Germany), while in other centers the injections were performed manually. The maximum intensity projection (MIP) and 3D images were reconstructed from raw images.

Image Analyses

Three radiologists experienced in the area reported the MRA finding in Center 1. The MRA findings were evaluated based on the raw images and MIP and 3D images reconstructed from those raw images and the results were recorded.

First, we evaluated anatomical localization, size, number and parenchymal signal intensity of the bilateral kidneys. Then, the main renal artery was evaluated in terms of the origin, number, the presence of stenosis, the localization of the stenosis (proximal, middle, distal and long segments), the etiology of stenosis (atherosclerosis, fibromuscular dysplasia (FMD)) and the degree of stenosis. Finally, the presence of accessory renal arteries, and if present the number and presence of stenosis in the accessory renal arteries were determined.

Statistical Analyses

The data was analyzed using SPSS 20. Descriptive statistics such as frequency distribution, mean, standard deviation, and median were used to define the sampling. The distribution of MRA and DSA methods according to the number, presence of stenosis, stenosis segments and the degree of stenosis in the renal arteries was determined separately. In addition, sensitivity and specificity of MRA and DSA methods in terms of RAS were investigated.

Results

1. Comparison of MRA and DSA regarding detection of renal artery numbers and variations

The evaluation of 70 patients with DSA revealed 149 main renal arteries including 78 right and 71 left, while evaluation with MRA showed 140 main renal arteries 72 of which were right and 68 were left.

In 10 patients whose MRA imaging was done in our clinic (Center 1) both the MRA and DSA imaging showed a total of 23 renal arteries: 13 on the right and 10 on the left. The right renal artery in one patient and the left renal artery in another were observed in both tests. The patient whose right renal artery was not seen had a history of right nephrectomy, while the patient whose left renal artery was not seen had a history of severe hypoplasia of the left kidney. In one patient, the MRA detected three right renal arteries, while the DSA detected four.

Furthermore, the MRA did not detect any left renal arteries in two patients; however, the DSA detected two left renal arteries in one of those patients and one renal artery in another patient. The MRA did not detect any right renal arteries in one patient, while the DSA detected one renal artery in the same patient. Moreover, in 3 patients the MRA detected one right renal artery; meanwhile the DSA detected two right renal arteries in those patients. In another patient, 1 right main renal artery was seen by MRA, while 3 right main renal arteries were observed by using DSA. The MRA detected double main renal artery in one patient, but the DSA detected only one main renal artery in the same patient. Double right renal artery in one patient and double left renal artery in another patient was observed using both methods. Both methods showed left kidney hypoplasia in 2 out of 70 patients, right kidney hypoplasia in 4 patients and nephrectomy of the right kidney in 1 patient. Furthermore, both methods showed that in one patient the left kidney had a left iliac fossa and pelvic localization and that the left main renal artery emerged from the left internal iliac artery.

Early branching variation in the right main renal artery was observed in one patient in both methods. The MRA detected 1 accessory renal artery in 1 patient, while the DSA detected a total of 17 accessory renal arteries in 12 patients, 1 accessory renal artery in 8 patients, 2 in 3 patients, and 3 in 1 patient. The accessory renal artery detected in MRA was also observed in the DSA.

2. The sensitivity and selectivity of MRA in diagnosis of RAS

We compared the MRA with DSA in terms of the number of renal arteries in order to determine the sensitivity and specificity of MRA in the detection of RAS. While the MRA detected RAS in 89 of the 149 renal arteries, the DSA detected 49 RAS. These 43 RAS detected in both MRA and DSA were considered true positives. On the other hand, 46 out of 89 RAS detected by MRA were found to be normal renal arteries in DSA (false positive). Moreover, neither of the tests detected RAS in 54 of 149 renal arteries (true negatives), while 6 out of 49 RAS detected by DSA were evaluated as normal renal arteries in MRA (false negative) (Table 1).

Table 1. Comparison of the renal arteries with RAS in MRA and DSA

			DSA		Sum
			RAS (-)	RAS (+)	
MRA	RAS (-)	Number	54	6	60
		%	54.0%	12.2%	40.3%
	RAS (+)	Number	46	43	89
		%	46.0%	87.8%	59.7%
Sum		Number	100	49	149
		%	100.0%	100.0%	100.0%

MRA: Magnetic Resonans Angiography, DSA: Digital Substraction Angiography, RAS: Renal Artery Stenosis

The MRA identified bilateral RAS in 21 out of 70 patients, while the DSA detected bilateral RAS in 9 patients (true positive), unilateral RAS in 6 patients and normal renal artery in 6 patients (false positive). Moreover, the MRA identified that 47 patients had unilateral RAS, however the DSA confirmed only 16 of those patients (true positive), while 27 patients were shown to have normal renal arteries (false positive) and 4 patients were shown to have bilateral RAS (false negative). Neither of the tests detected RAS in 1 patient (true negative). According to these results, sensitivity, selectivity and accuracy of MRA in the detection of RAS were 87.8%, 54% and 65%, respectively.

In our clinic we used an automatic injector, while other clinics did the injections manually. Therefore, we determined the contribution of the use of an automatic injector on the MRA's diagnostic value by calculating sensitivity, selectivity and accuracy separately and these values were found to be 100%, 90% and 95.6%, respectively.

3. The comparison of MRA and DSA in terms of degree and localization of RAS

The DSA determined varying degrees of main renal artery stenosis in 49 patients. Mild stenosis was detected in 18 renal arteries, moderate in 12, severe in 16, and occlusion was detected in 3 renal arteries. Among 18 renal arteries that were identified to have mild stenosis by DSA, MRA showed mild stenosis in 10, moderate stenosis in 5 and normal renal artery in 3. Among 12 renal arteries that were identified as having moderate stenosis by DSA, MRA showed moderate stenosis in 8, severe stenosis in 2, occlusion in 1, and a normal renal artery in 1. Moreover, out of the 16 renal arteries that were determined to have severe stenosis by DSA, 14 were identified to have severe stenosis by MRA as well, but 2 of them were defined as normal. The MRA detected an occlusion in 3 renal arteries, while DSA determined that 2 of them had severe stenosis while 1 had moderate stenosis. In addition, among the 98 renal arteries that were determined to be normal by DSA, 52 were determined to be normal by MRA as well. However, DSA showed mild stenosis in 32, moderate stenosis in 8, severe stenosis in 3, and occlusion in 3 renal arteries.

The evaluation of stenosis localization in 89 patients who were identified to have RAS by using MRA showed ostial or proximal 1/3 localization in 61 renal arteries, central renal artery localization in 13 renal arteries, only distal 1/3 localization in 11 renal arteries and long segment localization in 4 renal arteries. On the other hand, in 49 patients identified to have RAS by using DSA, the stenosis localization was as follows: ostial or proximal 1/3 localization in 42 renal arteries, central artery localization in 5 renal arteries, distal localization in 1 renal artery and long segment localization in 1 renal artery.

4. Comparison of MRA and DSA in terms of RAS etiology and age

Out of a total of 49 RAS cases, 43 cases (88%) had atherosclerosis and 6 cases (12%) had FMD. The comparison of stenosis locations with the etiology showed atherosclerosis in 42 cases with ostial-proximal 1/3 segment localization and 1 case with long segment localization, and FMD in 6 cases with middle 1/3 and/or distal segment localization (Table 2).

The evaluation of age distribution of 49 renal artery cases with RAS revealed that 9 cases were in the 17-39 years age group, 20 cases were in 40-62 years age group and 20 cases were in 63-85 years age group. Forty-three of them (87.7%) had atherosclerosis, while 6 (12.3%) had FMD in their etiology (Table 3).

Table 2. Ethiology of RAS according to the localization of the pathology.

Stenosis Localization	Stenosis		Sum
	Atherosclerosis	FMD	
Proksimal	42	0	42
Middle	0	5	5
Distal	0	1	1
Long segment	1	0	1
Sum	43	6	49

FMD: Fibromuscular Dysplasia

Table 3. The distribution of RAS according to age groups

		Age groups			Sum
		17-39	40-62	63-85	
DSA	RAS (-)	41	32	18	91
	RAS (+)	9	20	20	49
Sum	50	52	38	140	

DSA: Digital Substraction Angiography, RAS: Renal Artery Stenosis

5. The Percutaneous Transluminal Angioplasty (PTA) Rates in RAS

The Percutaneous Transluminal Angioplasty (PTA) procedure was performed in 22 (28%) of the 49 RAS detected patients. PTA was recommended in another 4 patients (8.1%), but the procedure could not be carried out in our clinic for patient-related reasons. Balloon angioplasty alone was applied to 7 patients (32%) that underwent PTA, while the combination of balloon angioplasty and stenting was applied to 15 patients (68%). The PTA procedure did not result in any complications in any of the patients. Additionally, all patients were discharged after 24 hours of observation. Bilateral balloon+stent angioplasty was applied to 3 patients who underwent PTA and unilateral balloon+stent angioplasty was applied to 13 patients. Stent restenosis was observed during the follow-up of one of the patients who underwent PTA and therefore an in-stent balloon angioplasty procedure was applied during the second PTA and in-stent lumen patency was achieved again.

Discussion

Renal artery stenosis (RAS) is a pathology that may cause hypertension, renal ischemia, and end-stage renal failure. The threshold value of RAS that results in hypertension or ischemic injury is not known and varies from patient to patient [8,9,10]. Narrowing of 50-60% of the luminal diameter is considered significant in terms of hemodynamics (10). The most common cause of RAS is atherosclerosis followed by FMD. Early detection of RAS is important in order to prevent permanent damage. Currently, interventional radiological methods are used for treatment of RAS [11]. Although DSA is a gold standard in the diagnosis of RAS, this method is invasive, includes radiation and requires the use of nephrotoxic iodinated contrast agents and thus cannot be used as a screening method. Many tests have been used in the detection of RAS in the past. Among these methods are Doppler ultrasonography and Captopril scintigraphy that investigate functional effects, while techniques such as BTA and 3D-MRA provide morphological information [12]. In recent years, there have been some studies suggesting that MRA could provide functional information [11, 13].

MRA is a noninvasive technique used to display many arterial systems in the body. The conventional MRA methods such as time-of-flight (TOF) and phase contrast (PC) have been previously used to display renal arteries trending towards RAS. Gedroye et al. have reported that the 3D-PC reconstruction method's sensitivity was 84% and specificity was 91% [14]. Although PC MRA provides high quality images, it has several disadvantages such as long procedure time, limitation in the volume that will be examined and difficulty in showing accessory arteries [15, 16]. Servois et al. have reported the 2D-TOF method's sensitivity and selectivity as 70-85% and 78-86%, respectively [17]. The combination of both techniques increases the sensitivity and selectivity values to 87% and 97% [18]. The disadvantage of the TOF technique is signal loss resulting from the movement of protons in different directions in the arteries when the normal laminar blood flow profile is perturbed. This signal loss is evident in low caliber distal portions of vessels and twisted portions of the renal arteries or in the turbulent flow that develops secondary to stenosis [19]. In order to eliminate this problem Prince et al. have suggested using high doses of gadolinium to increase the signal intensity of blood in the displayed volume and reported seeing increased signal in the aorta and its branches in the 3D-TOF sequence [20]. The studies that have used this method have reported seeing increases in sensitivity and specificity (94% and 98%, respectively) [21]. The most important technical feature of this technique was using intravenously injected paramagnetic agents that decreases the blood's T1 relaxation time and thus creates significant contrast difference between the blood and the surrounding tissues. Another important feature of the technique is that it provides images in a very short time (expressed in seconds) during the time when the paramagnetic agent passes through the desired vascular system for the first time [22].

There are many studies in the literature that have used various techniques and some studies have reported contrast-enhanced 3D-MRA's sensitivity and specificity as 88-100% and 90-94%, respectively (11, 23). Thanks to these high rates, the contrast-enhanced 3D-MRA has become a routinely used effective non-invasive screening method to determine proximally located atherosclerotic lesions that are the most common cause of RAS. In our study, the sensitivity of MRA was detected as 87.8%, which was consistent with the values presented in the literature. However, the selectivity, which is the ability to distinguish non-RAS cases, was determined to be 54%, which is lower than values reported in the literature. Various factors might have resulted in a low selectivity. First, the difficulty in the evaluation of stenosis and failure to provide adequate saturation due to spatial pre-saturation in the lumen of finely calibrated veins and a decrease in gadolinium T1's shortening effect may explain these results. Second, improper stenosis diagnosis due to inability to achieve adequate arterial contrast as a result of timing error or due to venous contamination is another possibility. Third, an incorrect stenosis diagnosis due to loss of signal associated with de-phasing artifact in twisted veins or in normal veins with impaired laminar flow could be another reason for the results. Another reason includes the MRA's technical limitations and artifacts such as movement artifacts due to patients' inability to hold their breath. In addition, the inhomogeneity of the properties of devices used for MRA imaging in different centers as

well as the different parameters used in the imaging procedure were important contributors to low selectivity. It is important to know MRA's technical limitations and artifacts for a proper diagnostic approach, to take measures to address these artifacts and limitations in patients with RAS, to take more careful assessment, and if needed to evaluate the patient with other noninvasive techniques such as Color Doppler Ultrasound.

Recent developments in rapid gradient echo imaging and echo-planar technology lead to significant shortening in the examination time and routinely used surface coils have improved the signal/noise ratio and thus increased image quality. This has allowed for the visualization of even very fine caliber accessory arteries [24]. In studies that used MRA to detect RAS, the rate of accessory renal artery detection was between 10-42%. A study by Thornton et al. reported detecting 19 accessory renal arteries in 60 patients [19]. Cobelli et al. have identified a total of 13 accessory renal arteries in 45 patients [25]. In our study, the MRA detected 1 accessory renal artery in 1 patient, while the DSA detected a total 17 accessory renal arteries in 12 patients: this included 1 in 8 patients, 2 in 3 patients, and 3 in 1 patient. The accessory renal artery detected in MRA was also observed in DSA. In conclusion, the rate of detection of accessory renal arteries with MRA was 6% in this study, which is below the rate reported in the literature. However, the detection of accessory arteries and thin renal arteries as accessory arteries and the rate of accurate detection of stenosis in renal arteries were still low. The main reason for this is that image resolution is a limiting factor in small caliber arteries. The decrease in spatial pre-saturation and the shortening effect of gadolinium T1 in the lumen of the small caliber arteries prevents adequate saturation thus making it difficult to evaluate stenosis [24]. For the same reason in our study, 9 out of 149 renal arteries observed by DSA were not detected by MRA. In addition, 6 renal arteries (5 left and 1 right renal arteries) that were visualized as normal by MRA were determined to have RAS of various degrees located in the proximal segment by DSA (false negative).

Stenosis in intrarenal and segmental branches is extremely rare and often seen in young non-azotemic hypertensive patients or in patients with FMD. In our study, the DSA detected segmental stenosis in one patient, however it was not observed in MRA. Difficulties in the diagnosis of such stenosis have been described before. Therefore, although MRA seems to be normal in younger patients or in patients with possible distal or segmental renal artery involvement such as FMD, if there is a clinical suspicion for RAS it is recommended that the patient undergoes DAS [24].

The most common artifacts beside the technical limitations described above often occur due to timing errors. Capturing the intravenously injected contrast agent in the desired vascular system in the arterial phase is essential for a quality image. While early arterial injection cannot achieve adequate signal, late injections lead to contrast of systems related to venous return that superposition with arteries thus making it difficult to evaluate the results. This problem can be overcome by using automatic injector systems with automatic triggering programs that enable contrast agent injections and ensures capturing of the contrast agent in the arterial phase of the desired vascular system. In our study, although the automatic triggering software was used in all centers, the automatic injection system was used only in our clinic (Center 1), while in other centers the contrast material injection was done manually. Performing contrast agent injections manually instead of with automatic injections resulted in timing errors and venous superposition due to enhancement of venous structures, especially the left renal vein in younger patients with rapid circulations. This was likely the reason why MRA detected RAS in 46 of the 149 renal arteries, while DAS showed that those 46 renal arteries were normal (false positive). In our clinic (Center 1) MRA was performed by using an automatic injector and showed 1 stenosis in a total of 23 renal arteries, but this was not confirmed by DSA (false positive). The MRA's sensitivity, specificity and accuracy in detecting RAS were determined to be 100%, 90% and 95.6%, respectively. The important point here is that if the venous return had occurred the evaluation should be done not only based on MIP and 3D images but these findings should also be correlated with raw images, and the possibility of arteriovenous malformation should be especially considered in patients with unilateral venous return [22, 26].

Respiratory artifacts might have been among another limitation for 46 false positives detected in our study. Double-contour appearance and the loss of sharpness in the orifice level in particular associated with an inability to provide optimal breath-hold lead to a false stenosis appearance [26]. In our study, a total of 46 false positives were detected: 19 in the proximal segment, 8 in the middle segment, and 10 in the distal segment. These false stenosis appearances were due to respiratory artifacts, timing errors and de-phasing artifacts associated with turbulent flow at the orifice level especially in cases with stenosis observed in the proximal segment. In order to bring breathing artifacts within the limits so that they won't disrupt the diagnostic quality before the examination, patients should be evaluated for the presence of obstructive or restrictive lung pathologies. Moreover, patients should be evaluated in terms of how long they can hold their breaths and if that period is short the sequence parameters should be adjusted to shorten the examination time. In addition, in patients who are without pulmonary diseases, it would also be useful to give breath-hold training prior to the procedure [27, 28].

Another observation in our study was the exaggerated loss of signal that occurred at the level of stenosis that blocked the accurate determination of the degree of stenosis. Although contrast-enhanced examination largely prevents signal loss, some amount of de-phasing, i.e. signal loss, occurs in severe stenosis or in regions with turbulent flow such as orifice level [26-29]. Indeed, in our study MRA showed moderate stenosis in 5, severe stenosis in 2 and occlusion in 1 renal artery, while the DSA determined those 5 moderate stenoses as mild, 2 severe stenoses as moderate and 1 occlusion as moderate stenosis and we believe that the reason for this was that the signal loss exaggerated the degree of stenosis. Therefore, one must be aware of de-phasing artifact in signal losses observed as localized narrowing of the lumen, especially in orifice levels [11, 30].

In many studies in the literature, it has been reported that atherosclerosis involves the proximal branches of the renal arteries, while FMD occurs in the middle, distal, and intrarenal branches of renal arteries. In our study, atherosclerosis was

present in 43 out of 49 (87.7%) detected RAS and in 42 (97%) of those the involvement was observed in the proximal 1/3 and 1 (3%) was observed in the long-segment of the renal artery. Moreover, there were 6 patients with FMD (12.3%) and in 5 (83%) of them the involvement was in the middle and distal 1/3, and 1 case (17%) was only in the distal 1/3. The distribution of our cases according to the etiology of stenosis localization was consistent with other studies in the literature.

In our study, RAS was detected in 36 out of 70 patients (51.4%) by using DSA, which is the gold standard in detection of RAS. Twenty-two (61.1%) of those patients were males and fourteen (38.9%) were females. The RAS was detected in 49 renal arteries and 40 of those (81.6%) were detected in patients between 40-85 years of age, while 9 of them (18.4%) were detected in patients between 17- 39 years of age. These findings are in line with the literature. In addition, the evaluation of etiology-gender distribution showed that among 49 patients with RAS, FMD was detected in 6 patients: 5 males and 1 female. Additionally, atherosclerosis was detected in 43 patients: 17 males and 13 females. The results of atherosclerosis-gender distribution showed similarity with the literature, but the results of the FMD distribution, which is usually more common in the female population, did not match the literature.

Conclusion

MRA is highly sensitive in the diagnosis of RAS, limits the use of contrast agents, is less invasive than DSA and can safely be used in the diagnosis and screening of hypertension.

Competing interests

The authors declare that they have no competing interests.

References

1. Keleş İ, Ağaç MT. İkincil hipertansiyon. Klinik Gelişim 2005;18(2):42–8.
2. Conkbayır I, Yücesoy C, Edguer T, Yanık B, Yaşar Ayaz U, Hekimoğlu B. Doppler sonography in renal artery stenosis: an evaluation of intrarenal and extrarenal imaging parameters. Clin Imaging 2003;27:256–60.
3. Granata A, Fiorini F, Andrulli S. Doppler ultrasound and renal artery stenosis: an overview. Journal of Ultrasound 2009;12:133–43.
4. Vasbinder GB, Nielmans PJ, Kessels AG. Diagnostic tests for renal artery stenosis in patients suspected of having renovascular hypertension: a meta analysis. Ann Intern Med 2001;135:401–11.
5. Williams GJ, Macaskill P, Chan SF. Comparative accuracy of renal duplex sonographic parameters in the diagnosis of renal artery stenosis: paired and unpaired analysis. Am J Roentgenol 2007;188:798–811.
6. Chain S, Luciardi H, Feldman G, Berman S, Herrera RN, Ochoa J, et al. Diagnostic role of new Doppler index assessment of renal artery stenosis. Cardiovascular Ultrasound 2006;25(4):4.
7. Soulez G, Oliva VL, Turpin S, Lambert R, Nicolet V, Therasse E. Imaging of renovascular hypertension: respective values of renal scintigraphy, renal Doppler US, and MR angiography. Radio Graphics 2000;20:1355–68.
8. Tonbul Z, Güney I. Renovasküler hipertansiyon. J Int Med Sci 2007;3(4):1–10.
9. Walsh PC, Novick AC. Campbell Üroloji. 8. baskı. İstanbul Güneş 2005.p.229–61.
10. Zwiebel WJ. Ultrasound Assesment of the Splanchnıc Arteries. Zvviebel, WJ. Introduction to vascular Ultrasonography, 4ed, Philadelphia: WB Saunders Company 2000.p.421-31.
11. Schneider G, Prince MR, Meaney JFM, Ho VB. Magnetic Resonance Angiography. 1st edition. NewYork: Springer-Verlag 2005.p.209-36.
12. Bongers V, Bakker J, Beutler JJ, Beek FJA, De Klerk JMH. Assessment of Renal Artery Stenosis: Comparison of Captopril Renography and Gadolinium-Enhanced Breath-Hold MR Angiography. Clinical Radiology 2000;55:346-52.
13. Michaely HJ, Sourbron S, Dietrich O, Attenberger U, Reiser MF, Schoenberg SO. Functional renal MR imaging: an overview. Abdom Imaging 2007;32:758-71.
14. Gedroye P, Neerhut R, Negus R. MRA of renal artery stenosis. Clin Radiol 1995;50:436-9.
15. De Cobelli F, Vanzulli A, Sirono S. Renal artery stenosis. Evaluation with breath-hold three-dimensional dynamic gadolinium enhanced versus three-dimensional phase-contrast MRA. Radiology 1997;205:689-95.
16. 78. Hany TF, Debatin JF, Leung D, Pfammatter T. Evaluation of the aortoiliac and renal arteries: Comparison of breath-hold contrast-enhanced 3D MRA with conventional catheter angiography. Radiology 1997;204:357-62.
17. Servois V, Laissy JP, Ferger C. Two dimensional TOF MRA of renal arteries without maximum intensity projection: A prospective comparison with angiography in 21 patients screened for renovascular hypertension. Cardiovasc Intervent Radiol 1994;17:138-42.
18. Zhang H, Maki JH, Prince MR. 3D contrast- enhanced MR angiography. J Magn Reson Imaging 2007;25:13-25.
19. Thornton J, O'Callaghan J, Walshe J, O'Brien E, Varghese JC, Lee MJ. Comparison of digital subtraction angiography with gadolinium-enhanced magnetic resonance angiography in the diagnosis of renal artery stenosis. Europen Radiology 1999;9(5):930-4.
20. Prince MR. gadolinium-enhanced MR aortography. Radiology 1994;191:155-64.
21. Prince MR, Narasimham DL, Stanley JC. Gadolinium enhanced MRA of abdominal aortic aneurysms. J Vasc Surg 1995;14:656-69.
22. Prince MR. 3D Contrast enhanced MR Angiography. 2 nd edition. Germany: Springer 1999;3(41):89-107.
23. Qanadli SD, Soulez G, Therasse E, Nicolet V, Turpin S, Froment D, Courteau M, Guertin MC, Oliva VL. Detection of Renal Artery Stenosis: Prospective Comparison of Captopril-Enhanced Doppler Sonography, Captopril-Enhanced Scintigraphy and MR Angiography. AJR 2001;177:1123–9.
24. Rieumont MJ, Kaufmann JA, Geller SC. Evaluation of renal artery stenosis with-dynamic gadolinium enhanced MRA. AJR 1997;169:39-44.
25. De Cobelli F, Venturini M, Vanzulli A, Sironi S, Saivioni M, Angeli E, Scifo P, Garancini M P, Quartagno R, Bianchi G, Del Maschio A.Renal Arterial Stenosis: Prospective Comparison of Color Dopler US and Breath-hold, Three-dimensional, Dynamic, Gadolinium-enhanced MR Angiography. Radiology 2000;214(2):373-80.
26. Lee VS, Martin DJ, Krinsky GA, Rofsky NM. Gadolinium enhanced MRA: Artifacts and Pitfalls. AJR 2000;175:197-205.
27. Kızılkılıç O. Kontraslı Manyetik Rezonans Anjiografi Teknikleri. Türkiye Klinikleri J Radiol-Spesial Topics 2009;2(1):15-23.
28. Bulakbaşı N, Sanal HT. MRA Artefakt ve Sınırlamaları. Türkiye Klinikleri J Radiol-Spesial Topics 2009;2(1):24-36.
29. Thornton MJ, Thornton F, O'Callaghan J. Evaluation of dynamic gadolinium enhanced breath-hold MRA in the diagnosis of renal artery stenosis. AJR 1999;173:1279-83.
30. Law YM, Tay KH, Gan YU, Cheah FK, Tan BS. Gadolinium enhanced magnetic resonance angiography in renal artery stenosis: Comparison with digital subtraction angiography. Hong Kong Med J 2008;14:136-41.

How to cite this article:
Çetin M, Aktaş AR, Özgür Ö, Karaali K, Alimoğlu E, Alparslan A, Sindel T. Comparison of Catether Angiography with Magnetic Resonance Angiography in the Diagnosis of Renal Artery Stenosis. J Clin Anal Med 2015;6(suppl 6): 737-42.