Distal Metatarsal Osteotomy in Hallux Valgus Surgery: Chevron Osteotomy

Halluks Valgus Cerrahisinde Distal Metatarsal Osteotomi: Chevron Osteotomisi

Chevron Osteotomisi / Chevron Osteotomy

Fatih Doğar[1], Fırat Ozan[1], Kaan Gürbüz[1], Yakup Ekinci[2], Ökkeş Bilal[3], Eyyüp Sabri Öncel[1]
[1]Department of Orthopedics and Traumatology, Kayseri Training and Research Hospital, Kayseri,
[2]Department of Orthopedics and Traumatology, Develi Hatice Muammer Kocatürk State Hospital, Kayseri,
[3]Department of Orthopedics and Traumatology, Kahramanmaraş Sütçü İmam University Medical Faculty, Kahramanmaraş, Turkey

Özet

Aim: Halluks valgus, birinci parmağın laterale deviasyonu ile birinci metatarsın medial deviasyonu sonucu oluşan kompleks bir ayak deformitesidir. Bu çalışmada orta derece deformiteli, semptomatik halluks valguslu hastalara uyguladığımız chevron tipi distal metatarsal osteotomi ameliyatının radyografik ve fonksiyonel sonuçları değerlendirildi. Halluks valgus tanısı ile 22 hastanın (12 kadın, 10 erkek; ort. yaş 45±16.7;dağılım 22-69) 27 ayağına (13 sol, 14 sağ ayak) chevron osteotomisi ile cerrahi tedavi uygulandı. Ortalama takip süresi 15.4 ± 4.71 ay (dağılım, 10–24). Gereç ve Yöntem: Ameliyat sonrası ortalama AOFAS akoru 39.1 ± 8.55 (dağılım, 32–57) den 87.8 ± 4.7 (dağılım, 82–97) yükseldi (p < 0.0001). Ameliyat öncesi halluks valgus açısı (HVA) 37.4 ± 5.8 (dağılım, 29 –50) iken ameliyat sonrası 14.8 ± 3.1 (dağılım, 10 –20) (p < 0.0001) ve ameliyat öncesi ortalama intermetatarsal açı (IMA) 13.1 ± 1.5 (dağılım, 11 –17) iken ameliyat sonrası 7.1 ± 1.4 (dağılım, 5 –9) olarak tespit edildi (p < 0.0001). Ortalama sasemoid pozisiyonu ameliyat öncesi 2.9 ± 0.2 (dağılım, 2-3) iken ameliyat sonrası 1.2 ± 0.4 (dağılım, 1-2) olarak tespit edildi (p < 0.0001). Komplikasyon olarak bir hastada başparmakta hipoestezi gelişti. Takip sonunda, hastaların ameliyat sonucundan memnun kalma düzeyleri 16 ayakta (%59.2) çok iyi, 11 ayakta (%40.8) iyi olarak bulundu.Bulgular: Çalışma sonucunda chevron osteotomisi ile iyi radyolojik sonuç, ameliyat sonrası yüksek hasta memnuniyeti ve minimal komplikasyon elde ettik. Chevron osteotomi yöntemi, orta dereceli halluks valgus deformitesinin tedavisinde etkin bir yöntemdir.

Anahtar Kelimeler

Halluks Valgus; Chevron Osteotomisi; Cerrahi

Abstract

Aim: Hallux valgus is a complex foot deformity resulting from medial deviation of first metatarsal and lateral deviation of toe. Radiographic and functional outcomes of chevron type distal metatarsal osteotomy applied to symptomatic hallux valgus patients with moderate deformity were assessed in the present study. Chevron osteotomy was applied to 27 feet (13 left, 14 right) of 22 patients (12 women and 10 men; mean age: 45±16.7 years). Mean follow-up was 15.4± 4.71 months (range, 10–24). Material and Method: The average preoperative AOFAS score of 39.1 ± 8.55 (range, 32–57) improved (p < 0.0001) to 87.8 ± 4.7 (range, 82–97). The average preoperative hallux valgus angle (HVA) of 37.4 ± 5.8 (range, 29–50) improved (p < 0.0001) to 14.8 ± 3.1 (range, 10–20), and the average preoperative intermetatarsal 1-2 angle (IMA) of 13.1 ± 1.5 (range, 11–17) improved (p < 0.0001) to 7.1 ± 1.4 (range, 5–9). The average sesamoid position improved from 2.9 ± 0.2 (range, 2-3) preoperatively to 1.2 ± 0.4 (range, 1-2) (p < 0.0001). Toe hypoesthesia was developed in one patient as a complication. At the end of follow-up, patient satisfaction was found to be excellent in 16 feet (59.2%) and good in 11 feet (40.8%). Results: The results of the study that chevron osteotomy yields good radiological result, high degree of postoperative patient satisfaction with minimal complications. Chevron ostoetomy is most effective method in the treatment of moderate hallux valgus.

Keywords

Hallux Valgus; Chevron Osteotomy; Surgery

DOI: 10.4328/JCAM.3553 Received: 28.04.2015 Accepted: 13.05.2015 Printed: 01.12.2015 J Clin Anal Med 2015;6(suppl 6): 752-5
Corresponding Author: Fırat Ozan, Department of Orthopedics and Traumatology, Kayseri Training and Research Hospital, 38010, Kocasinan, Kayseri, Turkey.
T.: +90 3523368884 F.: +90 3523207313 E-Mail: firatozan9@gmail.com

Introduction

Hallux valgus is a common disorder of the forefoot characterized by lateral deviation of the great toe and medial deviation of first metatarsal [1, 2]. Extrinsic and intrinsic factors are thought to play role in its etiology [1, 2]. Current classification is based on radiographic measurements and classifiy the disease as mild, moderate, and severe [1-3]. Mild hallux valgus deformity is characterized by a hallux valgus angle (HVA) of less than 20 degrees and intermetatarsal 1-2 angle (IMA) of 11 degrees or less. A moderate deformity is characterized by a hallux valgus angle of 20 to 40 degrees and a first intermetatarsal angle of less than 16 degrees, while a severe deformity is characterized by a hallux valgus angle of more than 40 degrees and a first intermetatarsal angle of 16 degrees or more [2, 4].

Many procedures for correcting hallux valgus have been described [3, 5, 6]. Considerations for technical choice include the hallux valgus angle, intermetatarsal angle, arthritis in the first metatarsophalangeal (MTP) joint, hypermobility of the first tarsometatarsal joint, position of sesamoids, musculo-tendinous balance, and congruity of the first metatarsophalangeal joint [1-3]. Surgical techniques are generally classified as soft tissue procedures, metatarsal and phalangeal osteotomies, and combinations thereof [4, 7]. In general, distal metatarsal osteotomies are recommended to achieve sufficient correction of deformity in patients who has hallux valgus angulation up to 30-40° and intermetatarsal angulation up to 15° but no marked arthrosis in first MTP joint [6, 8]. Advantages of Chevron osteotomy include enabling early mobilization by providing a stable osteosynthesis, minimal shortening and ease of technique [9].

Radiographic and functional outcomes of chevron type distal metatarsal osteotomy applied to symptomatic hallux valgus patients with moderate deformity and nor arthritic changes in MTP joint were assessed in the present study.

Material and Method

Chevron osteotomy as surgical treatment was performed to 27 feet (13 left, 14 right feet) of 22 patients (12 women and 10 men; mean age: 45.0±16.7 years; range: 22-69 years) with a diagnosis of moderate symptomatic hallux valgus. There was bilateral involvement in five patients. Minimum follow-up was 10 months (mean: 15.4± 4.71 months, range: 10–24 months) (Table 1). The main operative indication for the surgery was pain and deformity in the forefoot.

In preoperative and postoperative assessment, hallux valgus (HV) and intermetatarsal 1-2 angles (IMA) were measured on weight-bearing anterior and lateral foot radiographs. All radiographs were assessed by one reviewer (OF). All patients underwent clinical assessment using the American Orthopedic Foot and Ankle Society's (AOFAS) hallux-metatarso-phalangeal-interphalangeal scale [10]. It includes pain (40 points), hallux alignment (15 points), and functional assessment (45 points). For subjective evaluation, the patients were asked to rate their postoperative satisfaction level as very good, good, moderate, or poor.

Table 1. Demographic characteristics of patients

Number of patients (feet)	22 (27)
Age, mean ± SD (range)	45 ± 16.7 (22-69)
Gender, n (%)	
Female	12 (54.5%)
Male	10 (45.5%)
Follow-up, months, mean±SD (range)	15.4 ± 4.71 (10-24)
Location, n (%)	
Right	14 (51.9%)
Left	13 (48.1%)

Sesamoid station (position of the tibial sesamoid relative to the axis of the first metatarsal) was graded using a fourpoint ordinal scale [11]: Grade 0, tibial sesamoid completely medial to the mid-axial line of the first metatarsal; Grade 1, less than 50 % overlap of the mid-axial line; Grade 2, more than 50 % overlap; Grade 3, tibial sesamoid completely lateral to the mid-axial line. The study was conducted in accordance with the Declaration of Helsinki.

Surgical technique

All osteotomies were performed by one surgeon (DF). The technique was done through an approximately 5 cm longitudinal medial incision over the first MTP joint. An inverted Y-shaped capsulotomy was performed, the medial eminence was excised, and a 60° V-shaped osteotomy was then made (Figure 1). The thickness of osteotomy blade used was 0.6 mm. The capital fragment was then manually translated laterally and not exceeding 50% of the width of the metatarsal head. Then compressed and stabilized with a two cannulated screw. On indication, a distal soft tissue procedure was performed by a 1-cm longitudinal incision over the dorsal aspect of the first intermetatarsal space to expose the conjoined adductor tendon. The tendon was dissected from the lateral sesamoid and the base of the proximal phalanx. A partial capsulotomy was performed to the lateral aspect of the first metatarsophalangeal joint.

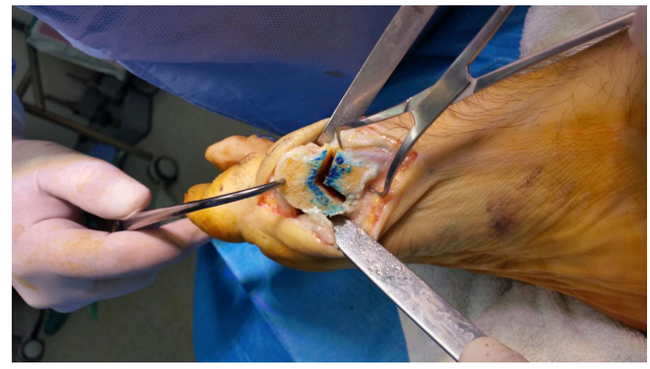

Figure 1. Intraoperative imaging of chevron osteotomy.

In addition to hallux valgus deformity, it was found that there was hammer toe deformity in second finger in two feet and Freiberg disease in second metatarsophalangeal joint in two feet. Proximal phalanx head resection, extensor digitorum brevis tenotomy and lengthening of extensor digitorum longus were performed for hammer toe deformity. Cheilectomy of metatarsal head and synovectomy was performed for Freiberg disease.

After surgery, short leg cast was applied to patients and no weight-bearing was allowed until end of second week. Then, full weight-bearing as tolerated was allowed by removing casts. All statistical analyses were performed using SPSS version 16.0

(SPSS Inc., Chicago, USA) for Windows (Microsoft Corporation, Redmond, USA). Paired Student's t-tests was used to analyze data. P < 0.05 was considered to be statistically significant.

Results

The average preoperative AOFAS score of 39.1 ± 8.55 (range, 32–57) improved to 87.8 ± 4.7 (range, 82–97) (p < 0.0001) (Table 2). The average preoperative HVA of 37.4 ± 5.8 (range, 29 –50) improved to 14.8 ± 3.1 (range, 10 –20) (p < 0.0001), and the average preoperative IMA of 13.1 ± 1.5 (range, 11 –17) improved (p < 0.0001) to 7.1 ± 1.4 (range, 5 –9) (Figure 2). The average sesamoid position improved from 2.9 ± 0.2 (range, 2-3) preoperatively to 1.2 ± 0.4 (range, 1-2) (p < 0.0001).

Table 2. Comparison of preoperative and postoperative radiographic results.

	Pre-operative	Post-operative	p-Value
AOFAS score	39.1 ± 8.55	87.8 ± 4.7	0.0001
HVA	37.4 ± 5.8	14.8 ± 3.1	0.0001
IMA	13.1 ± 1.5	7.1 ± 1.4	0.0001

AOFAS, American Orthopaedic Foot and Ankle Society; HVA, hallux valgus angle; IMA,intermetatarsal angle

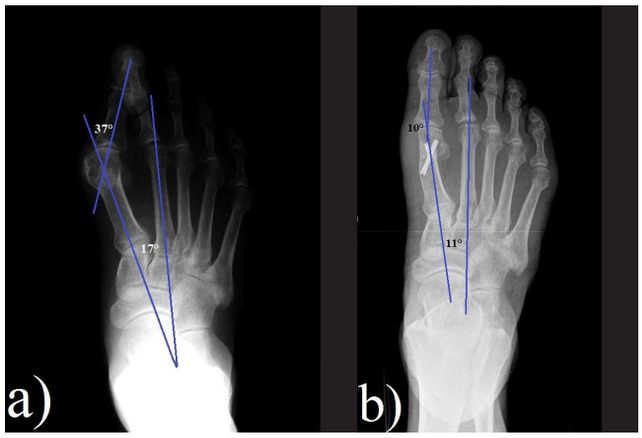

Figure 2. Preoperative and postoperative radiographs of the patient who underwent chevron osteotomy for hallux valgus deformity.

Toe hypoesthesia was developed in one patient as a complication. No patients had postoperative hallux varus deformity, osteotomy nonunion, AVN of the head of first metatarsal, dorsal malunion of the distal metatarsal osteotomy, or recurrence of the deformity after surgery. At the end of follow-up, patient satisfaction was found to be excellent in 16 feet (59.2%) and good in 11 feet (40.8%).

Discussion

Many surgical techniques have been defined for correction of hallux valgus deformity. However, there is no surgical technique that has ability to correct all constituents of deformity [3, 6, 12]. The goal of surgical intervention is provision of normal anatomy as well as normal functions. Thus, one should select most appropriate surgical intervention with lowest complication and recurrence rate by taking foot deformity, severity of deformity and patient factors [1-4, 8]. Hallux valgus deformity is classified as mild, moderate and severe based on HVA and IMA [1-3]. In our patients, mean preoperative IMA value was 13.1° (range, 11-17), whereas mean preoperative HVA was 37.4° (range: 29-50). We think that Chevron osteotomy is sufficient in our patients with moderate deformity. The results of this study that chevron osteotomy yields good radiological result, high degree of postoperative patient satisfaction with minimal complication.

The distal metatarsal osteotomy is a widely accepted method for the correction of mild to moderate hallux valgus [8, 13]. Chevron and Mitchell distal metatarsal osteotomies are frequently used in the treatment of mild to moderate hallux valgus [8, 13]. According to Heerspink et al. [13] the Mitchell ostetomy leads to further shortening of the first metatarsal compared to chevron osteotomy. This might lead to transfer metatarsalgia. Mitchell osteotomy provides better adjustment in the terms of the HV correction radiologically. It is essential for the prevention of postoperative metatarsalgia for a successful HV surgery. Therefore, chevron osteotomy may be preferred instead of Mitchell osteotomy especially in patients with a short first metatarsus [13].

Distal chevron osteotomy is one of the most commonly employed osteotomies [8, 13]. Advantages of this procedure are stability of the osteotomy, rapid healing and minimal shortening. Possible disadvantages are avascular necrosis, insufficient correction or recurrence of hallux valgus [5, 8, 12, 13]. Avascular necrosis of the metatarsal head in chevron osteotomies occurs 0-20% [3]. Excessive capsular dissection may lead to avascular necrosis of part or all of the metatarsal head since, after osteotomy, the only remaining blood supply is from the capsule [5, 8, 12]. We took care to preserve the lateral capsule and saw no signs of avascular necrosis. Only one patient developed postoperative sensory loss over the medial aspect of the great toe. It has been reported that limitations in movements were developed in first MTP joints in cases in which distal osteotomy with soft tissue releasing were performed [3, 12]. No limitation in first MTP joint was detected in our patients at the end of follow-up.

Clinical complaints as well as radiographic measures should be taken into account while making-decision of surgical indication [4]. In all patients, the complaints included pain and difficulty in wearing shoes. However, cosmetic disorder due to deformity was also striking. At the end of follow-up, patient satisfaction was found to be excellent in 16 feet (59.2%) and good in 11 feet (40.8%) when satisfaction was questioned.

For more severe hallux valgus deformities, proximal first metatarsal osteotomies have been performed [7, 9, 14]. In some studies reported that scarf method provide more correction in the amount of IMA and HVA compared to chevron [7, 15]. Given the good outcomes reported, shaft procedures did not result in a better radiographic or clinical outcome than distal corrections in hallux valgus procedures [5, 14, 16]. Deenik et al. found no differences between scarf and chevron osteotomy in correction of HVA and IMA in patients with moderate and severe hallux valgus [5, 14].

Although most authors recommend that the Chevron osteotomy should be used only for patients who are younger than 50 years of age. In our study, there were 8 (31.8%) patients aged 50 years or older. There was increase in mean AOFAS score by 52.5 points after surgery when compared to mean preoperative AOFAS score (p=0.0002). In a long-term follow up study

comparing patients younger and older than 50 years at time of surgery, Schneider et al. [8] found no differences in the clinical and radiographic outcome; thus, they concluded that chevron osteotomy need not be restricted to younger patients.

Several fixation methods are used for stabilization of distal chevron osteotomy including Kirschner wires (K-wire), mini screws, staples and bioabsorbable screws, plates [5-8, 17-20]. Each form has unique advantages and disadvantages [18, 19]. K-wires are relatively easy to insert and require limited exposure for insertion. However, they may loosen and migrate, irritate soft tissue, and provide a portal for infection if they penetrate the skin [17, 19]. To avoid the sequelae associated with metallic fixation, such as painful tissue irritation, loosening of hardware, secondary removal procedure, or pin tract infection, bioabsorbable fixation has been utilized [18]. Using plates in metacarpal and phalangeal fractures provides the most rigid, secure, and reliable fixation of implants currently available. The primary advantage is rigid fixation [21]. Potential disadvantages of using plates are foreign body reaction, allergic reaction, capsule irritation, palpable or visible fixation [19]. We used two cannulated screws for stabilization of osteotomy in our patients. The advantage of chevron osteotomy is direct weight-bearing postoperatively owing to the stable fixation. The patients were allowed for partial weight-bearing within first two months after surgery, followed by full weight-bearing. No loss of fixation, nonunion or malunion deformity was developed.

Hallux valgus is a complex deformity of the foot includes various accompanying pathologies [1, 4]. In addition to hallux valgus deformity, it was found that there was hammer toe deformity in second finger in two feet and Freiberg disease in second metatarsophalangeal joint in two feet. Proximal phalanx head resection, extensor digitorum brevis tenotomy and lengthening of extensor digitorum longus were performed for hammer toe deformity. Cheilectomy of metatarsal head and synovectomy was performed for Freiberg disease.

Secondary transfer metatarsalgia accounts for a significant proportion of failure after HV correction. The reported incidence of transfer metatarsalgia after chevron osteotomy has been 0% to 5% [12, 13]. Potential shortening of the first metatarsal can lead to transfer metatarsalgia of the head of the second metatarsal by the changed pressure distribution of the forefoot [12, 13]. In Chevron osteotomy, metatarsal shortening is generally associated to thickness of osteotomy blade used. The thickness of osteotomy blade used was 0.6 mm in this study. No transfer metatarsalgia was developed in our patients after surgery.

The present study has some limitations, including the lack of a control group for comparison and lower case numbers.

In conclusion, chevron osteotomy provides correction of deformity in patients with moderate hallux valgus deformity in complete and stable manner. It is an appropriate choice in hallux valgus surgery due to its technical ease, satisfactory functional outcomes and good patient satisfaction.

Competing interests

The authors declare that they have no competing interests.

References

1. Coughlin MJ, Jones CP. Hallux valgus: demographics, etiology, and radiographic assessment. Foot Ankle Int 2007;28:759–77.
2. Thordarson D, Rudicel S, Ebramzadeh E, Gill LH. Outcome study of hallux valgus surgery: an AOFAS multi-centre study. Foot Ankle Int 2001;22:956–9.
3. Radwan YA, Mansour AM. Percutaneous distal metatarsal osteotomy versus distal chevron osteotomy for correction of mild-to-moderate hallux valgus deformity. Arch Orthop Trauma Surg 2012;132(11):1539–46.
4. Coughlin MJ. Hallux valgus. J Bone Joint Surg Am 1996;78:932–66.
5. Deenik AR, Pilot P, Brandt SE, van Mameren H, Geesink RG, Draijer WF. Scarf versus chevron osteotomy in hallux valgus: a randomized controlled trial in 96 patients. Foot Ankle Int 2007;28(5):537–41.
6. Giannini S, Cavallo M, Faldini C, Luciani D, Vannini F. The SERI distal metatarsal osteotomy and Scarf osteotomy provide similar correction of hallux valgus. Clin Orthop Relat Res 2013;471(7):2305–11.
7. Adam SP, Choung SC, Gu Y, O'Malley MJ. Outcomes after scarf osteotomy for treatment of adult hallux valgus deformity. Clin Orthop Relat Res 2011;469(3):854–9.
8. Schneider W, Aigner N, Pinggera O, Knahr K. Chevron osteotomy in hallux valgus. Ten-year results of 112 cases. J Bone Joint Surg Br 2004;86(7):1016–20.
9. Trnka HJ, Zembsch A, Easley ME, Salzer M, Ritschl P, Myerson MS. The chevron osteotomy for correction of hallux valgus. Comparison of findings after two and five years of follow-up. J Bone Joint Surg Am 2000; 82(10):1373–8.
10. Kitaoka H, Alexander I, Adelaar R, Nunley JA, Myerson MS, Sanders M. Clinical rating systems for the ankle-hind foot, midfoot, hallux, and lesser toes. Foot Ankle Int 1994;15:349–53.
11. Smith RW, Reynold JC, Steward MJ. Hallux valgus assessment: report of Research committee of the American Orthopaedic Foot and Ankle Society. Foot Ankle Int 1984;5:92–103.
12. Klosok JK, Pring DJ, Jessop JH, Maffulli N. Chevron or Wilson metatarsal osteotomy for hallux valgus. A prospective randomised trial. J Bone Joint Surg Br 1993;75(5):825–9.
13. Heerspink FO, Verburg H, Reininga IH, van Raaij TM. Chevron Versus Mitchell Osteotomy in Hallux Valgus Surgery: A Comparative Study. J Foot Ankle Surg 2014:1067(14):353–6.
14. Deenik A, van Mameren H, de Visser E, de Waal Malefijt M, Draijer F, de Bie R. Equivalent correction in scarf and chevron osteotomy in moderate and severe hallux valgus: a randomized controlled trial. Foot Ankle Int 2008;29(12):1209–15.
15. Fakoor M, Sarafan N, Mohammadhoseini P, Khorami M, Arti H, Mosavi S, Aghaeeaghdam A. Comparison of clinical outcomes of scarf and chevron osteotomies and the mcbride procedure in the treatment of hallux valgus deformity. Arch Bone Jt Surg 2014;2(1):31-6.
16. Faber FW, Mulder PG, Verhaar JA. Role of first ray hypermobility in the outcome of the Hohmann and the Lapidus procedure. A prospective, randomized trial involving one hundred and one feet. J Bone Joint Surg Am 2004;86(3):486–95.
17. Tonbul M, Baca E, Adaş M, Ozbaydar MU, Yurdoglu HC. Crescentic distal metatarsal osteotomy for the treatment of hallux valgus: a prospective, randomized, controlled study of two different fixation methods. Acta Orthop Traumatol Turc 2009;43(6):497–503.
18. Caminear DS, Pavlovich R Jr, Pietrzak WS. Fixation of the chevron osteotomy with an absorbable copolymer pin for treatment of hallux valgus deformity. J Foot Ankle Surg 2005;44(3):203-10.
19. Yearian PR, Brown T, Goldman F. Chevron bunionectomy with microplate and screw fixation: a retrospective follow-up of 26 feet. J Foot Ankle Surg 1996;35:532–6.
20. Kaye JM. New staple fixation for an Austin bunionectomy. J Foot Surg 1992;31:43–6.
21. Jones WW. Biomechanics of small bone fixation. Clin Orthop 1987;214:11-8.

How to cite this article:
Doğar F, Ozan F, Gürbüz K, Ekinci Y, Bilal Ö, Öncel ES. Distal Metatarsal Osteotomy in Hallux Valgus Surgery: Chevron Osteotomy. J Clin Anal Med 2015;6(suppl 6): 752-5.