# Darier's Disease: Two Familial Case Reports

# Darier Hastalığı: Ailesel İki Olgu Sunumu

Darier's Disease / Darier Hastalığı

Emine Colgecen[1], Sevinc Sahin[2], Murat Borlu[3], Selda Seckin[2]
[1]Department of Dermatology, Bozok University Faculty of Medicine, Yozgat,
[2]Department of Pathology, Bozok University Faculty of Medicine, Yozgat,
[3]Department of Dermatology, Erciyes University Faculty of Medicine, Kayseri, Turkey

*Bu olgu sunumu 03-06 Eylül 2015 tarihinde Eskişehir'de düzenlenen IV. DOD Dermatoloji Gündemi'nde poster bildirisi olarak sunulmuştur.*

**Özet**

Darier hastalığı (Darier-White hastalığı, keratozis follikülaris), özellikle seboreik bölgeleri tutan, keratinizasyon bozukluğu ile karakterize, otozomal dominant geçişli, nadir gözlenen bir hastalıktır. Bu makalede, klinik ve histopatolojik bulgular ile Darier's disease tanısı konulan 47 ve 28 yaşlarında ki anne ve kız iki kadın hasta, bu hastalığın nadir görülmesi nedeniyle sunulmuştur.

**Anahtar Kelimeler**

Darier Hastalığı; Keratozis Follikülaris; Keratotik Papüller

**Abstract**

Darier's disease (Darier-White disease, keratosis follicularis) is a rare autosomal dominant disease particularly involving the seborrheic areas and characterized by impaired keratinization. Herein, two cases of this rare disease in a mother and her daughter, aged 47 and 28 years, are reported, together with clinical and histopathological findings.

**Keywords**

Darier's Disease; Keratosis Follicularis; Keratotic Papules

DOI: 10.4328/JCAM.3881 Received: 15.09.2015 Accepted: 19.10.2015 Printed: 01.12.2015 J Clin Anal Med 2015;6(suppl 6): 886-9
Corresponding Author: Emine Colgecen, Department of Dermatology, Bozok University Medical Faculty, 66200, Yozgat, Turkey.
T.: +90 3542127060 F.: +90 3542177150 E-Mail: drecolgecen@hotmail.com

## Introduction

Darier's disease, also known as Darier-White disease or keratosis follicularis, is a rare, autosomal dominant keratinization disorder first reported in 1889 by Darier and White. It is observed equally in both sexes [1-3]. Impairment in desmosomes and the tonofilament-desmosome complex, and compromise of epidermal homeostasis resulting from damage in ATP2A2 gene on the 12q23-24 1 chromosome that codes the calcium pump have been implicated in the pathogenesis of the disease [4]. Darier's disease is an entity that should be considered in the differential diagnosis of dermatoses progressing with keratotic papular lesions.

This report presents two familial cases of Darier's disease of a mother and her daughter.

## Case Report 1

A 47-year-old woman presented to our clinic with numerous mildly itching brown eruptions on the trunk and skin folds, having persisted and worsened for about 30 years. Her symptoms increased with sunlight and sweating and improved in the winter. Her history revealed that she had hepatitis B infection for 12 years, and she had been receiving telbivudine therapy for 14 months. In addition, she had generalized anxiety disorder for 4 years, and was using paroxetine for 2 years. Further investigation revealed that her daughter had similar eruptions. Physical examination findings were normal. Dermatological examination revealed numerous brown hyperkeratotic papular lesions on the bilateral axillary regions, beneath the breasts and on the trunk (Figure 1). Complete blood count and routine biochemical tests were within normal limits. A punch biopsy from a keratotic papular lesion on the trunk was performed. Histopathologically, a parakeratotic plug accompanying hyperkeratosis was detected in the stratum corneum (Figure 2). Beneath the parakeratotic plug, mild papillomatosis, irregular acanthosis, and focal suprabasal acantholysis were observed in the epidermis, by performing serial sections (Figure 3). In addition, dyskeratotic cells were present in the formation of "corps ronds" and "grains" in the upper part of the epidermis (Figure 3). Mild rete hyperplasia in the upper dermis was detected. There were mild perivascular chronic inflammation and melanophages in the upper dermis. The histopathological features were evaluated as compatible with Darier's disease. After clinicopathological correlation, the case was diagnosed as Darier's disease. Treatment with acitretin (25 mg/day) was started.



Figure 1. Brown hyperkeratotic papules on the trunk in Case 1.

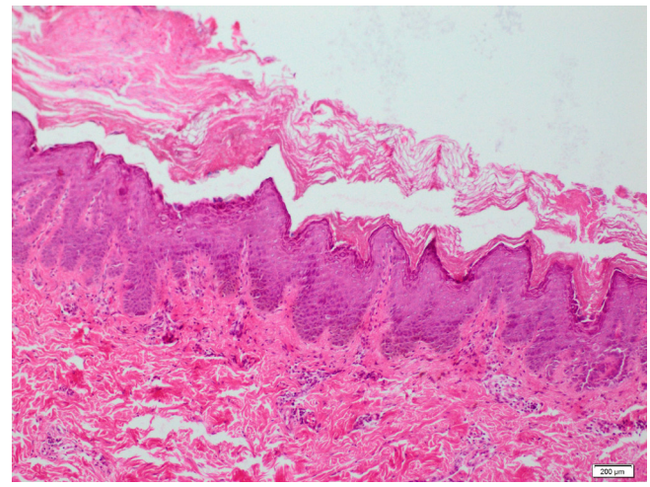

Figure 2. The microscopic photo of Case 1 showing focal suprabasal acantholysis (H&E, x40).

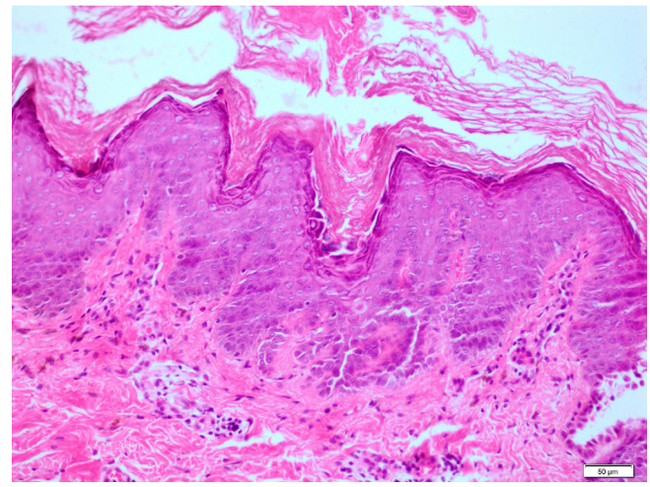

Figure 3. The higher-power microscopic view of Case 1 illustrating focal suprabasal acantholysis, dyskeratotic cells as "corps ronds", and "grains" (H&E, x200).

## Case Report 2

The 28-year-old daughter of Case 1 had eruptions extending from the neck to the trunk for approximately 10 years. These eruptions increased in size and number in the summer, and itching occurred. No characteristic finding was determined in her clinical history. Physical examination findings were normal. Dermatological examination revealed brown hyperkeratotic papular lesions on both sides of the neck, and both beneath and

between the breasts (Figure 4). Complete blood count and routine biochemical tests were within normal limits. A punch biopsy from a keratotic papular lesion on the neck was performed. The histopathological findings were similar but more striking and characteristic than Case 1. In the present case suprabasal acantholysis was extensive and formed suprabasal clefts (Figure 5). Dyskeratotic cells as "corps ronds" and "grains" in the upper part of the epidermis were also present (Figure 6). There was mild perivascular chronic inflammation accompanying a few eosinophils and melanophages in the upper dermis. The histopathological features were reported as consistent with Darier's disease. On the basis of clinical and histopathological findings, the case was diagnosed as Darier's disease. Topical 0.1% adapalene gel and moisturizing cream treatment was started. Since the patients did not attend to regular follow-up, the efficiency of the treatment could not be determined.



Figure 4. Brown hyperkeratotic papules on the neck of Case 2.

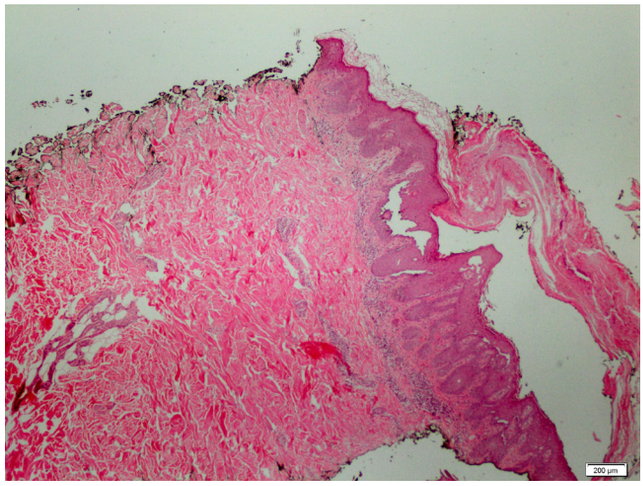


Figure 5. The microscopic photo of Case 2 showing extensive suprabasal acantholysis forming suprabasal clefts (H&E, x40).

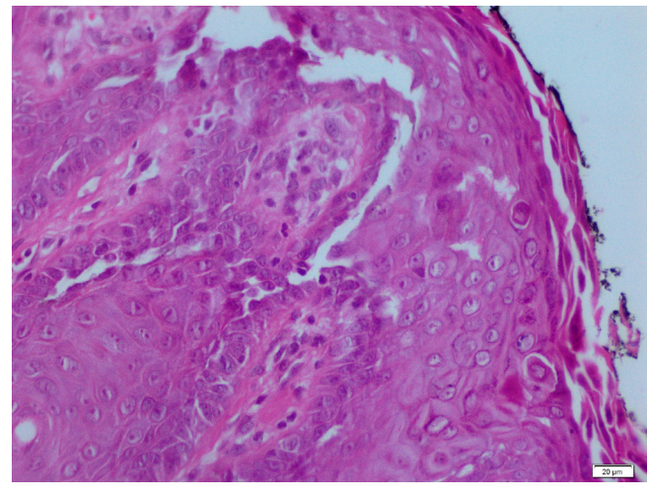


Figure 6. The high-power microscopic view of Case 2 illustrating suprabasal clefts, dyskeratotic cells as "corps ronds", and "grains" (H&E, x400).

## Discussion

The characteristic features of Darier's disease are fatty, hyperkeratotic hard lesions located at the anterior part of the chest, the middle part of the back, and seborrheic areas such as the hair margins and flexural areas. In general, the lesions are itching. The symptoms usually begin between the ages of 6 and 20 years, and peak in puberty. Clinically, Darier's disease may be confused with seborrheic dermatitis and acne. The triggering factor initiating pathogenesis is unknown, but increased sebum secretion in puberty and changes in bacterial flora are thought to play significant roles. Symptoms may worsen with sunlight and sweating, as in our cases. This is attributed to solar injury induced inflammation [1, 5].

Hair is generally normal in Darier's disease, while hairy skin is frequently covered with thick, fatty squames and crusts. Acral involvement in the form of punctate, keratotic papules is seen on the hands and feet in 95% of patients [1, 6]. Nail involvement manifests as fragility in the nails, subungual hyperkeratosis and splinter hemorrhage. Longitudinal white ridges may appear, and V-shaped nicks are seen at the free edge of the nail. Oral mucosal involvement may occur in about 15% of the cases as mucosal plaques and/or a cobblestone appearance in the hard palate [2, 4, 5]. In our cases there was no hairy skin, acral area, nail or oral mucosa involvement.

Darier's disease is a disorder of epidermal maturation and keratinization showing acantholytic dyskeratosis, histopathologically. The most strikingly characteristic features are suprabasal acantolysis forming clefts or lacunae, and dyskeratotic cells called "corps ronds" and "grains", histopathologically (1, 7). The histopathological appearance also supported diagnosis in our cases.

No relation is determined between Darier's disease and other medical problems in the literature. However, accompanying neuropsychiatric problems such as bipolar affective disorder, mental retardation, schizophrenia, recurrent depression, attempted suicide and epilepsy have been reported in some families [5, 6]. Our first case had a history of paroxetine use due to generalized anxiety disorder. Although Darier's disease exhibits a progressive course, it has no important complications. The most common complications are secondary skin infections such as widespread viral, bacterial, and dermatophyte infections [7].

No complication was observed in our cases.

The main approach for the treatment of Darier's disease includes avoiding heat and sunlight, and using emollients. Antiseptics, retinoids, tacrolimus, and 15% fluorouracil are used in topical treatment. Isotretinoin and acitretin therapies are more popular in widespread and serious cases [1, 5]. Alitretinoin, an endogenous retinoid used in severe, chronic hand eczema resistant to topical potent steroids, has recently been reported to be more beneficial in Darier's disease [8]. Oral treatments including prednisolone, cyclosporine, oral contraceptives, and essential fatty acids are the alternative therapies that are used rarely. Surgical procedures such as laser and dermabrasion may be tried if there is no response to oral therapies [6].

In conclusion, Darier's disease is an inherited rare entity that is a member of the acantholytic dyskeratosis family. It should be kept in mind in the differential diagnosis of dermatoses progressing with keratotic papular lesions, clinically. In the present report, a mother and her daughter with Darrier's disease are presented emphasizing the rarity of this disorder, the significance of the detailed clinical history, and a summary of the basic diagnostic and therapeutic approaches.

### *Competing interests*

The authors declare that they have no competing interests.

**References**

1. Hovnanian A. Acantholytic disorders of the skin: Darier-White disease, acrokeratosis verruciformis, Grover disease, and Hailey-Hailey disease. In: Wolff K, Goldsmith LA, Katz SI, Gilchrest BA, Paller AS, Leffell DJ, editors. Fitzpatrick's dermatology in general medicine. 7th ed. New York: Mc Graw Hill; 2008. p.432-42.
2. Bernabé DG, Kawata LT, Beneti IM, Crivelini MM, Biasoli ER. Multiple white papules in the palate: oral manifestation of Darier's disease. Clin Exp Dermatol 2009;34(7):270-1.
3. Onozuka T, Sawamura D, Yokota K, Shimizu H. Mutational analysis of the ATP2A2 gene in two Darier disease families with intrafamilial variability. Br J Dermatol 2004;150(4):652-7.
4. Elmas ÖF, Kızılyel O, Metin MS, Bilen H, Atasoy M, Gürsan N. Komedonal Darier hastalığı: Bir olgu sunumu. Türkderm 2014;48(Özel Sayı 2):94-6.
5. Canpolat F, Cemil BÇ, Eskioğlu F, Oktay M, Alper M. Darier hastalığı ile bipolar afektif bozukluk birlikteliği. Turkiye Klinikleri J Dermatol 2009;19(1):46-50.
6. Cooper SM, Burge SM. Darier's disease: epidemiology, pathophysiology, and management. Am J Clin Dermatol 2003;4(2):97-105.
7. Zeglaoui F, Zaraa I, Fazaa B, Houimli S, El Fekih N, Ezzine N, et al. Dyskeratosis follicularis disease: case reports and review of the literature. J Eur Acad Dermatol Venereol 2005;19(1):114-7.
8. Anuset D, Goutorbe C, Bernard P, Reguiai Z. Efficacy of oral alitretinoin for the treatment of Darier disease: a case report. J Am Acad Dermatol 2014;71(2):46-8.

*How to cite this article:*
Colgecen E, Sahin S, Borlu M, Seckin S. Darier's Disease: Two Familial Case Reports. J Clin Anal Med 2015;6(suppl 6): 886-9.