Case Report

JCAM

A New Association or Coincidence: Supraventricular Tachycardia in a Child Receiving Hyoscine N-Butylbromide

Yeni Bir İlişki veya Tesadüf: Hiyosin N-Butilbromid Alan Bir Çocukta Supraventriküler Taşikardi

Supraventricular Tachycardia in a Child Receiving Hyoscine N-Butylbromide

Eyup Aslan[1], Ebru Aypar[2], Ahmet Sert[1], Sukru Arslan[3], Dursun Odabas[1]
[1]Department of Pediatric Cardiology, Konya Training and Research Hospital, Konya,
[2]Department of Pediatric Cardiology, Hacettepe University, Faculty of Medicine, Ankara,
[3]Department of Pediatric Nephrology, Konya Training and Research Hospital, Konya, Turkey

Özet

Hiyoskin N-Butilbromid, periferal etkili antikolinerjik, antimuskarinik bir ilaçtır. Gastrointestinal ve genitoüriner sistemin spazmlarının tedavisinde kullanılmaktadır. Antikolinerjik etkisi sebebiyle, atropine benzer şekilde pozitif kronotropik özelliğinden dolayı sinüs taşikardisine yol açabilmektedir. Bununla birlikte, literatürde hiyoskin n-butilbromid ile supraventriküler taşikardi birlikteliği bildirilmemiştir. Bu yazıda karın ağrısı için hiyoskin n-butilbromid tedavisi esnasında supraventriküler taşikardi gelişen bir olguyu sunuyoruz.

Anahtar Kelimeler

Çocuk; Hiyoskin N-Butilbromid; Supraventriküler Taşikardi

Abstract

Hyoscine N-Butylbromide, is a peripherally acting antimuscarinic, anticholinergic agent. It is used for spasms of gastrointestinal and genitourinary trackt. Because of anticholinergic effects, it exerts positive chronotropic agent like atropine, may lead to sinus tachycardia. However, there has been no reported an association of supraventricular tachycardia and hyoscine n-butylbromide. In this report, we report a case that developed supraventricular tachycardia during hyoscine n-butylbromide therapy for his abdominal pain.

Keywords

Child; Hyoscine-N-Butylbromide; Supraventricular Tachycardia

DOI: 10.4328/JCAM.1394 Received: 12.11.2012 Accepted: 31.12.2012 Printed: 01.05.2016 J Clin Anal Med 2016;7(3): 400-402
Corresponding Author: Eyup Aslan, Department of Paediatric Cardiology, Konya Training and Research Hospital, 42080, Konya, Turkey.
T.: +90 3323236709 F.: +90 3323236723 E-Mail: doktor_eyup@mynet.com

Introduction

Supraventricular tachycardia (SVT) is the most common rhythm disturbance in children. The true incidence of SVT in children is unknown but has been estimated to be 1 in 250-1000 children [1]. Most patients presenting with episodic palpitations have a structurally normal heart. Myocarditis, electrolyte disturbances, some congenital heart defects and cardiac surgeries as well as drugs may cause SVT. However, we report a case that developed supraventricular tachycardia during hyoscine n-butylbromide therapy.

Case Report

A 13 year-old boy was admitted with complaints of abdominal pain and palpitation at department of paediatric emergency. His past history was unremarkable except he was given hyoscine-n-butylbromide for abdominal pain on a previous day. Physical examination revealed: body weight: 68 kg (90-97 p), height: 159 cm (50-75 p), respiratory rate: 30/min, body temperature: 36.9 °C, blood pressure: 110/80 mmHg. He had no unconsciousness and regular tachycardia (pulse rate: 220/min) with no murmur. On abdominal palpation he had a pain at periumblical and right hypochondriac areas. A chest X- ray showed no cardiomegaly. Echocardiography was normal. A 12 lead ECG was consistent with SVT (heart rate: 221 beats/min, narrow QRS complex and absent of P waves) (Figure 1). Complete blood count, serum electrolytes, renal function and liver enzymes all were normal. C-reactive protein and sedimentation rate levels were elevated as 190 mg/ml (N: 0-5 mg/ml), 48 mm/h (N: 20 mm/h), respectively. The patient was diagnosed as SVT induced by hyoscine n-butylbromide therapy based on the clinical and electrocardiographic findings.

At first, vagal manoeuvres were performed, but they were not successful. Afterwards, supraventricular tachycardia reverted to sinus rhythm with intravenous adenosine (a dose of 150 µg per kg), but tachycardia recurred within thirty minutes, which was terminated with adenosine (150 µg per kg) again. Tachycardia didn't recur and metoprolol (1 mg/kg per day) was started for maintenance of treatment. Abdominal US revealed plastron appendicitis. Ampicillin (200 mg per kg per day), ceftriaxon (75 mg per kg per day) and metronidasole (30 mg per kg per day) were recommended for therapy of plastron appendicitis by paediatric surgeon. These antibiotics were ceased after 10 days. On follow-up, the patient remained in a good clinical condition without abdominal pain and recurrence of palpitations and repeated ECG showed sinus rhythm. After discharge, 24-hour ECG showed no arrhythmia. The patient has been also followed up by department of paediatric surgery.

Discussion

Hyoscine-N-Butylbromide, is a peripherally acting antimuscarinic, anticholinergic agent used as an abdominal-specific antispasmodic. It is a quaternary ammonium compound and a semi synthetic derivative of scopolamine. Like its precursor scopolamine, it blocks the action of acetylcholine at parasympathetic sites in smooth muscle [2]. The commonly reported side effects of hyoscine-n-butylbromide include acute urticaria and angioneurotic edema [3]. Because of anticholinergic effects, it exerts positive chronotropic agent like atropine, may lead to tachycardia. There has been reported association between atropine and SVT in the literature [4] but, to the best of our knowledge, no association with hyoscine n-butylbromide.

In SVT, most patients presenting with episodic palpitations have a structurally normal heart. In older children the heart rate is extremely rapid (usually 160 to 280 beats/min) and regular. Electrocardiogram shows tachycardia with regular rhythm, usually invisible p wave and narrow QRS complex. It must be distinguished from other forms of tachycardia with narrow QRS. Quite often, the idiopathic fascicular left ventricular tachycardia (IFLVT) can be confused with a SVT because of its relatively narrow QRS. Idiopathic fascicular left ventricular tachycardia is the most common idiopathic ventricular tachycardia of the left ventricle in structurally normal heart. Idiopathic fascicular left ventricular tachycardia typically presents in young adults (15 to 40 years), mainly affects males (60-80%) and diagnosis requires exclusion of structural heart disease. The most frequent clinical presentation is paroxysmal episodes of palpitations and dizziness, as similar to SVT [5]. Our case was a male adolescent with structurally normal heart. His ECG showed a regular tachycardia with 221 beats/ min, invisible p wave, and narrow QRS complex, suggested to SVT. The tachycardia responded to adenosine administration. However, IFLVT usually does not respond to vagal manoeuvres, adenosine or beta-blockers; but response to vera-

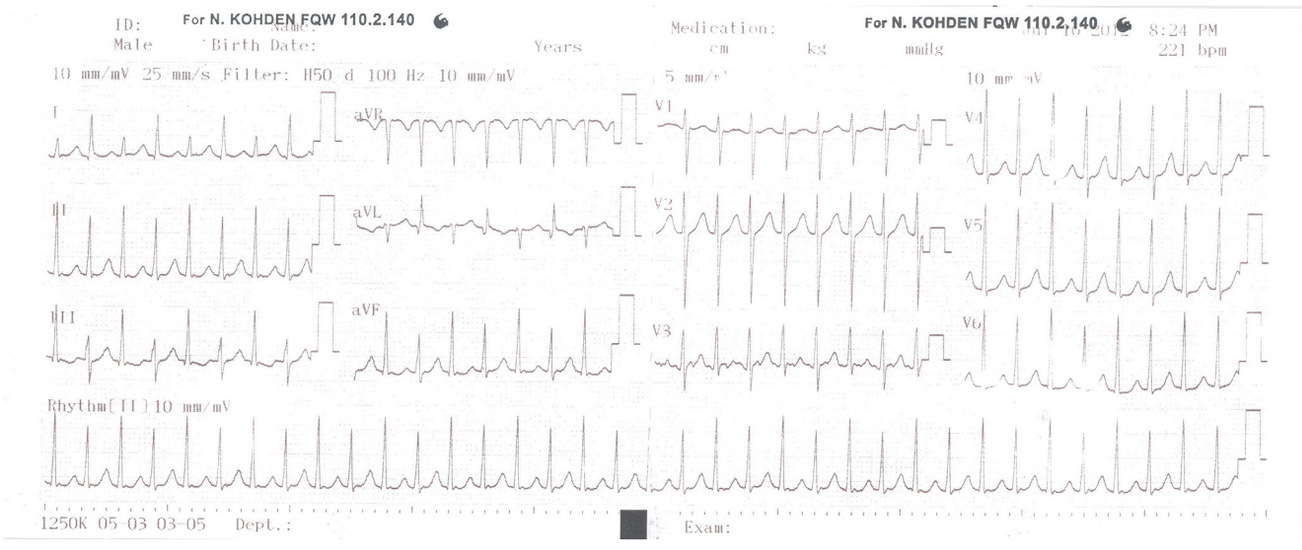

Figure 1. Electrocardiography shows SVT (heart rate: 221 beats/min, narrow QRS complex and absent of P waves)

pamil is an important feature of it. Electrophysiologically, IFLVT behaves as a re-entrant tachycardia. It is characterized by right bundle branch block (RBBB) pattern and the QRS axis depends on which fascicle is involved in the re-entry. Posterior fascicular ventricular tachycardia (90-95% of cases) shows RBBB and left axis, anterior fascicular ventricular tachycardia shows RBBB and right axis [5]. In our patient, there was no bundle branch block and QRS axis was within normal. In our patient, we think that hyoscine-n-butylbromide may have led to SVT; however, it may have also resulted from sympathetic hyperactivation because of his abdominal pain due to acute appendicitis.

Intravenous adenosine is the first line drug for termination of SVT in infants and children. Beta blockers can be chosen for maintenance of treatment of SVT between several drugs [6]. Adenosine is extremely effective in terminating supraventricular tachycardia. It causes a temporary atrioventricular nodal (AV) conduction block and interrupts circuits that involve the AV node. The Paediatric Advanced Life Support guidelines recommend a first dose of 100 µg per kg followed by a second dose of 200 µg per kg, if necessary [7]. Dixon et al, [8] found a median effective dose of 150 µg per kg, in older children. In our patient, tachycardia responded to adenosine administration by a dose of 150 µg per kg, as this study.

In conclusion, we would like to emphasize that clinicians should be aware of the possibility that cardiac arrhythmias might be the results of hyoscine n-butylbromide administration and should be used with caution and monitoring these patients closely.

Competing interests

The authors declare that they have no competing interests.

References

1. Losek JD, Endom E, Dietrich A, Stewart G, Zempsky W, Smith K. Adenosine and pediatric supraventricular tachycardia in the emergency department: multicenter study and review. Ann Emerg Med 1999; 33(2):185-91.
2. Weiser T, Just S. Hyoscine butylbromide potently blocks human nicotinic acetylcholine receptors in SH-SY5Y cells. Neurosci Lett 2009; 450(3):258-61.
3. Robinson AC, Teeling M. Angioneurotic oedema and urticaria induced by hyoscine butylbromide. Postgrad Med J 1982; 58(679):316.
4. Merli GJ, Weitz H, Martin JH, Mc Clay EF, Adler AG, Fellin FM. Cardiac Dysrhytmias Associated With Ophthalmic Atropine. Arch Intern Med 1986; 146(1):45-7.
5. Francis J, Venugopal K, Khadar SA, Sudhayakumar N, Anoop KG. Idiopathic Fascicular Ventricular Tachycardia. Indian Pacing and Electrophysiology Journal 2004; 4 (3):98-103.
6. Ceviz N, Çeliker A. Çocuklarda Görülen Artitmilerin Farmakolojik Tedavisi. Türk Aritmi ve Elektrofizyoloji Dergisi 2005; 3(3):173-87.
7. Kleinman ME, Chameides L, Schexnayder SM, Samson RA, Hazinski MF, Atkins DL et al. Pediatric Advanced Life Support: 2010 American Heart Association Guidelines for Cardiopulmonary Resuscitation and Emergency Cardiovascular Care. Pediatrics 2010; 126 (5):1361-99.
8. Dixon J, Foster K, Wyllie J, Wren C. Guidelines and adenosine dosing in supraventricular tachycardia. Arch Dis Child 2005; 90:1190-1.