Case Report
JCAM

Coronary Arteriovenous Fistula in a Child Presenting with Chest Pain

Göğüs Ağrısı ile Başvuran Bir Çocukta Koroner Arteriovenöz Fistül

Derya Arslan[1], Derya Cimen[1], Bulent Oran[1], Nazif Aygul[2]
[1]Department of Pediatric Cardiology, [2]Department of Cardiology,
Selcuk University Medical Faculty, Konya, Turkey

Bu olgu bildirimi daha önce 10.Ulusal Pediatrik Kardiyoloji ve Kalp Damar Cerrahisi Kongresinde (04-07 Mayıs 2011-Gaziantep) poster olarak sunulmuştur.

Özet

Koroner arteriyovenöz fistül koroner anjiyografilerin % 0.1-% 0.2'sinde rastlantısal bir bulgudur. On beş yaşındaki kız hasta 3 yıldan beri efor ile oluşan göğüs ağrısı ile başvurdu. Ekokardiyografi daha önce yapılmıştı ve küçük bir musküler ventriküler septal defekt saptanmıştı. Elektrokardiyografisi normal aksla beraber sinüs ritmindeydi. Ekokardiyografide sol ventrikül fonksiyonları normaldi ve sağ ventrikül içine devamlı akım vardı. Bu nedenle koroner arter fistülü olabileceği düşünüldüğü için koroner anjiyografi yapıldı. Sol ön inen (LAD) koroner arterden ayrılan birinci septal perforan dal ile sağ ventrikül arasında koroner arteriovenöz fistül olduğu görüldü. Önemli bir şant saptanamadığı için hastanın klinik takibine karar verildi.

Anahtar Kelimeler

Angina Pektoris; Koroner Fistül; Koroner Anjiyografi

Abstract

Coronary arteriovenous fistula is an incidental finding in 0.1% to 0.2% of coronary angiograms. A 15-year-old famale patient presented with a three years history of chest pain on exertion. Echocardiography was performed previously and a small muscular ventricular septal defect was detected. The electrocardiogram was normal sinus rhythm together with normal axis. On echocardiography, left ventricular function was normal and there was continuous flow into the right ventricle. Therefore, coronary angiography was performed for considering the coronary artery fistula. Coronary artery fistula was observed between the first septal perforating branch of the left anterior descending coronary artery with right ventricle. The patient's clinical follow-up was decided since a significant shunt could not be identified.

Keywords

Angina Pectoris; Coronary Fistula; Coronary Angiography

DOI: 10.4328/JCAM.1425 Received: 26.11.2012 Accepted: 16.12.2012 Printed: 01.05.2016 J Clin Anal Med 2016;7(3): 391-393
Corresponding Author: Derya Arslan, Selcuk University Faculty of Medicine, Department of Pediatric Cardiology, 42080 Konya, Turkey.
T: +90 3322415000 F.: +90 3323236723 E-Mail: aminederya@hotmail.com

Introduction

Coronary arteriovenous fistula (CAF) is an abnormal precapillary connection between a coronary artery and a cardiac chamber, a great artery, superior vena cava, or coronary sinus. It is a very rare malformation and incidence is 0.2-0.4% of all congenital cardiac defects. It usually arises from the right coronary artery and roughly 90% of the fistulas drain into the venous circulation [1-2].

It is rare but it can cause an important coronary morbidity and mortality leading to angina, syncope, congestive heart failure, myocardial infarction and sudden death. Cardiac catheterization and coronary angiography are necessary for the precise delineation of coronary anatomy, assessment of hemodynamic parameters, and to detect concomitant atherosclerosis and other structural anomalies. In symptomatic cases, therapeutic options include surgical correction or transcatheter embolization [3].

Case Report

A 15-year-old female child presented with effort related burning type chest pain of 3 years duration. She has had no particular prior medical/surgical history. Echocardiography was performed previously and a small muscular ventricular septal defect was detected. On the physical examination, her heart sounds were normal and no murmur was heard. The pulse rate was 85 beats/min and the blood pressure was 110/70 mmHg. Other physical examination findings were normal. The electrocardiogram displayed normal sinus rhythm. Cardiac biomarker enzymes, 24-hour holter monitoring and chest radiograph (cardiothoracic ratio=0.47) results were normal.

The patient underwent exercise testing, cardiac arrhythmia and chest pain did not occur. The transthoracic echocardiographic evaluation showed that the mosaic flow into the right ventricle (Figure1). However, echocardiography demonstrated a normal finding with good left ventricular systolic function and 24-hour holter monitoring showed no specific findings. There was a CAF on the coronary angiogram. The CAF was between the right ventricle and the first septal perforating branch of the left anterior descending coronary artery (Figure2). The clinical follow-up was decided since the patient is not a significant shunt.

Discussion

Coronary arteriovenous fistula (CAF) is usually congenital and is found to originate from the right coronary artery and to drain into the right ventricle in the majority of reported cases [4]. In our case it originated from the left anterior descending artery and was draining to the right ventricle. Concomitant congenital cardiovascular abnormalities such as tetralogy of Fallot, atrial septal defect and ventricular septal defect have been reported in the literature [5]. Our patient did not have any other congenital heart disease.

The clinical presentation is mainly dependent on the severity of the shunt. However, about half of the patients are asymptomatic. Symptomatic patients may present with atypical chest pain, palpitation, heart failure, bacterial endocarditis, or with an incidental continuous murmur which is characteristically heard over the left sternal border and apex [6]. Our patient presented with effort related burning type chest pain of 3 years duration.

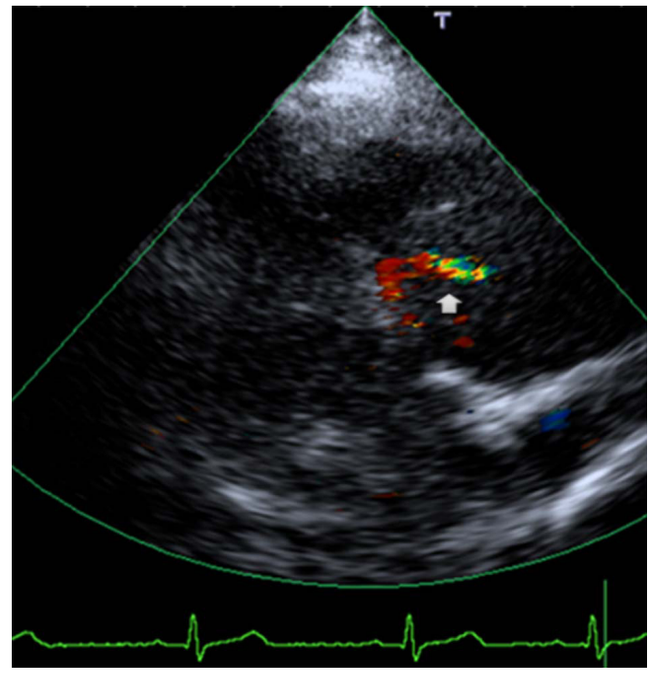

Figure 1. Echocardiographic images showing a mosaic flow in the right ventricle (arrow).

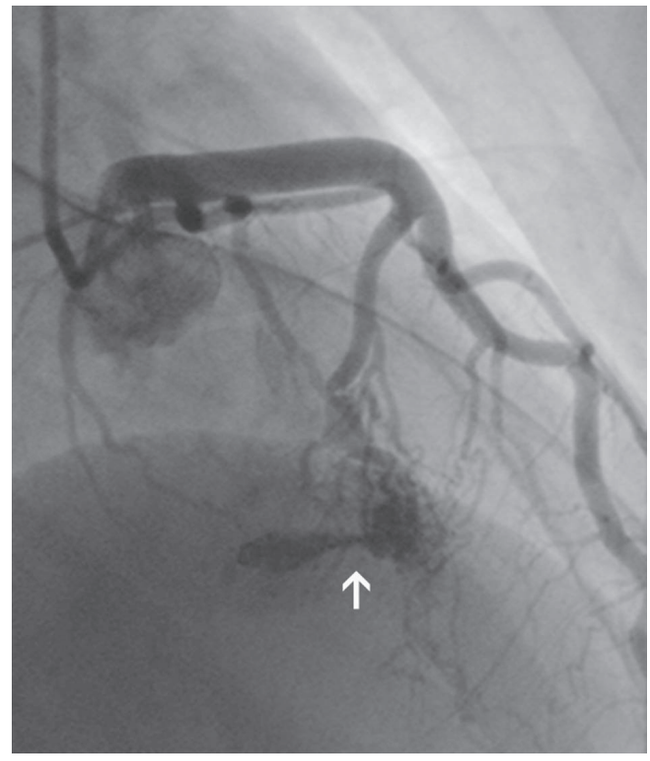

Figure 2. Angiographic view showing a coronary arteriovenous fistula originating from the first septal branch of the left anterior descending artery and the latter drained into the right ventricle (arrow).

The most significant complications are pulmonary hypertension due to large left-right shunt, bacterial endocarditis, aneurismal dilatation, rupture or thrombosis of the fistula and myocardial ischemia [7]. Coronary arteriovenous fistula may be discovered during the evaluation of a continuous murmur at the precordium and are usually diagnosed incidentally at coronary angiography. Although, transthoracic echocardiography can show the dilated coronary arteries and color Doppler imaging the turbulent flow of the fistula. Chest X-ray can reveal pulmonary artery enlargement and cardiomegaly. In electrocardiographic investigation, right ventricular hypertrophy, right bundle branch block, left

bundle branch block and ischemic changes can be seen [6-8]. In our case a myocardial ischemia or significant shunt was not documented. Treatment of congenital CAF is strongly recommended in symptomatic patients. But, CAF which do not cause symptoms, myocardial ischemia and significant shunting can be followed noninvasively. Coronary ischemia is primary indications for closure of a fistula. Surgical closure is effective and provides long-term safety. Although, catheter based closure has become the preferred treatment option [8].

In conclusion, CAF is a frequent form of coronary artery anomalies that can cause serious symptoms and findings such as myocardial ischemia. Therefore, they should always be considered during diagnostic work. Symptomatic patients should be promptly treated.

Competing interests

The authors declare that they have no competing interests.

References

1. Darwazah AK, Hussein IH, Hawari MH. Congenital circumflex coronary arteriovenous fistula with aneurysmal termination in the pulmonary. Tex Heart Inst J 2005;32(1):56-9.
2. Vitarelli A, De Curtis G, Conde Y, Colantonio M, Di Benedetto G, Pecce P, et al. Assessment of congenital coronary artery fistulas by transesophageal color Doppler echocardiography. Am J Med 2002;113(2):127-33.
3. Gowda RM, Vsavada BC, Khan IA. Coronary artery fistulas: clinical and therapeutic considerations. Int J Cardiol 2006;107(1):7–10.
4. Levin DC, Fellows KE, Abrams HL. Hemodynamically significant primary anomalies of the coronary arteries, angiographic aspects. Circulation 1978;58(1):25–34.
5. Said SA, Lam J, van der Werf T. Solitary coronary artery fistulas: a congenital anomaly in children and adults. Congenit Heart Dis 2006;1(3):63–76.
6. Abdelmoneim SS, Mookadam F, Moustafa SE, Holmes DR. Coronary artery fistula with anomalous coronary artery origin: a case report. J Am Soc Echocardiogr 2007;20(3):333-4.
7. Gunduz H, Akdemir R, Binak E, Ayarcan Y, Kurtoglu N, Uyan C. A case of coronary artery fistula with mitral stenosis. The International Journal of Cardiovascular Imaging 2003;19(161):533–36.
8. Gowda RM, Vasavada BC, Khan IA. Coronary artery fistulas: clinical and therapeutic considerations. Int J Cardiol 2006;107(1):7-10.