Atraumatic First Rib Fracture

Atravmatik Birinci Kot Fraktürü

Atraumatic Fracture

Koray Aydoğdu, Serdar Özkan, Ülkü Yazıcı, Nurettin Karaoğlanoğlu
Atatürk Göğüs Hastalıkları ve Göğüs Cerrahisi Eğitim ve Araştırma Hastanesi, Göğüs Cerrahisi Kliniği, Ankara, Türkiye

Özet

Kot fraktürleri genellikle travma sonrası görülmekte olup atravmatik spontan kot fraktürü oldukça nadirdir. Ağır yük kaldırma dışında travma hikayesi olmayan 17 yaşındaki bayan olgumuzda tespit edilen izole birinci kot fraktürü, olası komplikasyonlar açısından detaylı incelendi ve uzun dönem takibe alındı. Etiyolojiye yönelik farklı görüşlerin bildirildiği atravmatik birinci kot fraktürü olgumuza ait klinik tecrübemizi literatür eşliğinde sunduk.

Anahtar Kelimeler

Ağrı; Atravmatik; Birinci Kot Fraktürü

Abstract

Rib fractures are usually seen after a trauma, while atraumatic spontaneous rib fractures are quite rare. A first rib fracture identified in our 17 years old female patient who had not a history of trauma except lifting a heavy weight was examined in details in terms of the potential complications and followed-up for a long time. We presented our experience on this case with atraumatic first rib fracture that has different views for the etiology in light of the literature.

Keywords

Pain; Atraumatic; First Rib Fracture

DOI: 10.4328/JCAM.1471 Received: 12.12.2012 Accepted: 26.12.2012 Printed: 01.05.2016 J Clin Anal Med 2016;7(3): 397-399
Corresponding Author: Serdar Özkan, Atatürk Göğüs Hastalıkları ve Göğüs Cerrahisi Eğitim ve Araştırma Hastanesi, Göğüs Cerrahisi Kliniği, Sanatoryum Caddesi, 06280 Kecioren, Ankara, Turkey. T.: +90 3123552110 F.: +90 3123552135 E-Mail: drozkan78@yahoo.com

Introduction

Rib fractures usually emerge due to traumatic reasons. Although seen, atraumatic and spontaneous rib fractures are quite rare. We aimed to share our young case in which isolated first rib fracture developed without an obvious trauma history in light of the literature.

Case Report

Our 17 years old female case who had not any trauma history presented to our clinic with the complaints of shoulder and chest pain with abrupt onset and pain and limitation in the right arm movements. On the chest radiography, right first rib fracture was detected. In her detailed medical history, the patient had no history of trauma, but had lifted heavy weights for the last 3 days due to the cookery training she received. Except the first rib fracture, her chest X-ray graphy did not reveal pneumothorax, hemothorax, subcutaneous emphysema (Figure 1). On the examination carried out in terms of the injury may occur due to the first rib fracture, no pathological findings were found. On right subclavian vascular doppler examination, arterial and venous flow patterns were normal (Figure 2). No electrolyte abnormality was monitored in the laboratory analysis. Hereupon, the patient was informed in details, administered proper analgesic and anti-inflammatory therapy and symptomatic recovery was achieved. No pathology developed in the case which is still under our follow-up program. The patient was informed on the long term complications.

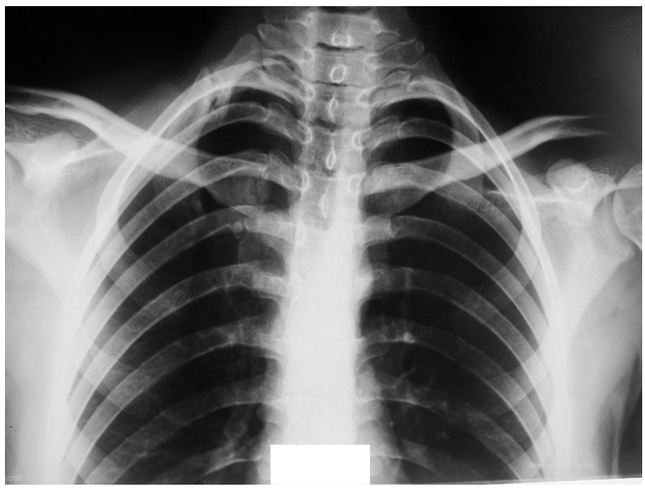

Figure 1. Chest x-ray radiography

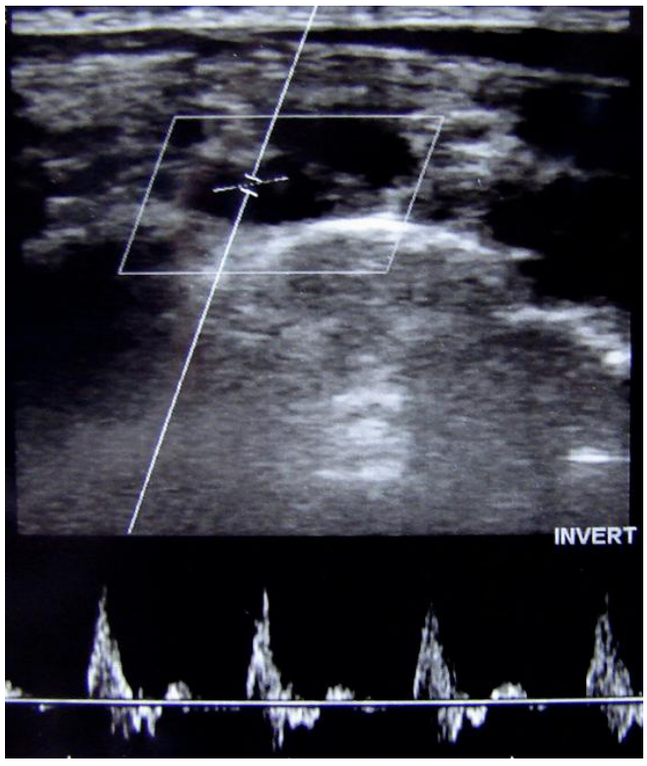

Figure 2. Right subclavian vascular Doppler examination

Discussion

The most common cause of rib fracture is trauma. Shoulder girdle (anteriorly clavicle, posteriorly scapula and laterally arms and upper thoracic muscles) protects the first three ribs from the injury. Fracture of these ribs point out the likelihood of serious internal damage . Especially brachiocephalic vascular injury is a likelihood in this region and requires further diagnostic procedures. The incidence of isolated first rib fracture and related major vascular injury is about 3% [1]. Several theories have been suggested for etiology of the first rib fractures. Traumatic isolated first rib fracture is usually infrequent and often accompanied by scapula and clavicula fractures. Because scapula and clavicula are well protected by the soft tissues, first rib fractures require a significant force to occur. Nontraumatic fractures are considered as stress fractures occurred without an effectual trauma and usually emerge in the weakest point of rib. Whereas most of the spontaneous fractures are caused by advanced age, renal failure, metastatic tumors or osteoporosis. Atraumatic isolated first rib fractures are quite rare. The muscular contraction force to be applied on a rib will create a stress on the rib. Rib will undergo inelastic deformation if the force applied exceeds its elastic limit. In inelastic deformation, particularly the trauma applied on the same point is crucial. Stress fractures occur when the opposite forces that are repeated due to lifting or carrying heavy weights exceed the strength limits of the bone [2]. Fractures related to paroxysmal cough generally develop between the 5th and 10th ribs, while stress fractures due to the other reasons frequently occur in the first rib [2]. Most authors advocate the first rib stress fracture to be resulted from the anatomical structure of that rib [3]. Other authors believe the mechanism of 1st rib fracture is that; contraction of the anterior scalene muscle and the front-upper parts of the m.serratus anterior with a sudden and strong traction of the arm produces opposite traction forces in the subclavian sulcus [4]. The force applied by these muscles to repeat and exceed the strength limit of rib results in the fractures. In an analysis of the cases with first rib fracture in Japan, Shinoda et al. reported fractures were caused by a sport activity (frequently baseball, judo and volleyball) in 32 of 115 cases. The interesting point to Shinoda was that no isolated first rib fractures were seen in the weight lifters, despite lifting heavy weights was the most blamed factors in the etiology [5]. The patients usually present with upper chest pain and localized tenderness. The most important problem in rib fractures is pain in which various treatment methods are used such us intravenous analgesia, intercostal blockade, epidural analgesia and patient controlled analgesic.

Conclusion

Despite their different etiology, vascular and neural injuries are

likely to occur in first rib fractures due to the anatomical proximity. That is why attention should be paid in such cases for the complications.

Competing interests

The authors declare that they have no competing interests.

References

1. Gupta A, Jamshidi M, Rubin JR. Traumatic first rib fracture: is angiography necessary? A review of 730 cases. Cardiovasc Surg 1997;5(1):48-53.
2. Leung H, Stirling A. Stress fracture of the first rib without associated injuries. Injury 1991;22(6):483-4.
3. Lorentzen J, Movin M. Fracture of the first rib. Acta Orthop Scand 1976;47(6):632-4
4. Frangakis E. Fractures of the first rib. Report of two cases of bilateral fracture of first rib. Acta Orthop Scand 1967;38(2):192-8.
5. Shinoda M, Shiba M, Uematsu O. Fractures of first rib in athletes (in Japanese). Orthop Surg Traumatol (19834) 26:559.