# High Definition Angiography for the Evaluation of Carotid Arteries in Stroke Patients

## İnme Hastalarında Karotid Arterlerin Yüksek Çözünürlüklü Bt Anjiografi ile Değerlendirilmesi



Aykut Recep Aktas, Omer Yılmaz, Mustafa Kayan, Mustafa Kara, Nisa Unlu, Tuna Parpar, Esma Dilek Ustun, Mert Koroglu
Süleyman Demirel University Faculty of Medicine Dept. of Radiology, Isparta, Turkey

**Özet**

Giriş: Yüksek çözünürlüklü (YÇ) Bilgisayarlı Tomografi (BT) invitro damar ve stentlerin kenarlarında netlik artışına neden olduğu bilinen BT teknolojisinde bir gelişme olarak sunuldu. Amacımız, inme hastalarında karotis damarların çapı ve duvar kalınlığını değerlendirerek bu teknolojinin etkinliğini araştırmaktır. Gereç ve Yöntem: BT Anjiyografi (BTA) karotis arter; 19 YÇBT ile 21 standart çözünürlüklü (SÇ) BT toplam 40 inme hastası aynı görüntüleme protokolleri ile farklı üniversite hastanelerinde tetkik edildi. Damar duvarı iç - dış çapları ve ortak, iç,dış karotid arterlerin (CCA, ICA ve ECA) duvar kalınlığı iki radyolog tarafından ölçüldü ve görüntüler kalitesi, hareket artefaktı ve gürültüsü açısından karşılaştırıldı. Bulgular: YÇ ve SÇ BT anjiyografi karşılaştırılabilir bulunmuştur. YÇBT ölçümlerinde radyologların uyumu ve Cronbach Alpha değeri daha yüksek olup damar konturlarının görüntülerde keskin ve ölçümlerin daha güvenilir olduğu gösterilmiştir. Tartışma: Teknolojik gelişmeler sonucu görüntü kalitesi YÇBT aniyografide iyileştirilmiştir. Bu yüzden işlem öncesi karotis ostiumundaki plakları , damar duvarının kenarlarını göstermede ve stenoz ölçümünde SÇBT den daha etkili olduğu düşünülmüştür.

**Anahtar Kelimeler**

Yüksek Çözünürlük; Bilgisayarlı Tomografi; Carotid Damarlar; Anjiografi; Görüntü Kalitesi

**Abstract**

Aim: High definition(HD) Computed Tomography(CT) was presented as an improvement in CT technology which is known to have increased in sharpness of the edges of the vessels and stents in vitro. The purpose of the study was to take the effectivity of this technology clinically by evaluating the diameter and wall thickness of carotid vessels in stroke patients. Material and Method: CT Angiography(CTA) of carotid arteries; 19 with HDCT and 21 with standard definition(SD) CT, totally 40 stroke patients were examined in different University hospitals with the same imaging protocols. The vessel wall inner and outer diameters and thickness of common, internal and external carotid arteries (CCA, ICA and ECA) were assessed by two blinded radiologists. Comparison was made between the scanners for image quality, motion artefacts and image noise. Results: HD and SD CT angiography achieved comparable. The agreement of the radiologists and Cronbach Alpha value was higher in HDCT showing that vessel contours are sharper in HDCT images and measurements are more reliable. Discussion: Due to new gemstone technology image quality was improved in HDCT angiography, is found much more effective than SDCT to show the edges of the vessel wall so qualifies the establishment of the plaques and extent of osteal stenosis.

**Keywords**

High Definition; Computed Tomography Angiography; Carotid Arteries; Image Quality

DOI: 10.4328/JCAM.2756 Received: 28.08.2014 Accepted: 20.09.2014 Printed: 01.05.2016 J Clin Anal Med 2016;7(3): 332-335
Corresponding Author: Aykut Recep Aktas, Department of Radiology, Medical Faculty, Suleyman Demirel University, Isparta, Turkey.
T.: +90 2462112050 F.: +90 2462112050 GSM: +905324747281 E-Mail: aykutraktas@gmail.com

## Introduction

Stroke is a leading cause of morbidity and is often related to focal atherosclerotic changes of the carotid arteries [1]. Computed tomography angiography (CTA) and conventional digital subtraction angiography (DSA) are the current standard imaging modalities used to detect these changes [2]. The most current technological advancements in CTA include the combination of dual-source technology with wide detectors and accelerated gantry rotation [3] as well as a new gemstone technology [4]. The aim of this study was to compare the diagnostic performance of high definition and standard definition CT scanners.

## Material and Method

This retrospective study included data collected from stroke patients between September 2011 and September 2013. A total of 40 stroke patients at various university hospitals were examined with either HDCT (19 patients) or standard definition (SD) CT using the same imaging protocols. SD images were collected from a 128-slice CT system (Somatom Definition 128, Siemens Healthcare, Forchheim, Germany), while high definition images were obtained using a 64-slice CT scanner (GE HDCT, GE Medical, Milwaukee, USA). Patients received 60 ml of the iodinated contrast medium, iohexol (Omnipaque 350, GE Healthcare, Amersham, UK), at a flow rate of 5.5 ml/s. This was followed by a 20 ml saline bolus injection, which was monitored with a 140 HU attenuation threshold within the aorta. For both the SD and HD protocols, images were reconstructed with a slice thickness of 0.6 mm and a smooth convolution kernel. Images were acquired from the aortic arch to the circle of Willis in the caudocranial direction. All data was transferred to Dicom image archiving software (Onis Viewer 2.5, Digital Core Co. Ltd., Tokyo, Japan) and measurements were performed using the axial images. For each patient, an objective assessment of the image quality was based on measurements from each arterial segment near the bifurcation of the common carotid artery (CCA) with the internal (ICA) and external (ECA) carotid arteries. The subjective evaluation of image quality was based on image quality, image noise, artifacts and enhancements of the bilateral carotid vessels. Quantitative image parameters were assessed by two radiologists who had either 4 or 5 years of experience in neuroradiology (ARA, OY). The ROI was adapted to the size of the lumen for the mean vessel attenuation. The wall thickness of each arterial segment was calculated from the di erences between each vessel's inner (Vid) (figure 1) and outer (Vod) diameters (figure 2). No measurements were obtained in the occluded or aplastic segments. The SD and HD CT examinations were randomly selected to ensure that the study was randomized and that the patients remained anonymous. The image quality of the arterial segments was assessed in terms of the sharpness of the vessel edges as well as the subjective evaluation of the vascular opacification versus noise. A five-point scoring scale was used as follows: 5 (excellent) indicated the absence of motion and noise, enhanced carotid artery image quality, very sharp edges, and high subjective contrast-to-noise ratio; 4 (very good) indicated minimal blurring; 3 (good) indicated slightly suboptimal subjective contrast-to-noise ratio; 2 (moderate) indicated vessel edge blurring or markedly suboptimal subjective contrast-to-noise ratio; 1 (nondiagnostic) indicated inappropriate blurring or subjective contrast-to-noise ratio.

### *Statistical analysis*

Statistical analyses were performed using the Statistical Package for Social Sciences software (version 15.0, SPSS Inc., Chicago, Illinois, USA). Cronbach Alpha values were measured for internal consistency. A Student's paired t-test was used to compare the measurements of the same radiologist from both the HD and SD CT scanners, and an independent samples t-test was used to compare the differences between the measurements of the two radiologists from both the HD and SD CT scanners. A p-value of less than 0.05 indicated statistical significance.

## Results

The correlation coefficients ranged between 0.54 and 0.99. These values were calculated from the difference in the measurements of the inner and outer vessel diameters (vessel thickness) from the HD and SD CT scanners. Both radiologists agreed on the values, and the difference between the scanners was statistically significant ($p<0.05$). The Cronbach Alpha value was 0.905 in HDCT and 0.782 in SDCT, indicating that HDCT measurements are more reliable. Vessel wall thickness was calculated from the differences between the inner and outer vessel diameters. There were no differences in the measurements of vessel wall thickness between the radiologists when using HDCT, but 6 (60%) of the SDCT measurements were statistically different ($p<0.05$) (table 1). The HDCT images had superior image quality and quantity, and the vessels had much sharper

Table 1. Mean values of measurements taken by the radiologists from each scanner type

| | HDCT(N=18) | | | SDCT(N=21) | | |
|---|---|---|---|---|---|---|
| | | Std. Error | | | Std. Error | |
| | Mean | Mean | p | Mean | Mean | p |
| R_CC_Vod_Dr1 | 1.82 | 0.13 | 0.086 | 1.09 | 0.16 | 0.106 |
| RCCVod_Dr2 | 1.90 | 0.14 | | 1.29 | 0.14 | |
| RICVod_Dr1 | 1.75 | 0.15 | 0.828 | 0.89 | 0.06 | 0.027 |
| RICVod_Dr2 | 1.74 | 0.15 | | 1.06 | 0.07 | |
| RECVod_Dr1 | 1.54 | 0.09 | 0.672 | 1.15 | 0.10 | 0.201 |
| RECVod_Dr2 | 1.52 | 0.10 | | 1.06 | 0.08 | |
| LCCVod_Dr1 | 1.89 | 0.13 | 0.718 | 1.29 | 0.20 | 0.036 |
| LCCVod_Dr2 | 1.91 | 0.14 | | 1.51 | 0.22 | |
| LICVod_Dr1 | 1.70 | 0.07 | 0.820 | 0.88 | 0.08 | 0.050 |
| LICVod_Dr2 | 1.69 | 0.08 | | 1.05 | 0.05 | |
| LECVod_Dr1 | 1.66 | 0.13 | 0.555 | 0.90 | 0.08 | 0.633 |
| LECVod_Dr2 | 1.62 | 0.13 | | 0.93 | 0.08 | |
| LICViddr1 | 5.26 | 0.21 | 0.254 | 6.38 | 0.32 | 0.012 |
| LICViddr2 | 5.42 | 0.22 | | 6.22 | 0.31 | |
| RICViddr1 | 5.45 | 0.27 | 0.304 | 6.35 | 0.23 | 0.862 |
| RICViddr2 | 5.66 | 0.34 | | 6.34 | 0.23 | |
| RECViddr1 | 4.49 | 0.24 | 0.161 | 4.37 | 0.14 | 0.006 |
| RECViddr2 | 4.53 | 0.24 | | 4.54 | 0.12 | |
| LECViddr1 | 4.65 | 0.14 | 0.150 | 4.59 | 0.24 | 0.050 |
| LECViddr2 | 4.88 | 0.17 | | 4.51 | 0.22 | |

L:Left, R: Right, CC: Common Carotid Artery, IC: Internal Carotid Artery, EC: External Carotid Artery, Vod: Vessel outer diameter, Vid: Vessel inner diameter, Dr: Doctor

Table 2. The comparison of CT parameters and attenuation values

| | | HDCT | | SDCT | | |
|---|---|---|---|---|---|---|
| | | Std. Error | | Std. Error | | |
| | N | Mean | Mean | Mean | Mean | P |
| kilo voltage | 18 | 122.22 | 1.52 | 120.00 | 0.00 | .123 |
| tube current (mA) | 18 | 224.11 | 43.41 | 214.29 | 0.44 | .808 |
| RCCHUdr1 | 18 | 338.11 | 22.34 | 375.14 | 18.29 | .203 |
| RCCHUdr2 | 18 | 340.06 | 22.09 | 372.10 | 18.15 | .265 |
| RICHUdr1 | 17 | 331.06 | 23.29 | 381.05 | 19.73 | .109 |
| RICHUdr2 | 17 | 337.24 | 22.95 | 380.68 | 19.17 | .153 |
| RECHUdr1 | 18 | 302.72 | 20.99 | 368.48 | 19.58 | .028 |
| RECHUdr2 | 18 | 309.39 | 21.48 | 368.10 | 19.59 | .050 |
| LCCHUdr1 | 18 | 351.56 | 21.58 | 369.25 | 14.69 | .495 |
| LCCHUdr2 | 18 | 352.94 | 20.98 | 376.10 | 16.78 | .390 |
| LICHUdr1 | 18 | 333.78 | 21.21 | 398.35 | 16.44 | .023 |
| LICHUdr2 | 18 | 336.78 | 20.14 | 392.00 | 17.04 | .045 |
| LECHUdr1 | 18 | 323.33 | 22.53 | 372.45 | 19.80 | .109 |
| LECHUdr2 | 18 | 329.00 | 22.08 | 372.85 | 20.55 | .154 |

L:Left, R: Right, CC: Common Carotid Artery, IC: Internal Carotid Artery, EC: External Carotid Artery, HU: Attenuation value Hounsfield Unit, Dr: Doctor

Table 3. Comparison of the subjective image quality scores of the radiologists

| | HDCT(N=18) | | | SDCT(N=21) | | |
|---|---|---|---|---|---|---|
| | Mean | Std. Error Mean | p | Mean | Std. Error Mean | p |
| Image quality dr1 | 4.11 | 0.14 | | 4.24 | 0.12 | 0.186 |
| Image quality dr2 | 4.11 | 0.14 | | 4.38 | 0.13 | |
| Carotid artery enhancement dr1 | 4.50 | 0.15 | 0.083 | 4.48 | 0.13 | 0.104 |
| Carotid artery enhancement dr2 | 4.67 | 0.11 | | 4.67 | 0.13 | |
| Absence of image noise dr1 | 4.44 | 0.12 | 0.43 | 4.38 | 0.11 | 0.329 |
| Absence of image noise dr2 | 4.56 | 0.15 | | 4.48 | 0.11 | |
| Absence of motion artifacts dr1 | 4.61 | 0.14 | | 4.57 | 0.11 | 0.186 |
| Absence of motion artifacts dr2 | 4.61 | 0.14 | | 4.71 | 0.1 | |

edges than did the SDCT images.

There were no significant or comparable differences between attenuation values (Table 2) or image quality, enhancement, artifact and noise scores in the subjective image quality assessment of HDCT and SDCT (Table 3).

## Discussion

The high definition CT technique was first designed for cardiac applications. Recently, high definition CTA of the carotid arteries has seen significantly more use in clinical practice [4,5]. From the introduction of 2-slice CT scanners through the first generation of 64-slice scanners, the main manufacturers of CT scanners offered products with similar technical specifications. However, over the past 5 years, CT hardware design has diverged, with fundamental differences among scanners in terms of the number of x-ray sources, detector geometry, and gantry rotation time [6,8]. Because of these significant advances in CT technology it is likely that future scanners will enable improved image quality under more robust conditions, more imaging applications, and lower doses of radiation. Technical progress has enabled the continued growth of cardiovascular CT and has expanded its diagnostic and prognostic benefits [7,8].

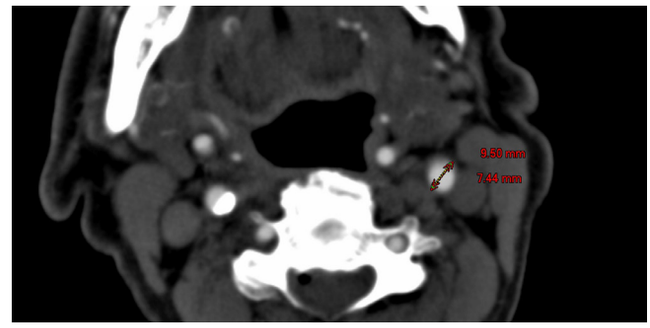


Figure 1. Carotid artery inner diameters measurement.

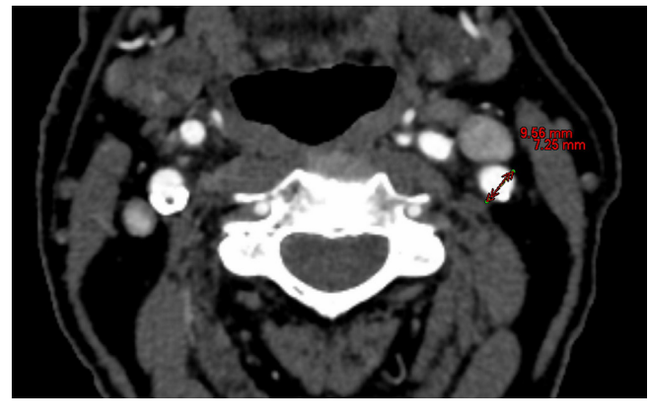


Figure 2. Carotid artery outher diameters measurement.

To our knowledge, this is one of a few studies comparing the standard and high definition CTA techniques designed for the evaluation of carotid arteries. We demonstrated that new high definition gemstone technology significantly improves quantitative image quality by increasing temporal resolution (4). In HDCT, one X-ray tube with a deflecting focal spot allows for a pitch of 3.2, which equals a table feed of 43 cm/s for gapless data acquisition. Because of a fast gantry rotation of 280 ms, high-speed volume coverage is accompanied by an in-plane temporal resolution of 75 ms [8].

We believe that high definition CTA has great promise in achieving more precise stenosis measurements at the carotid bifurcation in stroke patients. Also, a considerable asset to the high definition approach is its potential to view smaller parts, such as the intracranial portions of the internal carotid arteries.

HDCT for carotid artery measurements revealed good inter-observer agreement. However, only a satisfactory inter-observer agreement was achieved with SDCT. Vascular studies performed in the past have focused on stenosis. Because there are often edge definition artifacts in sharp transition zones and in areas with differing attenuation characteristics, which appear similar to the ringing artifacts, [9] we decided to make more precise evaluations, such as vessel wall thickness.

It is well known that unstable (or vulnerable) carotid plaques play a pivotal role in the pathogenesis of acute stroke due to local thrombus formation caused by plaque rupture or erosion [10]. Therefore, wall or plaque changes rather than the degree

of luminal narrowing may be more predictive of a patient's risk for further events. To our knowledge, this is the only study in which the wall thickness was evaluated, proving the feasibility of HDCT images in the carotid artery plaques and corresponding carotid wall changes in stroke patients. Consequently, it is clinically important to characterize the plaques, and it is especially important to identify unstable plaques, rather than detecting the degree of stenosis [11,12].

Results of this study indicate that there is a direct and strong correlation between the high definition images and the accuracy of the readers evaluating the wall changes. We believe that HDCT could be used as a more accurate assessment of the coronary plaques by demonstrating the corresponding luminal changes to the carotid artery wall. However, further studies based on a large cohort are needed to support our preliminary findings.

This study has several limitations. First, the emphasis of our design was on subjective and objective image quality. Secondly, the radiologists did not always measure the inner and outer diameters in the same axial plane. Although this is a preliminary study with a low number of patients, we believe these results are valuable for enhancing our understanding of the effect of different types of imaging technologies and subsequent measurement outcomes. We found a direct correlation between the types of CT and the evaluation of the carotid artery lumen. HDCT could serve as a complimentary tool to SDCT images for the detailed analysis of carotid lumen changes in relation to the plaque components, and therefore, would be valuable in identifying unstable or vulnerable plaques.

In summary, our findings are consistent with other reports reporting that high definition CT improves the image quality and quantity of carotid CTA.

### *Competing interests*

The authors declare that they have no competing interests.

**References**

1. Bayer-Karpinska A, Schwarz F, Wollenweber FA, Poppert H, Boeckh-Behrens T, Becker A et al. The carotid plaque imaging in acute stroke (CAPIAS) study: protocol and initial baseline data. BMC Neurol 2013;13:201. doi: 10.1186/1471-2377-13-201.

2. Menon B, Demchuk A. computed tomography angiography in the assessment of patients with stroke/TIA. Neurohospitalist 2011;1(4):187–99.

3. He C, Yang ZG, Chu ZG, Dong ZH, Shao H, Deng W et al. Arotid and cerebrovascular disease in symptomatic patients with type 2 diabetes: assessment of prevalence andplaque morphology by dual-source computed tomography angiography. Cardiovasc Diabetol 2010;9:91. doi: 10.1186/1475-2840-9-91.

4. Deng K, Zhang CQ, Li W, Wang JJ, Wang XY, Pang T et al. Preliminary application of high-definition CT Gemstone Spectral Imaging in hand and foot tendons. Korean J Radiol 2012;13(6):743-51.

5. Yang WJ, Chen KM, Pang LF, Guo Y, Li JY, Zhang H et al. High-definition computed tomography for coronary artery stent imaging: a phantom study. Korean J Radiol. 2012;13(1):20-6.

6. Sun Z, Choo G H, Ng K H. Coronary CT angiography: current status and continuing challenges. Br J Radiol 2012; 85(1013):495–510.

7. Jinzaki M, Tanami Y, Yamada M, Kuribayashi S. Progress and Current state of coronary CT. Ann Vasc Dis 2011;4(1): 7–18.

8. Halliburton S, Arbab-Zadeh A, Dey D, Einstein AJ, Gentry R, George RT et al. State-of-the-art in CT hardware and scan modes for cardiovascular CT. J Cardiovasc Comput Tomogr 2012;6(3):154-63.

9. Nelson RC, Feuerlein S, Boll DT. New iterative reconstruction techniques for cardiovascular computed tomography: how do they work, and what are the advantages and disadvantages? J Cardiovasc Comput Tomogr 2011;5(5):286–92.

10. Nandalur KR, Baskurt E, Hagspiel KD, Phillips CD, Kramer CM.Calcified carotid atherosclerotic plaque is associated less with ischemic symptoms than is noncalcified plaque on MDCT. Am J Roentgenol 2005;184(1):295-8.

11. Rozie S, de Weert TT, de Monyé C, Homburg PJ, Tanghe HL, Dippel DW et al. Atherosclerotic plaque volume and composition in symptomatic carotid arteries assessed with multidetector CT angiography; relationship with severity of stenosis and cardiovascular risk factors. Eur Radiol 2009;19(9):2294-301.

12. Biermann C, Tsiflikas I, Thomas C, Kasperek B, Heuschmid M, Claussen CD. Evaluation of Computer-Assisted Quantification of Carotid Artery Stenosis. J Digit Imaging 2012;25(2):250–7.