Case Report
JCAM

Petechial-Purpuric Rash, Leukopenia and Thrombocytopenia Associated Parvovirus B19

Parvovirus B19 İlişkili Peteşiyal-Pupurik Döküntü, Lökopeni ve Trombositopeni

Tugce Tural Kara, Halil Ozdemir, Ergin Ciftci, Erdal Ince
Çocuk Enfeksiyon Hastalıkları, Ankara Üniversitesi Tıp Fakültesi, Ankara, Türkiye

Özet

Parvovirus B19 makülopapüler, eritemli, peteşiyal veya purpurik lezyonlar gibi farklı deri döküntüleri neden olabilir. Ayrıca parvovirüsü B19 aplastik anemi, lökopeni, nötropeni ve trombositopeni gibi bazı önemli hematolojik bozukluklara neden olabilir. Biz peteşiyal-purpurik döküntüleri ile hastaneye başvuran bir çocuk olguyu sunduk. Laboratuvar analizinde lökopeni ve trombositopeni bulundu ve parvovirus B19 IgM serolojik testleri pozitif olduğu tespit edildi. Yatışının üçüncü gününden sonra, peteşiyal-purpurik döküntüleri gerilemeye başladı ve laboratuvar sonuçları normal aralığa geldi. Biz hastalığın parvovirus B19 enfeksiyonu olduğunu düşünüyoruz. Hastaya yanlızca ateş düşürücü ilaçlar verildi. Takibinde klinik ve laboratuvar bulguları tamamen iyileşti. Sonuç olarak; parvovirüs B19 peteşi ve purpura gibi bazı farklı klinik belirtiler neden olabilir. Ayrıca hematolojik bozukluklar da komplikasyon olarak görülebilir. Bu nedenle, döküntü, trombositopeni ve lökopenisi olan hastaların ayırıcı tanısında mutlaka düşünülmelidir.

Anahtar Kelimeler

Lökopeni; Parvovirüs B19; Döküntü; Trombositopeni

Abstract

Parvovirus B19 can cause different skin rashes like maculopapular, erythematous, petechial, or purpuric lesions. In addition, parvovirus B19 can cause some important hematologic disorders like aplastic anemia, leukopenia, neutropenia, and thrombocytopenia. We report a child who was admitted to the hospital with petechial-purpuric rashes. On laboratory analysis, leukopenia and thrombocytopenia were found and serologic testing of parvovirus B19 IgM was determined to be positive. After the third day of hospitalization, the petechial-purpuric rashes began to decline and laboratory results were in the normal range. We think that the disease was parvovirus B19 infection. The patient was treated with only antipyretic drugs. On follow up, the clinical and laboratory findings had completely returned to normal. In conclusion, parvovirus B19 can cause clinical signs such as petechiae and purpura. Also, hematologic disorders may be a complication. Because of this, it should be considered in the differential diagnosis in patients with rash, thrombocytopenia, and leukopenia.

Keywords

Leukopenia; Parvovirus B19; Rash; Thrombocytopenia

DOI: 10.4328/JCAM.4166 Received: 30.11.2015 Accepted: 01.01.2015 Printed: 01.05.2016 J Clin Anal Med 2016;7(3): 415-417
Corresponding Author: Tugce Tural Kara, Çocuk Enfeksiyon Hastalıkları, Ankara Üniversitesi Tıp Fakültesi, 06550, Dikimevi, Ankara, Türkiye.
T.: +90 3125956539 F.: +90 3123191440 E-Mail: tugcetural@hotmail.com

Introduction

Parvovirus B19 infection is common throughout the world. It has a wide spectrum of clinical findings. Although children may be asymptomatic during infection, nearly three-fourths of infected children have flu-like symptoms, malaise, fever, muscle pain, rashes, and arthralgias [1]. Children commonly do not require treatment; however if severe complications such as aplastic crisis, hydrops fetalis, arthropathy, or neurologic disorders occur, treatment will be lifesaving. Parvovirus B19 infection can cause skin rashes such as erythema infectiosum (fifth disease), and petechial and/or purpuric lesions. Papular-purpuric gloves and socks syndrome (PPGSS) has more commonly been reported in adolescents and adults [2]. In addition some hematologic disorders may be seen as a complication. Although parvovirus B19 targets the erythroid progenitor cells, virus associated leukopenia, neutropenia, and thrombocytopenia have been reported in the literature [3-6].

Here, we report a case with petechia-purpuric rash and low leukocyte and thrombocyte count due to parvovirus B19 infection.

Case Report

A 10-year-old girl was admitted to another hospital with petechial rash on her bilateral upper and lower extremities for 5 days. On laboratory evaluation, hemoglobin was 12.1 g/dL, white blood cell count was 3400/mm3, and thrombocyte count was 125000/mm³. She was consulted to our hospital because of the low leukocyte and thrombocyte count. The patient reported that both soles had started burning, swelling, and itching 6 days earlier. Headache, fever, and fatigue were noticed. A day later, the rashes spread to her face, hands, mouth, and trunk. Petechial-purpuric rashes were seen especially on her hands and feet, like glove and sock style (Fig. 1). Physical examination revealed blood pressure of 90/50 mmHg, pulse rate of 110/min, body temperature of 38.5 C°, and a respiratory rate of 28/min. Bilateral submandibular and cervical lymphadenopathy were localized; they were multiple and painful and the largest was 2x1 cm. In addition, petechiae on the hard palate and gingival hyperemia were found. Routine laboratory analysis revealed a hemoglobin level of 12.3 g/dL, white blood cell count of 3800/mm3 (neutrophils 61%, lymphocytes 30% and monocytes 9%), thrombocyte count of 150000/mm³, and a serum C-reactive protein level of 1.8 mg/L. Liver function tests, blood urea, and electrolytes were within normal range. In addition complement 3 and complement 4 levels were normal range. She did not receive any treatment except antipyretics during hospitalization. In order to determine the etiology of the petechial rash, cytomegalovirus (CMV) IgM and Epstein-Barr virus (EBV) IgM were tested and found to be negative. In addition, there were no etiological agents found by polymerase chain reaction (PCR) analysis of respiratory tract secretions. Blood cultures were negative. However, serologic testing of parvovirus B19 IgM was found to be positive and IgG was negative. Petechial-purpuric rashes began to decline on the third day of hospitalization. Thrombocyte and leukocyte counts increased day by day (Fig. 2, Fig 3).



Figure 1. Petechial purpuric rashes on the patient's foot

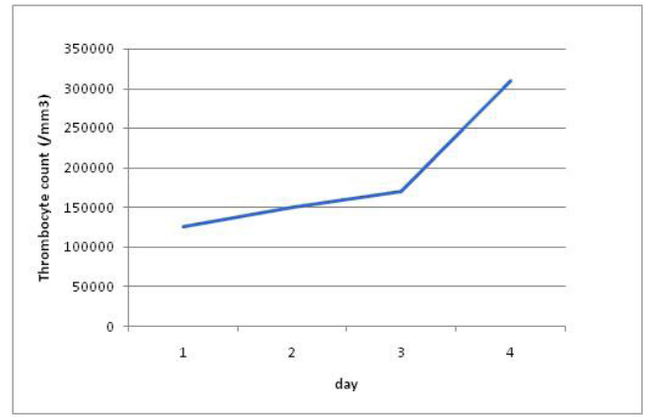

Figure 2. Thrombocyte count of the patient during hospitalization

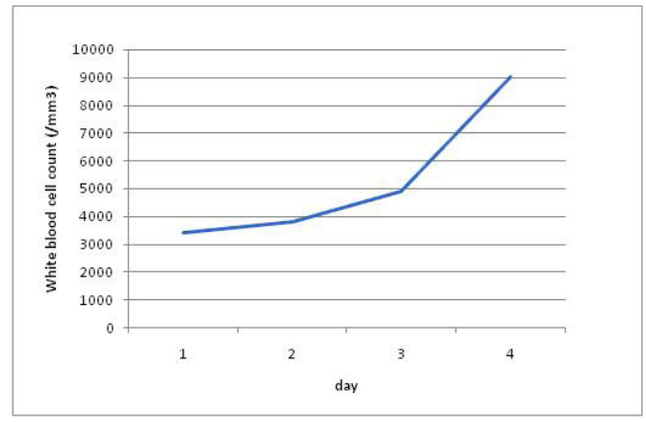

Figure 3. White blood count of the patient during hospitalization

Based on these findings, we believe that the disease was primary parvovirus infection. Because of this, the patient did not receive any treatment except antipyretics. After hospitalization the rashes decreased, laboratory examinations were found to be normal, hemoglobin was 11.8 g/dL, white blood cell count was 9000/mm3, and thrombocyte count was 309000/mm³. The patient recovered without complications.

Discussion

Acute parvovirus B19 causes nonspecific eruptions like polymorphous rash which is similar to many other diseases. Papular-purpuric gloves and socks syndrome (PPGSS), which is a clinic spectrum of parvovirus B19, is usually seen in the spring and summer. Parvovirus B19 is transmitted by respiratory secretions and saliva. When skin lesions appear, patients are more contagious. Petechial and/or purpuric lesions may be seen with edema and erythema on palms and soles [7].

There is a wide clinical spectrum of parvovirus B19 in the literature. Harms et al. first described PPGSS in 1990 [8]. Also reported is petechial purpuric eruption of parvovirus B19 infection (PAPPE), which is seen together with fever, artralgia, myalgia, and lymphanopathy. Our clinical case meets some of the criteria for PAPPE. However, trunk rash is the predominant occurrence in our case.

Parvovirus B19 can cause some hematologic disorders. Because the virus targets the erytropoetic progenitor cells in the human bone marrow, pure red cell aplasia may develop. However, parvovirus associated thrombocytopenia has been reported in the literature. Some studies suggest that viral nonstructural-1 proteins, which are cytotoxic to megakaryocytes, are responsible for thrombocytopenia [3,4]. In addition, P antigen was found on the megakaryocyte and it supported the cytotoxic effects of parvovirus B19 on the megakaryocyte [6].

Parvovirus associated neutropenia has also been reported. It is thought that direct invasion of the virus of hematopoietic progenitor cells and immune mediated destruction of the neutrophils are responsible for low leukocyte count. Viral DNA was detected from the circulating granulocytic cells. On the other hand, upon immunocytochemistry examination, parvovirus B19 capsid antigen was found on the granulocytic cells. [5,6]. Our patient was hospitalized during the viremic period of parvovirus B19 infection, as shown by fever, petechial-purpuric rash, low leukocyte, and trombocyte count.

Rash, edema, erythema, and fever are common symptoms of diseases such as Henoch–Schönlein purpura, vasculitis, enterovirus, adenovirus, meningococcus, EBV, CMV, rubella, rubeola, and varicella infectious. Epstein-Barr virus may cause some symptoms such as fever, malaise, nausea, chills, sore throat, posterior cervical lymphadenopathy, splenomegaly, and maculopapular rash in children. The rash usually involves the trunk, extremities, hands, and feet. In addition, CMV can cause the same symptoms. However, serologic testing of EBV and CMV was found to be negative in our patient. Meningococcal infections may cause petechial-purpuric rash, but they are necrotic and painful. Our patient did not have any necrotic rash. On the other hand, blood cultures were negative. Enteroviruses and adenovirus may cause fever and rash and therefore should be considered for differential diagnosis. Nevertheless, PCR analysis of respiratory tract secretion was detected to be negative. Henoch–Schönlein purpura and other vasculitis can also show purpuric rash but improvement is not possible in such a short period of treatment, whereas our patient recovered spontaneously within a few days.

Parvovirus infectious may cause a variety of clinical symptoms. It is important to consider parvovirus B19 infections when petechial-purpuric eruption, fever, artralgia, myalgia, lymphanopathy, thrombocytopenia, and leukopenia are detected. Although the disease is usually self-limiting, it should be kept in mind when diagnosing rash and hematologic disorders.

Competing interests

The authors declare that they have no competing interests.

References

1. Chorba T, Coccia P, Holman RC, Tattersall P, Anderson LJ, Sudman J, et al. The role of parvovirus B19 in aplastic crisis and erythema infectiosum (fifth disease). J Infect Dis 1986;154(3):383-93.
2. Gutermuth J, Nadas K, Zirbs M, Seifert F, Hein R, Ring J, et al. Papular-purpuric gloves and socks syndrome. Lancet 2011;378(9786):198.
3. Yoto Y, Kudoh T, Suzuki N, Katah S, Matsunaga Y, Chiba S. Thrombocytopenia induced by human parvovirus B19 infections. Eur J Haematol 1993;50(5):255-7.
4. Aktepe OC, Yetgin S, Olcay L, Özbek N. Human parvovirus B19 associated with idiopathic thrombocytopenic purpura. Pediatr Hematol Oncol 2004;21(5):421-6.
5. Istomin V, Sade E, Grossman Z, Rudich H, Sofer O, Hassin D. Agranulocytosis associated with parvovirus B19 infection in otherwise healty patients. Eur J Intern Med 2004;15(8):531-3.
6. Seo JY, Kim HK, Kim SH. Neutropenia in parvovirus B19-associated pure red cell aplasia. Ann Hematol 2011;90(8):975-8.
7. Santonja C, Nieto-González G, Santos-Briz Á, Gutiérrez Zufiaurre Mde L, Cerroni L, Kutzner H, et al. Immunohistochemical detection of parvovirus B19 in "gloves and socks" papular purpuric syndrome: direct evidence for viral endothelial involvement. Report of three cases and review of the literature. Am J Dermatopathol 2011;33(8):790-5.
8. Harms M, Feldmann R, Saraut JH. Papular-purpuric "gloves and socks" syndrome. J Am Acad Dermatol 1990;23(5):850-4.