Recurrent Sudden Sensorineural Hearing Loss in a Patient with Aortic Aneurysm

Aort Anevrizmalı Bir Hastada Tekrarlayan Ani İşitme Kaybı

SSNHL in a Patient with Aortic Aneurysm

M.Mustafa Kılıçkaya, Giray Aynali
Department of Otolaryngology, Medical Faculty of Suleyman Demirel University, Isparta, Turkey

Özet

Ani işitme kaybının (AİK) etyolojileri arasında viral enfeksiyonlar, embolizm, anevrizma ve vasküler olaylar gibi faktörler de bulunmaktadır. 63 yaşında, aort anevrizması cerrahisi ve hipertansiyon öyküsü olan bir hasta AİK şikayeti ile kliniğimize başvurdu. Medikal tedaviden sonra hasta tamamen iyileşti. Üç ay sonra başka bir AİK atağı ile gelen hastanın muayenesinde mikroembolizme sebep olabilecek aort anevrizmanın nüksettiği görüldü. Bu hastada Hiperbarik oksijen tedavisinin (HBOT) rölatif olarak riskli olması nedeniyle tedavi seçeneği olarak düşünülmedi. Ayrıca bu hastanın öncelikle aort anevrizmasından operasyon olması önerildiğinden dolayı AİK tedavisine ara verildi, ki bu durum kalıcı işitme kaybına sebep oldu. Sonuç olarak aort anevrizması, AİK' na neden olabilen ciddi bir hastalıktır ve bu hastalığın tedavi seçeneklerini kısıtlayabilir.

Anahtar Kelimeler

Ani İşitme Kaybı; Aort Anevrizması; Nüks

Abstract

Etiologies of sudden sensorineural hearing loss (SSNHL) include factors such as viral infections, embolism, aneurysm and vascular events. A 63-year-old male patient with a history of hypertension and aortic aneurysm surgery referred to our clinic with complaints of sensorineural hearing loss. The patient fully recovered after medical treatment. He had another SSNHL attack three months later; the examinations revealed the recurrence of the patient's aortic aneurysms, which suggested that the etiology might be the microembolism associated with aneurysm in that case. We did not consider hyperbaric oxygen treatment (HBOT) an option because it posed a relative risk for the patient. Additionally, as the patient underwent an operation primarily for aneurysm, the SSNHL treatment was interrupted, which resulted in permanent hearing loss. In conclusion, aortic aneurysm is a serious disease that may result in SSNHL, and that may affect the therapeutic options for treatment of SSNHL.

Keywords

Sudden Sensorineural Hearing Loss; Aortic Aneurysm; Recurrence

DOI: 10.4328/JCAM.4604 Received: 04.05.2016 Accepted: 16.05.2016 Printed: 01.09.2016 J Clin Anal Med 2016;7(5): 720-2
Corresponding Author: M.Mustafa Kiliçkaya, Department of Otolaryngology, Medical Faculty of Suleyman Demirel University, 32260 Isparta, Turkey.
T.: +90 2462119207 F.: +90 2462112832 E-Mail: drmmkilic@gmail.com

Introduction

SSNHL is an urgent disease with an annual prevalence rate of 1-2/10,000. It is characterized by a sensorineural hearing loss of 30 dB or higher at three subsequent frequencies over a period of three days. Although considered idiopathic, etiological factors include viral infections, autoimmunity, and ischemic-vascular events [1]. Arterial supply to the cochlea is mainly provided by the labyrinthine artery, which is thin and convoluted, with no collateral supply. This poses a risk of SSNHL development in ischemic events [2]. Arterial thrombosis is considered to be more harmful than venous thrombosis among the thrombotic risk factors in the pathogenesis. Cardiovascular risk factors (hypercoagulability, smoking, use of oral contraceptives, hypertension, etc.) are associated with poor prognosis [3]. Between 30-40% of patients with a history of SSNHL develop recurrent SSNHL.

Case Report

A 63-year-old male patient referred to the clinic with complaints of sudden hearing loss and tinnitus in the left ear. The patient's medical history indicated aortic aneurysm surgery 5-6 years previously, and hypertension, and due to use of antihypertensive and anticoagulant drugs. The audiological tests revealed 30 dB sensorineural hearing loss at 250, 500, and 1,000 Hz frequencies in the left ear (Figure 1). The patient was diagnosed with SSNHL and the treatment commenced immediately. Medical treatment included oral corticosteroid, piracetam, Vitamin B complex, and betahistine dihydrochloride. Corticosteroid treatment started at a low dose because of the the patient's hypertension history. The patient's hearing performance returned to a normal audiological range in three weeks and we suggested a follow-up (Figure 1).

However, after three months, the patient referred to the clinic again, this time with more severe hearing loss and tinnitus in the same ear (left). The audiological tests revealed 66 dB sensorineural hearing loss at 500, 1000, and 2000 Hz frequencies in the left ear (Figure 2). Middle ear pressure was normal for both ears in the tympanogram. The speech reception and speech discrimination thresholds were 75 dB and 45% (with masking) for the left ear, respectively. There were no pathological findings in the patient's temporal bone computed tomography. Medical treatment was started immediately. The patient received the same treatment; respective bone and air conduction (with masking) rates of 50 dB and 78 dB were found by audiogram 4 days later. We decided on HBOT as the patient suffered from severe hearing loss and was only slowly responding to the medical treatment.

We first requested cardiovascular surgery consultation to determine whether HBOT posed any risk for the patient, due to his history of aortic aneurysm surgery. The cardiologist reported recurrent aortic aneurysm and that the patient immediately needed another surgical operation; he was thus transferred. Thoracic computer tomography and angiography detected fusiform aneurysmal dilatation of approximately 62x60 mm in the ascending aorta, calcification of the aortic root, and calcified atheromatous plaques in the coronary arteries (Figure 3. a,b). The ecocardiographic findings indicated that the aortic diameter was 60 mm and located 3 cm above the aortic root, which implied aortic aneurysm and mitral valve failure.

Post-operative audiological tests were conducted about 3 months after the early stage of recurrent SSNHL. The tests revealed 53 dB sensorineural hearing loss at 500, 1000, and 2000 Hz frequencies and that the sensorineural hearing loss was permanent. (Figure 2).

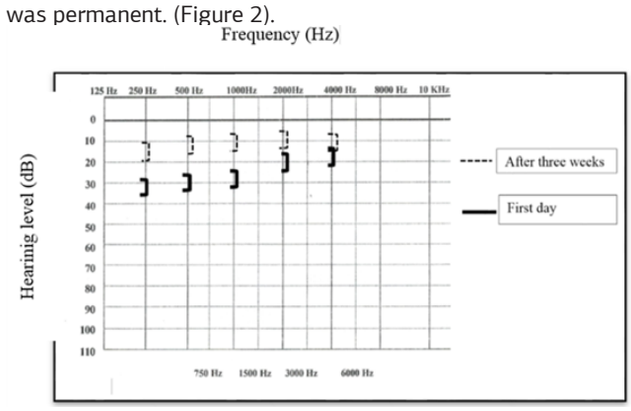

Figure 1. The audiogram of the patient in the first attack. Mild SSNHL in the left ear.

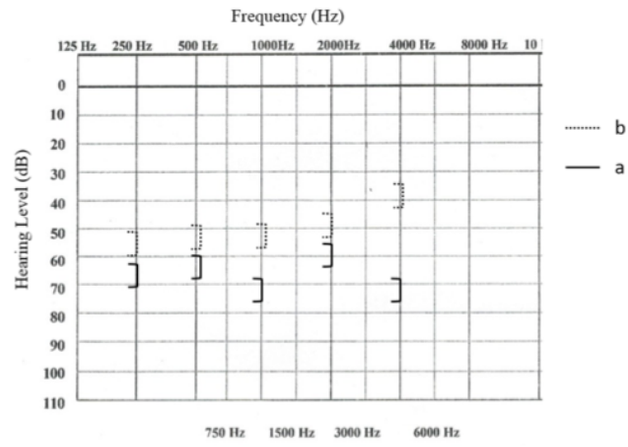

Figure 2. The first audiogram of the patient in the second attack. SSNHL in the left ear(a). The final audiogram of the patient in the second attack. Permanent SNHL in the left ear (b).

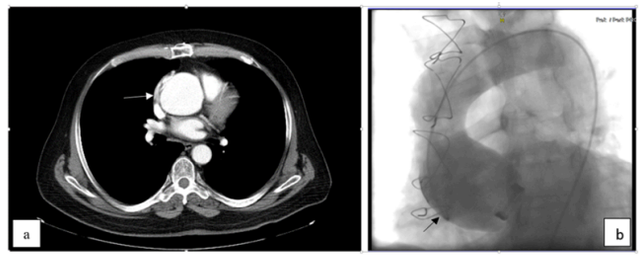

Figure 3. The fusiform aneurysmal dilatation of the ascending aorta (62x60mm). Thoracic computed tomography(a), Angiography(b).

Discussion

SSNHL is usually a unilateral phenomenon and may be associated with tinnitus and vertigo. Etiological factors of SSNHL include viral infections, vascular events such as embolism, neoplastic diseases, chronic myeloid leukemia, and demyelinating diseases causing demyelination in the cochlear nucleus and nerve [4]. Diseases such as vasospasm, hemorrhage, thrombosis, hypercoagulability, and microembolism are among the vascular causes of SSNHL [5]. SSNHL may develop after some non-otologic surgical operations with a prevalence rate of 1-1.8/1000. Microembolism is also considered among the etio-

pathogenetic factors triggering the disease.

Aortic mural thrombi are seen as the cause of arterial thromboembolism. Although they are largely caused by abdominal aorta, thoracic aorta is also a factor. Thoracic thromboembolism is observed in cases with atherosclerotic diseases and aneurysms. Mural thrombi in the aortic aneurysm may trigger macroembolism and microembolism, and they are the cause of arterial embolism [6]. In our case it is difficult to prove that SSNHL was caused by aortic aneurysm; however, the short interval recurrence of SSNHL suggests that it may have been due to microembolism. Approximately 30-60% of patients recover spontaneously in two weeks. Delayed treatment, severity of the hearing loss (particularly when it is above 50 dB), hearing loss at low frequencies, and the presence of vertigo are associated with poor prognosis [7]. In our case, the hearing loss was at low frequencies, more than 50 dB, but without vertigo.

As cochlear blood perfusion decrease is considered as an etiological factor of SSNHL, therapeutic options seek to increase this perfusion. Treatment includes various alternatives such as systemic corticosteroids, intratympanic steroid injection, vasodilator agents, stellate ganglion blockage, HBOT, and oral magnesium. Geriatric patients are known to be exposed to the risk of respiratory, cardiac, and vascular problems during HBOT. Moreover, as hyperoxia triggers hyperoxic vasoconstruction, it may cause hemodynamic changes including increased arterial pressure, bradycardia, decreased cardiac output, etc. HBOT is known to be contraindicated in acute severe bronchospasm and pneumothorax, and it is also reported to be contraindicated in patients with a history of thoracic surgery due to pneumothorax risk (yet no high risk) [8]. We considered it risky and thus avoided HBOT treatment in our case because the patient had a history of thoracic surgery, aortic aneurysm, and hypertension. Intratympanic steroid injection seemed more appropriate for a patient with these risk factors. However, with the surgeon recommending immediate surgical aneurysm repair, the patient underwent that operation first, and the SSNHL treatment was lower priority.

Conclusion

Given that microembolism is among the etiological factors of SSNHL, one should remember that severe diseases such as aortic aneurysm – a cause of microembolism – might be a comorbidity in the case of SSNHL. This represents a more serious condition for the patient and may influence therapeutic options for the SSNHL. One should also be careful because HBOT, a likely therapeutic choice, is relatively contraindicated in patients with cardiac diseases, pulmonary diseases, aneurysm, and other vascular diseases. Intratympanic steroid injection may be preferred over HBOT in such cases, as the former offers fewer systemic side effects.

Acknowledgement:

The authors declare no financial support. The manuscript is not being considered or reviewed by any other publication. This manuscript describes original work and the manuscript has not been published elsewhere. The manuscript contains no libelous or unlawful statements. All authors approved the manuscript and this submission. All authors of the manuscript have participated sufficiently in the conception and design of the work and in writing the manuscript, and they take public responsibility for it.

Competing interests

The authors declare that they have no competing interests.

References

1. Çelenk F, Bayramoğlu İ. Ani İşitme Kaybı. Turkiye Klinikleri Journal of Surgical Medical Sciences 2006;2(28):28-35.
2. Lovato A, Tormene D, Staffieri C, Breda S, Staffieri A, Marioni G. Sudden hearing loss followed by deep vein thrombosis and pulmonary embolism in a patient with factor V Leiden mutation. Int J Audiol 2014;53(9):625-8.
3. Passamonti SM, Di Berardino F, Bucciarelli P, Berto V, Artoni A, Gianniello F et al. Risk factors for idiopathic sudden sensorineural hearing loss and their association with clinical outcome. Thromb Res 2015;135(3):508-12.
4. Schreiber BE, Agrup C, Haskard DO, Luxon LM. Sudden sensorineural hearing loss. Lancet 2010;375(9721):1203-11.
5. Capaccio P, Ottaviani F, Cuccarini V, Bottero A, Schindler A, Cesana BM, et al. Genetic and acquired prothrombotic risk factors and sudden hearing loss. Laryngoscope 2007;117(3):547-51.
6. Roche-Nagle G, Wooster D, Oreopoulos G. Symptomatic thoracic aorta mural thrombus. Vascular 2010;18(1):41-4.
7. Belhassen S, Saliba I. Intratympanic steroid injection as a salvage treatment for sudden sensorineural hearing loss. J Laryngol Otol 2014;128(12):1044-9.
8. D. Mathieu. Physiology and Medicine of Hyperbaric Oxygen Therapy: Contraindications to Hyperbaric Oxygen Therapy, First Edition. Saunders: An imprint of Elsevier Inc 2008.p.587-98.

How to cite this article:
Kılıçkaya MM, Aynali G. Recurrent Sudden Sensorineural Hearing Loss in a Patient with Aortic Aneurysm. J Clin Anal Med 2016;7(5): 720-2.