Case Report
JCAM

Morgagni Hernia: Presentation of 3 Cases and A Short Review of the Literature

Morgagni Hernisi: Üç Vakanın Sunumu ve Literatürün Kısaca Gözden Geçirilmesi

Morgagni Hernia in Childhood

Mervan Bekdas[1], Hulya Ozturk[2]
[1]Department of Pediatrics, [2]Department of Pediatric Surgery, Abant Izzet Baysal University Faculty of Medicine, Bolu, Turkey

Özet

Morgagni hernisi, diafragma hernisinin nadir bir tipidir. Genellikle sağda görülür. Çoğunlukla akciğer grafisi ile tanısı konulur. Bu çalışmada amacımız Morgagni hernisindeki deneyimlerimizi sunarak bu tablonun erken tanı ve tedavisine katkıda bulunmaktır. Olgularımızın iki tanesi solunum sistemi semptomları ile başvuruken, bir tanesi asemptomatik idi. Bir tanesinin tanısı sadece akciğer grafisi ile konuldu, diğer iki tanesinin ayırıcı tanısı için akciğer tomografisi gerekli oldu. Herni her üç olguda sağ tarafta idi ve hepsine cerrahi tedavi uygulandı. Vakaların hiçbirinde postop morbidite veya mortalite saptanmadı.

Anahtar Kelimeler

Morgagni Hernisi; Solunum Sistemi Semptomu; Görüntüleme Yöntemi; Çocuk

Abstract

Morgagni hernia is a rare type of diaphragm hernia, generally seen on the right side. Diagnosis usually requires chest X-rays. In this study, we aim to share our experience with Morgagni hernia cases to contribute to its early diagnosis and treatment. Among our cases, 2 were admitted with respiratory symptoms while one of the cases was asymptomatic. In one of the cases the disease was diagnosed merely with chest X-ray, but in the other 2 cases thorax computerized tomography was required for differential diagnosis. The hernias were on the right side in all 3 cases and surgical interventions were performed in all of them. Postoperative morbidity or mortality was not observed in these cases.

Keywords

Morgagni Hernia; Respiratory Symptom; Imaging Method; Child

DOI: 10.4328/JCAM.4641 Received: 20.05.2016 Accepted: 09.06.2016 Printed: 01.09.2016 J Clin Anal Med 2016;7(5): 733-6
Corresponding Author: Mervan Bekdas, Department of Pediatrics, Abant Izzet Baysal University Faculty of Medicine, Bolu, Turkey.
T.: +903742534656 E-Mail:merbek14@yahoo.com

Introduction

Congenital diaphragm hernia is a condition characterized by the entrance of intra-abdominal organs to the thoracic cavity due to an anatomical defect of the diaphragm. This idiopathic condition is reported in 1/ 2000-4000 live births [1]. It is more often seen in females [2]. About 95% of these hernias are reported in the lateral region. Morgagni hernias are determined in only 3% of cases of congenital diaphragm hernia [3]. The main problem in Morgagni hernia arises from aborted development of the sternal and costal parts of the diaphragm and the concomitant insufficient connections between these parts [4]. Another cause of the development of these hernias is believed to be the increased intraabdominal pressure due to recurrent vomiting and cough attacks [5]. About 90% of these hernias are on the right side, while 8% are on the left side, and 2% are bilateral. In the thoracic cavity, the omentum and/or transverse colon are commonly herniated [6] and rarely the liver, small intestine, and stomach [7-9]. The diagnosis of Morgagni hernia is generally delayed. Sometimes the cases are admitted with some acute clinical symptoms such as acute volvulus or respiratory distress, but in 50-70% of cases the patients are diagnosed incidentally during investigations for non-specific respiratory or gastrointestinal symptoms [10]. These hernias are more commonly identified in adults than in children because herniation is facilitated by risk factors such as abdominal trauma, morbid obesity, and pregnancy, more commonly seen in adults. Additionally, enlargement of the hernia sac leads to the progression of symptoms [11,12].

An interesting feature of Morgagni hernia is that in 34-50% of cases, it accompanies other abnormalities such as Down, Turner, or Noonan syndromes, Cantrell pentalogy, pectus deformities, intestinal malrotation, or genitourinary malformations [13]. In a large series, Morgagni hernia was reported with Down syndrome in approximately 20% of cases [14,15].

In this study, we aim to share our experience with Morgagni hernia cases to contribute to its early diagnosis and treatment.

Case Report 1

A boy, 3 years and 3 months old, was admitted to our outpatient clinic with fever and cough that had lasted for 1 week. Although he had been admitted to another center previously, his symptoms were continuing despite treatment. Results of his physical examination were: body temperature of 37 °C, arterial blood pressure of 100/70 mmHg, and a respiratory rate of 42/min with a heart rate of 138/min. In auscultation, there were crackles on mid parts of the right hemothorax while other system examinations were normal. The blood leucocyte count was 13300/mm³, the hemoglobin level was 10.3 g/dl, and all other routine blood tests were within normal ranges. The postero-anterior chest X-ray revealed a consolidation area on the right paracardiac region. A diagnosis of pneumonia was made and100 mg/kg ceftriaxone iv treatment was started. On the 5th day of treatment, in a control chest X-ray, an appearance with septations was found (Figure 1). The thorax computerized tomography revealed that there was a Morgagni hernia sac on the right anterior part of the heart containing transverse colon, and, secondary to this formation, the heart was deviated to the left causing compression atelectasis on neighboring lung parenchyma (Figure 2). Traditional open abdominal surgery was performed without any complication. Control chest X-rays showed no abnormality.



Figure 1. Chest X-ray of the first case (View of consolidation area on the right paracardiac region)

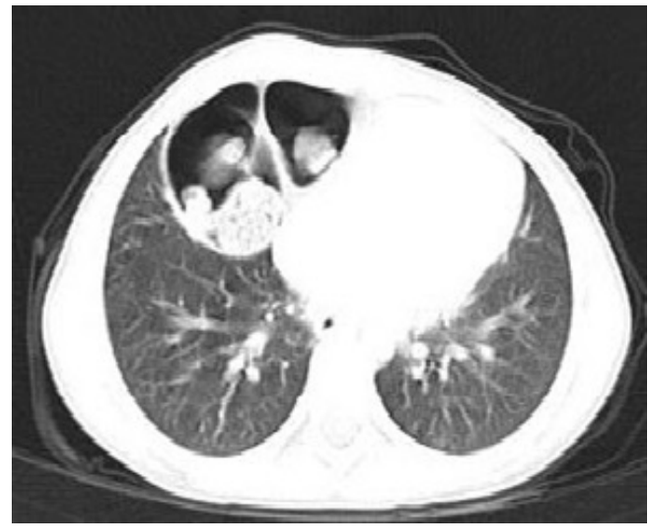

Figure 2. Thorax tomography of the first case (View of sac containing transverse colon on the right anterior of the heart; the heart was deviated to the left causing compression atelectasis)

Case Report 2

A 16-month-old girl was admitted to our hospital with the complaint of a cough that had continued for 3 months. In a physical examination her body temperature was 37.1 °C, arterial blood pressure was 90/65 mmHg, and her respiratory rate was 48/min with a heart rate of 124/min. Her lung and all other systemic examinations were normal. The laboratory examination revealed a leucocyte count of 14900/mm³ and a hemoglobin level of 12.4 g/dl, while other routine laboratory tests were within normal limits. In a postero-anterior chest X-ray, opacity on the right paracardiac region was detected. In thorax computerized tomography, a Morgagni hernia sac containing transverse colon on the right anterior part of the heart (Figure 3) was found. Traditional open abdominal surgery was performed without any complication. Control chest X-rays showed no abnormality.



Figure 3. Thorax tomography of the second case (View of sac containing transverse colon on the right anterior of the heart)

Case Report 3

A 21-month-old girl was admitted to our hospital with the complaint of dysmorphic face appearance and the inability to extend the interphalangeal joints of her hand. In physical examination, her body temperature was 37 °C, arterial blood pressure was 80/60 mmHg, and her respiratory rate was 27/min with a heart rate of 105/min. All systemic examinations were normal including auscultation of the lungs. Her leucocyte count was 9800/mm³ and hemoglobin level was 11.9 g/dl while other routine laboratory tests were within normal limits. A postero-anterior chest X-ray revealed an appearance compatible with a hernia on the right paracardiac region (Figure 4). Traditional open abdominal surgery was performed without any complication. Control chest X-rays showed no abnormality.

Discussion

Morgagni hernia may be seen in all age groups including the newborn period, but diagnosis is often made incidentally [10].



Figure 4: Chest X-ray of the third case (View of sac on the right paracardiac region)

The clinical findings of the condition are generally associated with the size of the hernia sac. In patients with large-sized defects, respiratory symptoms are commonly seen due to the compression on the lungs. A sunken abdomen, the presence of abdominal sounds on the thorax, or cyanosis may be other findings in those cases. Patients with small-sized defects are generally asymptomatic and diagnosis is made incidentally [13]. One of the 3 cases reported here was asymptomatic while the other 2 cases presented with respiratory symptoms.

In patients with these clinical findings, chest X-ray is sufficient for the diagnosis of Morgagni hernia [16]; the diagnosis can be achieved by postero-anterior and especially lateral graphs in many of the cases. In those graphs, suspicious density on the cardiophrenic angle, air-fluid levels on the paracardiac region, or intestinal loops on the thorax may be identified [17]. If there is doubt about the diagnosis, computerized tomography of the thorax is the most appropriate diagnostic tool, with 100% sensitivity. Moreover, it is also helpful to differentiate Morgagni hernia from mass lesions with fatty or vascular patterns [17]. Sometimes ultrasonography, magnetic resonance imaging, or contrast enhanced investigations of the gastrointestinal tract may also be required for diagnosis [18]. However, radiological investigations other than the chest X-ray are not performed in routine practice. Nevertheless, doctors today, for liability protection, should use additional imaging methods to confirm diagnosis during the preoperative period [19]. In one of our cases, the hernia was diagnosed with a chest X-ray, while in 2 of our cases computerized tomography of the thorax was required for the differential diagnosis of the mass lesion identified on the right cardiophrenic angle by chest X-ray.

The treatment of asymptomatic Morgagni hernia is controversial. Although some authors recommend that the treatment is not necessary, others advise treatment of all cases to prevent the development of complications such as acute gastrointestinal system obstruction, incarceration, strangulation, or volvulus [20]. The generally accepted opinion is to perform surgical treatment of symptomatic patients. Surgical repair may be performed with open surgery by abdominal or thoracic approaches [15]. In all of our cases, open surgical interventions were performed by the abdominal approach and no complications were determined. In patients with a history of abdominal operations, the thoracic approach may be more appropriate. But in patients with the suspicion of gangrene in the intestinal loops, open surgical interventions with abdominal approach are advised [21]. It is also controversial to expulse the hernia sac in surgical treatment. Although some authors advise not to remove the hernia sac since this may cause pericardial or pleural perforations [6], others oppose this idea due to the possibility of recurrences or cyst formation by leaving it in the thoracic cavity [22]. In all of our cases, after reduction of the colonic segments from the hernia sac, plication of the sac was performed with separated suture.

Another treatment method is laparoscopic surgery. The laparoscopic method is preferred in the treatment of Morgagni hernia because it permits a smaller incision and allows faster recovery [23]. This method was not used in our patients due to the our surgical team's lack of experience with this procedure and the lack of the requisite medical equipment in our hospital.

Morbidity and mortality generally depends on the presence of compressions of the hernia sac, pulmonary hypoplasia, and pulmonary hypertension [24]. Morbidity or mortality was not observed in any of our cases.

In conclusion, Morgagni hernia cases may be symptomatic or asymptomatic. In differential diagnosis of children with respiratory system symptoms unresponsive to treatment, Morgagni hernia should be kept in mind. A postero-anterior chest X-ray is often enough for the diagnosis, but in cases of differential diagnosis where there is some doubt, advanced radiological methods may be required. Although the surgical treatment of asymptomatic cases is controversial, we recommend surgical treatment to prevent possible complications.

Competing interests

The authors declare that they have no competing interests.

How to cite this article:
Bekdas M, Ozturk H. Morgagni Hernia: Presentation of 3 Cases and A Short Review of the Literature. J Clin Anal Med 2016;7(5): 733-6.

References

1. Doyle NM, Lally KP. The CDH Study Group and advances in the clinical care of the patient with congenital diaphragmatic hernia. Semin Perinatol 2004;28:174–84.
2. Akar E. Retrospective Evaluation of Patients with Morgagni Hernia. J Clin Anal Med 2012;3(3):331-3.
3. Khandelwal S, Oelschlager BK. Video. Laparoscopic repair of congenital bilateral Morgagni hernia. Surg Endosc 2011;25:2010.
4. Mallick MS, Alqahtani A. Laparascopic-assisted repair of Morgagni hernia in children. J Pediatr Surg 2009;44:1621-4.
5. Al-Salem A. Congenital hernia of Morgagni in infants and children. J Pediatr Surg 2007;42:1539-43.
6. Akbıyık F, Tiryaki TH, Şenel E, Mambet E, Livanelioğlu Z, Atayurt H. Is hernial sac removal necessary? Retrospective evaluation of eight patients with Morgagni hernia in 5 years. Pediatr Surg Int 2006;22:825-30.
7. Kuster GGR, Kline LE, Garzo G. Diaphragmatic hernia through the foramen of Morgagni: laparoscopic repair case report. J Laparoendosc Surg 1992;2(2):93-100.
8. Newman L, Eubanks S, Bridges M, Lucas G. Laparoscopic diagnosis and treatment of Morgagni hernia. Surg Laparosc Endosc 1995;5:27-31.
9. Vinard JL, Palayodan A, Collomb P. Emergency laparoscopic treatment of a strangulated Morgagni hernia. Eur J Coeliosurg 1997;1:35-40.
10. Minneci PC, Deans KJ, Kim P, Mathisen DJ. Foramen of Morgagni hernia: changes in diagnosis and treatment. Ann Thorac Surg 2004;77:1956-9.
11. Federico JA, Ponn RB. Foramen of Morgagni hernia. In Shields TW, LoCicero III J, Ponn RB (eds): General Thoracic Surgery. Philadelphia, Lippincott Williams & Wilkins, 2000.p.647-50.
12. Colakoglu O, Haciyanli M, Soyturk M, Colakoglu G, Simsek I. Morgagni hernia in a adult: Atypical presentation and diagnostic difficulties. Turk J Gastronterol 2005;16(2):114-6.
13. Pokorney WJ, McGill CW, Herberg FJ. Morgagni hernia during infancy: presentation and associated anomalies. J Pediatr Surg 1984;19:394-7.
14. Çiğdem MK, Önen A, Okur H, Otçu S. Associated malformations in Morgagni hernia. Pediatr Surg Int 2007;23:1101-3.
15. Al-Salem AH, Nawaz A, Matta H, Jacobs A. Herniation through the foramen of Morgagni: early diagnosis and treatment. Pediatr Surg Int 2002;18:93-7.
16. Abraham V, Myla Y, Verghese S, Chandran BS. Morgagni-Larrey Hernia- a Review of 20 Cases. Indian J Surg 2012;74(5):391-5.
17. Eren S, Ciris F. Diaphragmatic hernia: diagnostic approaches with review of the literature. Eur J Radiol 2005;54:448-59.
18. Zaleska-Dorobisz U, Bagłaj M, Sokołowska B, Ładogórska J, Moroń K. Late presenting diaphragmatic hernia: clinical and diagnostic aspects. Med Sci Monit 2007;13(Suppl 1):137-46.
19. Durakbasa CU, Mutus M, Tosyalı AN, Sehiraltı V, Masrabacı K, Okur H. Hernia of Morgagni: experience of a pediatric surgical clinic. Çocuk Cerrahisi Dergisi 2007;21(3):139-43.
20. Pfannschmidt J, Hoffmann H, Dienemann H. Morgagni hernia in adults: result in 7 patients. Scand J Surg 2004;93(1):77-81.
21. Kurkcuoglu IC, Eroglu A, Karaoglanouglu N, Polat P, Balik AA, Tekinbas C. Diagnosis and surgical treatment of Morgagni hernia: report of three cases. Surg Today 2003;33(7):525-8.
22. Rau HG, Schardey HM, Lange V. Laparoscopic repair of a Morgagni hernia. Surg Endosc 1994;8:1439-44.
23. Shah SR, Wishnew J, Barsness K, Gaines BA, Potoka DA, Gittes GK, Kane TD. Minimally invasive congenital diaphragmatic hernia repair: a 7-year review of one institution's experience. Surg Endosc 2009;23:1265-71.
24. van Loenhout RB, Tibboel D, Post M, Keijzer R. Congenital Diaphragmatic Hernia: Comparison of Animal Models and Relevance to the Human Situation. Neonatology 2009;96(3):137-49.