An interesting view of the trachea and main bronchi as if it is drawn with a pencil: Tracheobronchopathia osteochondroplastica

Trakea ve Ana Bronşların Sanki Kalemle Çizilmiş Gibi İlginç Bir Görüntüsü: Tracheobronchopathia Osteochondroplastica

Tracheobronchopathia

M.Fatih Erkoç[1], Halil İbrahim Serin[1], Bayram Metin[2]
[1]Department of Radiology, [2]Department of Thorasic Surgery, Bozok University Medical Faculty, Yozgat, Türkiye

A 62 year old nonsmoker man presented with increasing shortness of breath, wheeze, dry cough and multiple episodes of hemoptysis from past 5 years. His clinical examination and multiple chest X-rays taken over the years were normal. Spirometry revealed a mild obstructive airway disease but bronchoscopy was not performed as the patient did not give consent for the procedure. The CT scan that lead to the diagnosis in our patient showed deformed, thickened and narrowed tracheal wall. There were irregular spaced 1-3 mm calcific submucosal nodules of trachea and the main bronchi extending to small airways which were similar to plaque. Tracheobronchopathia osteochondroplastica is a rare benign disorder with unknown etiology, characterized by the presence of subepithelial osteo cartilaginous nodules projecting into the tracheobronchial lumen. Recently, disease has subdivided as tuberosa (degenerative changes with nodule formation and ossification) and peripherica (diffuse degeneration of the trachea which is almost exclusively only found during autopsy) according to the type of tracheal ossification and nodule formation. Cough not responding to usual medical treatment, recurrent hemoptysis and breathlessness are the most common symptoms. The treatment of this disease is unknown as it cannot be confirmed by a major control study because of the rarity of the disease. If there is localized disease, possible resection of the affected area may be attempted but most common chose is medical treatment .The patient was discharged with symptomatic treatment and was asked to follow up within 6 months period.

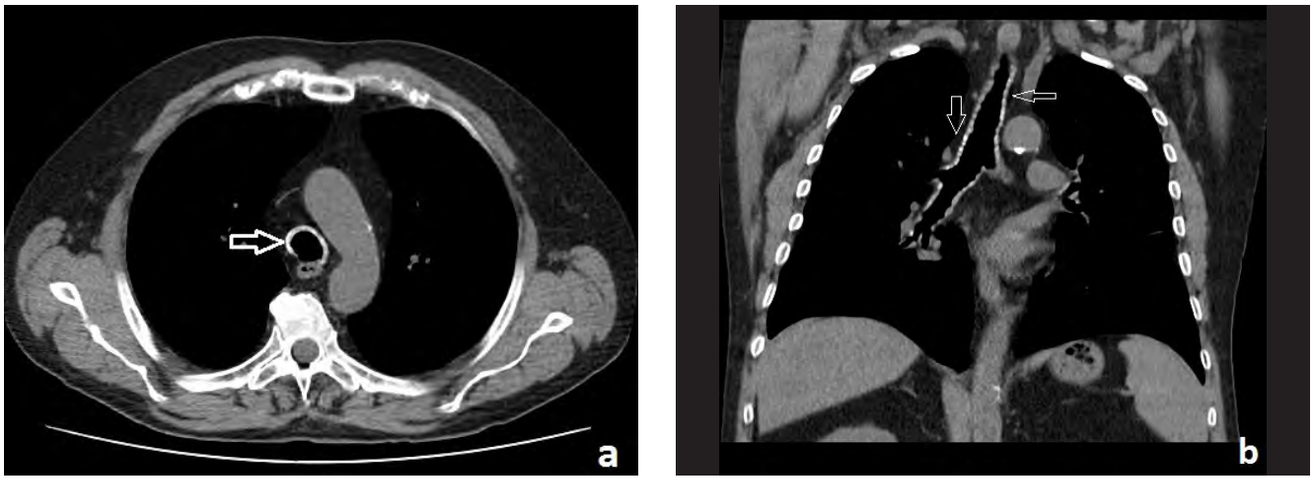

Figure 1. Axial (a) and coronal (b) views of high resolution CT thorax showing calcification and submucosal nodular pattern (arrows) along the trachea and major bronchi.

DOI: 10.4328/JCAM.2715 Received: 10.08.2014 Accepted: 19.08.2014 Printed: 01.02.2016
Corresponding Author: Mustafa Fatih Erkoç, Bozok University Medical Faculty, Department of Radiology, 66200, Yozgat, Turkey.
GSM: +905326977932 E-Mail: drerkoc@gmail.com