Massive Abdominal Wall Hematoma Due to Low Moleculer Weight Heparine

Düşük Molekül Ağırlıklı Heparine Bağlı Masif Abdominal Duvar Hematomu

Hematoma due to Enoxaparine

Suleyman Deniz, Gokhan Inangil
Department of Anesthesiology, Gulhane Military Medical Academy, Haydarpasha Training Hospital, Istanbul, Turkey

Low moleculer weight heparin (LMWH) is commonly used for prophylaxis against deep venous thrombosis [1, 2]. But these medications can lead injection site complications like abdominal wall hematoma rarely [3]. The risk of bleeding may increase in elderly population especially when the length of stay in intensive care unit (ICU) increases [4]. We report a case with massive abdominal wall hematoma that needed transfusion due to LMWH. 49 year old woman (108 kg 1.68 m with BMI: 38) was admitted ICU after postoperative menengioma surgery with score of Glaskow Coma Score 4. On 30th day 6000 IU/0,6 enoxaparine sodium was planned for deep venous trombosis prophylaxis. On the 136th day of her ICU stay her abdomen was slightly distended with echymosis and her haemoglobin level decreased rapidly to 6.2 from 8.9. Platelet count were 157,000/µL. With physical examination large enduration area with dimensions 12x14 cm noted (Figure 1). Ultrasonography of abdominal wall with curved array probe (5-2 MHz Sonosite M-Turbo C60x transducer) showed a large partially organised hematoma 6.58 x 5.45 cm (Figure 2). 2 U of erithrocytes suspension and 2 U of fresh frozen plasma planned.



Figure 1. The hematoma external appearance

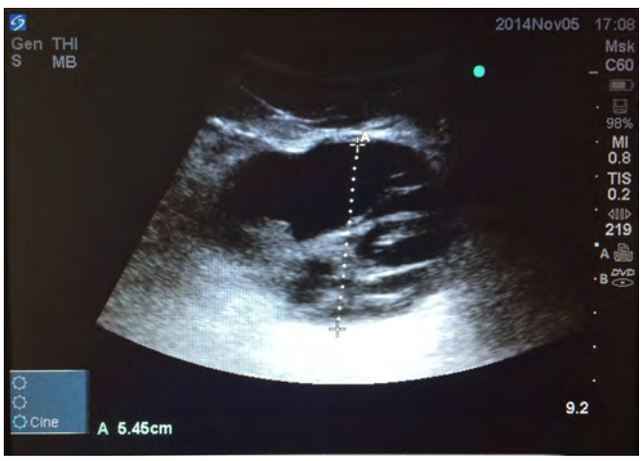

Figure 2. The hematoma ultrasonographic appearance

References

1. Şimşek E. Çalışkan A, Soran B, Tütün U. A complication that can be faced after embolectomy: drug caused coagulation problem. J Clin Anal Med 2013; DOI: 10.4328/JCAM.2123
2. Antonelli D, Fares L II, Anene C. Enoxaparin associated with huge abdominal wall hematomas: A report of two cases. Am Surg 2000;66(8):797-800.
3. Mir T, Layliev J, Glickman LT. Massive spontaneous hematoma from chronic enoxaparin (Lovenox) use. Plast Reconstr Surg 2010;126(4):209e-10e.
4. Kayrak M, Bacaksiz A, Yazici M. Is enoxaparin injection from the abdominal wall safe in elderly people?: a fatal case of rectus sheath hematoma. Can Fam Physician 2008;54(9):1246-8.

DOI: 10.4328/JCAM.3310 Received: 11.02.2015 Accepted: 18.02.2015 Printed: 01.02.2016
Corresponding Author: Suleyman Deniz, Department of Anesthesiology, Gulhane Military Medical Academy, Haydarpasha Training Hospital, Istanbul, Turkey.
GSM: +905366542540 E-Mail: sdeniz.md@gmail.com