Cervical Ectopic Thymic Tissue with Parathyroid Elements Mimicking Papillary Carcinoma Metastasis

Papiller Karsinom Metastazını Taklit Eden Servikal Ektopik Timus Dokusu İçindeki Paratiroid Dokusu

Esra Karakuş[1], Müjdem Nur Azılı[2], Atilla Şenaylı[2]
[1]Ankara Çocuk Sağlığı ve Hastalıkları, [2]Çocuk Cerrahisi,
Hematoloji Onkoloji Eğitim ve Araştırma Hastanesi, Ankara, Türkiye

To the editor:

A 16 year-old female patient was presented with a cervical mass and pain. An ultrasound imaging detected hypoechoic nodules and calcifications at the right and left thyroid lobe. Preoperative blood examples were within the normal limits, except for autoantibodies (TgAb, TPOAb and TrAb). The nodule at the lower pole of the middle part of the right thyroid lobe was aspirated with a single pass using a 22-gauge needle. Fine needle aspiration biopsy performed on the left lesion revealed cellular, three-dimensional and papillary groups. Some of these groups showed follicular organization. The cells had voluminous, pleomorphic nuclei with rough chromatin. Pseudoinclusions were extensive and some nuclei had prominent nucleoli. Foamy macrophages and mature lymphocytes were sparsely seen in the background. The patient underwent bilateral total thyroidectomy. Thyroidectomy specimen was totally 14x9x4 cm in size. Both the macroscopic and the hematoxylin and eosin–stained sections of the right and left thyroid lobe showed a papillary thyroid microcarcinoma (PTMC) (Figure 1A). Nuclear features frequently observed were optically clear nuclei, nuclear grooves, chromatin clumping and nuclear crowding (Figure 1B). Additionally, sections of material sent from the patient revealed cervical ectopic thymus tissue. Biopsy of the lymph node revealed well-delineated servical thymic tissue composed of lobular lymphoepithelial components and interspersed Hassall's corpuscles. These findings were in support of ectopic thymus rather than lymph node. No histological features of lymph nodal tissue was present. Multiple sections studied from the lesion showed foci of parathyroid gland tissue consisting entirely of chief cells with eosinophilic cytoplasm that mimicking metastasis of papiller carcinoma (Figure 1C). We further performed immunohistochemical staining. Clusters of

DOI: 10.4328/JCAM.3327 Received: 18.02.2015 Accepted: 07.04.2015 Printed: 01.02.2016
Corresponding Author: Esra Karakuş, Ankara Çocuk Sağlığı ve Hastalıkları, Hematoloji Onkoloji Eğitim ve Araştırma Hastanesi, Dışkapı, Ankara, Türkiye.
T.: +90 3125969746 GSM: +905071636748 F.: +90 3123472330 E-Mail: esrakaraku@gmail.com

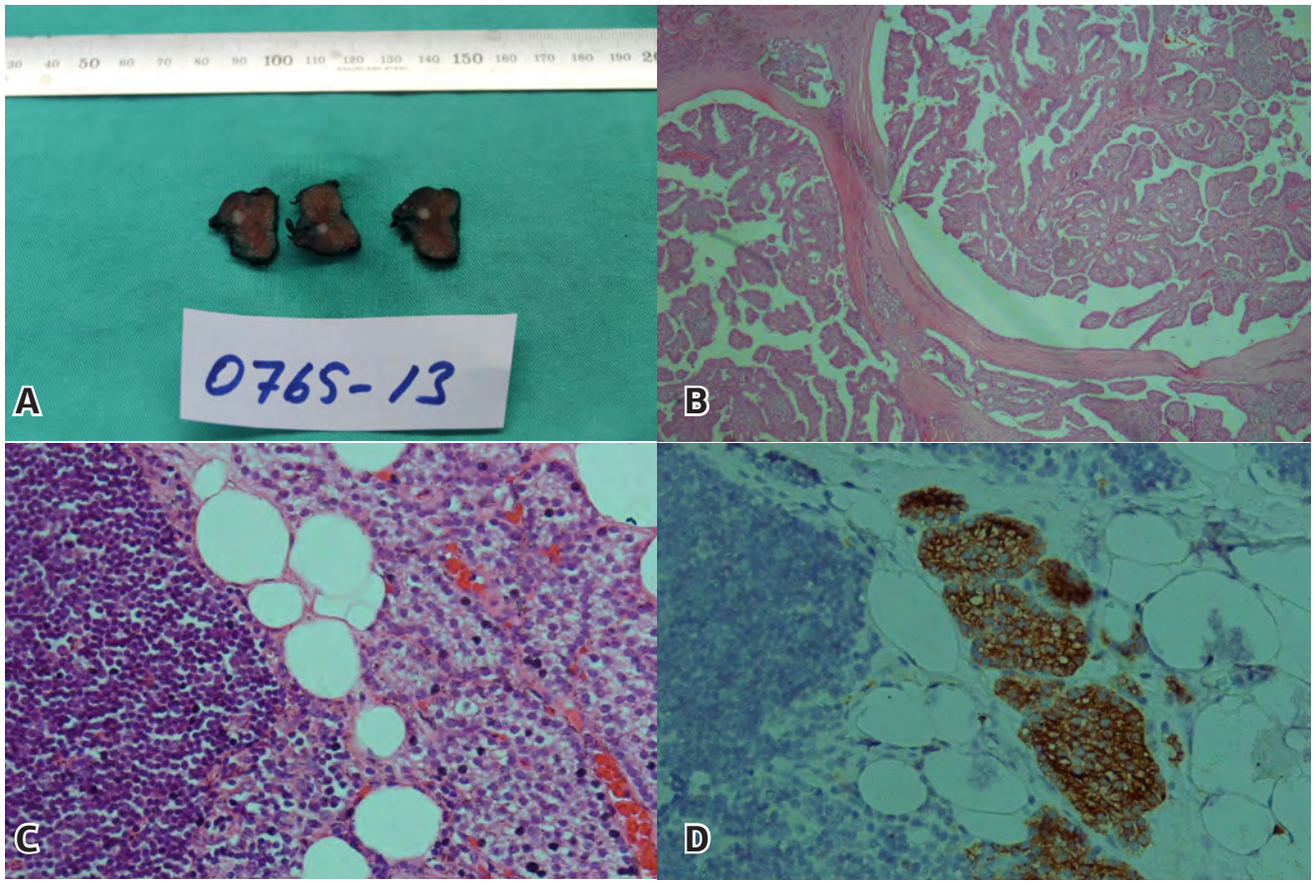

Figure 1. Surgical specimen showing solid nodule of whitish and homogeneous aspect. (A). Papillary thyroid carcinoma (PTC) is composed of delicate papillae lined by malignant cells (H&E, X100) (B). Parathyroid gland tissue consisting entirely of chief cells with eosinophilic cytoplasm that mimicking metastasis of papiller carcinoma (H&E, X400) (C). Clusters of uniform cuboidal epithelial chief cells showed strong and diffuse immunohistochemical staining for parathyroid hormone (parathyroid hormone, X400) (D).

uniform cuboidal epithelial chief cells showed strong and diffuse immunohistochemical staining for parathyroid hormone (Figure 1D). Based on these findings, the diagnosis for lymph nodal material of ectopic thymic tissue with parathyroid element was established. There were no postoperative complications.

Papillary thyroid microcarcinomas, as a specific subgroup of PTC an have a very favorable prognosis. Papillary microcarcinoma is increasing in incidence among young adults. They are regarded as low risk tumours [1, 2].

Cervical ectopic thymic tissue (CET) is an common embryological anomaly but CETs can not be diagnosed preoperatively. Congenital malformations of the neck may develop although with a low incidence, accounting for about 0.5 to 1% [3,4]. In conclusion, cervical ectopic thymic tissue with parathyroid elements is extremely rare. They can be misdiagnosed as metastasis if immunohistochemistry is not performed.

References

1. Noguchi S, Yamashita H, Uchino S, Watanabe S. Papillary microcarcinoma. World J Surg 2008;32:747-53.

2. Chow SM, Law SC, Chan JK, Au SK, Yau S, Lau WH. Papillary microcarcinoma of the thyroid-Prognostic significance of lymph node metastasis and multifocality. Cancer 2003;98:31-20.

3. Thomas B, Shroff M, Forte V, Blaser S, James A. Revisiting imaging features and the embryologic basis of third and fourth branchial anomalies. Am J Neuroradiol 2010;31:755-60.

4. Batuecas Caletrío A, Blanco Pérez P, Santa Cruz Ruiz S, Serradilla López JM,González Sánchez M, Moreno Jiménez D, Benito González F, Muñoz Herrera A.Persistence of the third branchial arch. Acta Otorrinolaringol Esp 2006;57:193-5.