Bleeding Caecal Angiodysplasia Diagnosed by CT-Angiography

BT-Anjiografi İle Tanı Konan Kanamalı Çekal Anjiyodisplazi

Caecal Angiodysplasia

Murat Özgür Kılıç[1], Gürkan Değirmencioğlu[1], Yeliz Kılıç[2]
[1]Department of General Surgery, Faculty of Medicine, Turgut Özal University,
[2]Clinic of Anesthesiology and Reanimation, Dr. Abdurrahman Yurtaslan Oncology Training and Research Hospital, Ankara, Turkey

A 71-year old male patient was admitted to ER because of active rectal hemorrhage. At admission, only low haemoglobin level (8.3 g/dl) was found within laboratory tests. He had no history of gastrointestinal (GI) bleeding. His physical examination was unremarkable, and no abnormality was detected on digital rectal examination. Upper GI endoscopy was also normal. Colonoscopy failed due to gross blood. Computed tomography (CT)-angiography detected a bleeding submucosal vascular ectatic area, 16 mm in size, at the medial wall of the caecum (Figure 1A, B). Since the bleeding did not stop by angiographic intervention, right hemicolectomy was performed. Histopathology demonstrated dilated submucosal vessels with mild dysplasia, consistent with angiodysplasia. He was discharged without any problem on seventh day.

Vascular lesions are common causes of lower GI bleeding, and can be classified into different subtypes, including angiodysplasia, arteriovenous malformation, and vascular ectasia. Among those, angiodysplasia is generally seen in elderly patients, and can cause both occult and massive lower GI bleeding. It may also be asymptomatic, and can incidentally found at screening colonoscopy [1]. Although the bleeding ceases spontaneously in the vast majority of cases [2], some patients need endoscopic, angiographic, or surgical interventions due to non-stopping or recurrent bleeding. In case of failure of endoscopic and angiographic interventions, surgery should be performed immediately.

In conclusion, angiodysplasia is an infrequent cause of lower GI bleeding, and requires timely diagnostic and therapeutic interventions. Treatment of these lesions should be individualized depending on severity of disease, and a multidiciplinary approach should be required for best outcomes.

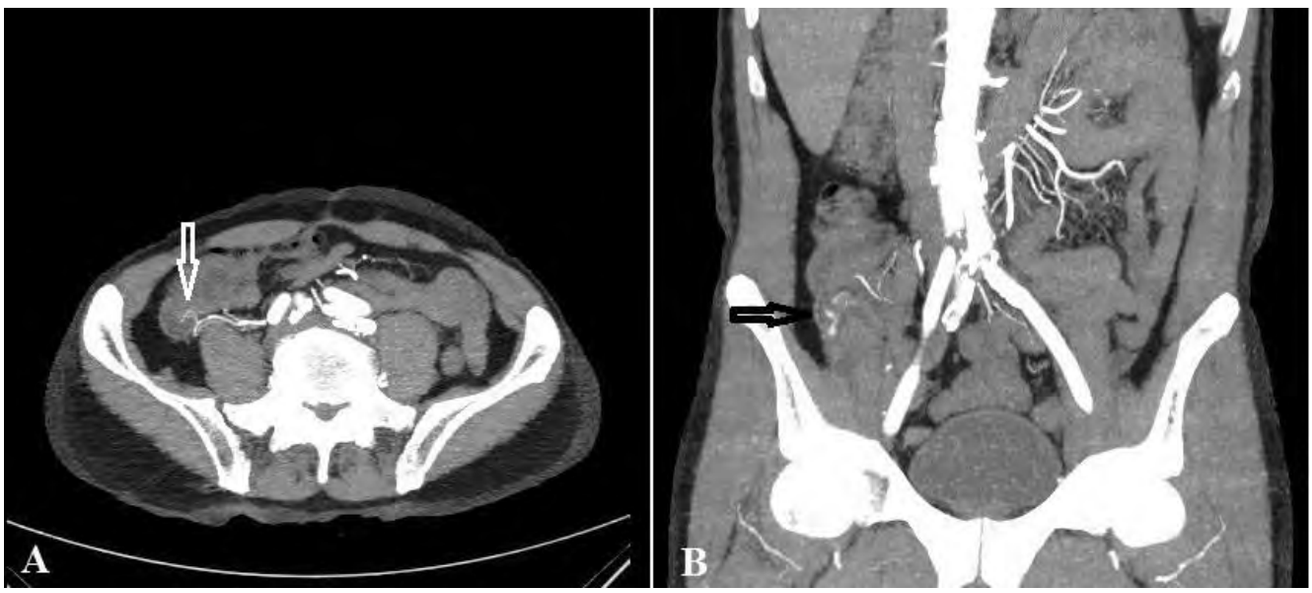

Figure 1A, B. The bleeding caecal angiodysplasia on two images (A, B) of CT-angiography (arrows show the lesion located at the medial wall of the caecum)

References

1. Regular J, Wronsca E, Pachlewiski J. Vascular lesions of the gastrointestinal tract. Best Pract Res Clin Gastroenterol 2008;22(2):313-28.
2. Hoedema RE, Luchtefeld MA. The management of lower gastrointestinal hemorrhage. Dis Colon Rectum 2005;48(11):2010-24.

DOI: 10.4328/JCAM.3824 Received: 07.08.2015 Accepted: 27.08.2015 Printed: 01.02.2016
Corresponding Author: Murat Özgür Kılıç, Department of General Surgery, Turgut Özal University, Ankara, Turkey.
GSM: +905053573122 E-Mail: murat05ozgur@hotmail.com