A Sail-like Glass Piece into the Cervical Esophagus

Servikal Özofagusta Yelkene Benzeyen Cam Parçası

Glass into the Esophagus

Murat Öncel, Güven Sadi Sunam, Hüseyin Yıldıran
Göğüs Cerrahisi A.D., Selçuk Üniversitesi Tıp Fakültesi, Konya, Türkiye

The esophageal foreign bodies have importance because they have serious morbidity and mortality by esophageal perforation [1]. 25 -year-old male patient with mental retardation who had history of convulsions since the age of 5 years, admitted the emergency department by discomfort in the throat. About 4 hours ago, as he was drinking coke by the glass, the glass had broken and he felt dysphagia. In physical examination, the patient's extremities and facial muscles in neck had spasticity, he had no orientation and his cooperation was limited. Examinations of his oropharynx was unremarkable and he had hypersalivation. The glass piece was shown by radiological imaging located at cervical part of esophagus (Figure 1). The rigid esophagoscopy was performed and the glass piece was removed by Magill forceps (Figure 2). Esophageal mucosa was intacted. Postoperatively, the patient was relieved of the discomfort swallowing , and could accept both solid and liquid foods orally. He was discharged 24 hours later. The treatment depends on the clinical status of patient and type of foreign body. Endoscopy is the most common and safe procedure. However, the foreign bodies at the first narrow of esophagus can be removed by Magill forceps [2]. If the foreign body can not be removed by endoscopy or esophageal perforation occurs, surgery should be planned.

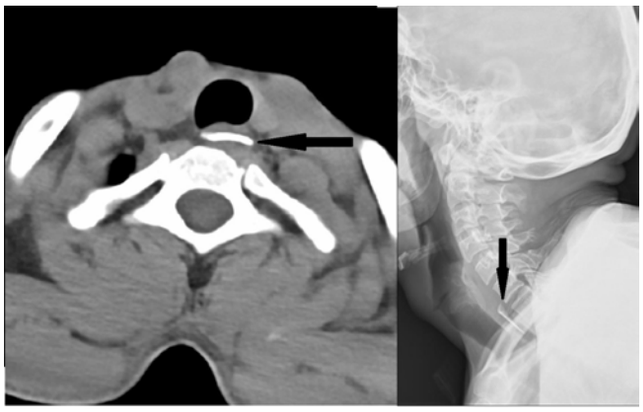

Figure 1. Radiological imaging of the piece of glass in computed tomography and X-ray



Figure 2. The piece of glass

References
1. Metin B, Öncel M, Yıldırım Ş, Tözüm H. Esophagial Foreign Body in Children. Archives Medical Review Journal 2014;23(2):186-96.
2. Bao W-K. Study of Foreign-Body Extraction from the Upper Third of the Esophagus in Children. Iranian Journal of Pediatrics 2014;24(2):214-8.

DOI: 10.4328/JCAM.3852 Received: 23.08.2015 Accepted: 13.09.2015 Printed: 01.02.2016
Corresponding Author: Murat Öncel, Göğüs Cerrahisi A.D. Selçuk Üniversitesi Tıp Fakültesi, Alaeddin Keykubat Kampüsü, Selçuklu, Konya, Türkiye.
T.: +90 3322243929 E-Mail: moncel01@hotmail.com