Original Image
JCAM

A Very Rare Cause of Chronic Back Pain: L1 Hemivertebra

Kronik Bel Ağrısının Oldukça Nadir Bir Nedeni: L1 Hemivertebra

Chronic Back Pain

Ramazan Aydin[1], Gulten Aydin[2]
[1]Clinic of Radiology, Kirikkale High Speciality Hospital, [2]Department of Pathology, Kirikkale University Faculty of Medicine, Turkey

A 49-year-old man presented to the hospital with many years history of back pain. He went to many hospitals during this period. None of the hospitals performed a radiologic examination. He used many non-steroidal anti-inflammatory drugs, but he did not heal. The neurologic examination was normal. A magnetic resonance imaging revealed L1 hemivertebra compression to the thecal sac and spinal cord (Fig. 1). After this diagnosis, the patient was operated and hemivertebra was excised. After one year follow up the patient did not have back pain.

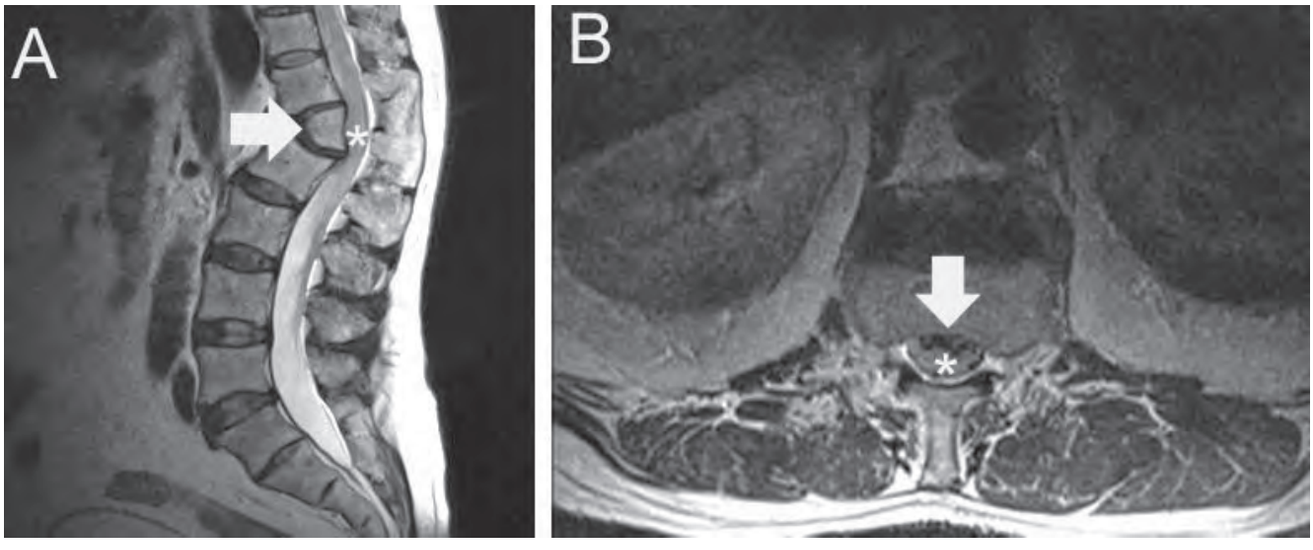

Figure 1. A T2 weighted sagittal (A) and axial (B) magnetic resonance images revealed L1 hemivertebra (arrow) compression to the thecal sac and spinal cord (asterisk).

DOI: 10.4328/JCAM.4197 Received: 10.12.2015 Accepted: 22.12.2015 Printed: 01.02.2016
Corresponding Author: Ramazan Aydin, Clinic of Radiology, Kirikkale High Speciality, Kırıkkale, Turkey.
E-Mail: mdramazan@hotmail.com