Cutaneous Metastasis of Large Cell Lung Cancer: A Case Report

Büyük Hücreli Akciğer Kanserinin Cilt Metastazları: Olgu Sunumu

Cutaneous Metastasis

İsmail Ertuğrul Gedik[1], Timuçin Alar[1], Aslı Muratlı[2]
[1]Göğüs Cerrahisi Anabilim Dalı, [2]Patoloji Anabilim Dalı, Onsekiz Mart Üniversitesi Tıp Fakültesi, Çanakkale, Türkiye

Özet

Akciğer kanseri dünya genelinde yıllık insidansı en fazla olan kanser türüdür. Cilt, akciğer kanserinin metastaz yaptığı nadir organlardan biri olup insidansının %1 ile %12 arasında değişiklik gösterdiği bildirilmiştir. Bu makalede 67 yaşında yaklaşık 2 aydır vücudunun çeşitli bölgelerinde şişlik yakınmalarıyla başvurduğu hekim tarafından çekilen akciğer grafisi sonrası, sağ üst zonda yaklaşık 3 cm çaplı homojen dansite artışı saptanması nedeniyle hastanemizin iç hastalıkları polikliniğine başvuran ve sonrasında tarafımıza konsülte edilen bir erkek olgu sunuldu. Özgeçmişinde 80 paket/yıl sigara içtiği öğrenilen hastanın yapılan fizik muayenesinde vücudunun çeşitli bölgelerinde çok sayıda deri lezyonu saptandı. Sağ 6. interkostal aralık ile orta aksiller hat kesişim yerindeki yaklaşık 1,5x1 cm' lik cilt nodülü gerekli hazırlıkları takiben lokal anestezi altında bütün olarak eksize edildi ve patoloji laboratuvarına gönderildi. Patoloji raporunda "büyük hücreli nöroendokrin karsinom" olarak tanısı konuldu ve başka bir odak saptanmaması sonucu akciğerin büyük hücreli karsinomunun uzak metastazı olarak kabul edildi. İnoperabl olarak değerlendirilen hasta onkoloji polikliniğine yönlendirildi.

Anahtar Kelimeler

Deri Metastazı; Akciğer Kanseri; Büyük Hücreli Kanser

Abstract

Lung cancer has the highest incidence among all cancer types in the world. Skin is an uncommon organ that lung cancers metastasize and the incidence of cutaneous metastasis has been reported between 1-12%. In this report, we would like to present the case of a 67 year old male patient who admitted to our hospital with the complaint of multiple swollen masses on the different parts of his skin and has a homogenous mass with the width of 3 cm on chest x ray. The nodule at the intersection of the right 6th intercostal space and the mid-axillary line and with the dimensions of 1.5x1 cm was excised under local anesthesia and the specimen was sent to the pathology laboratory for histopathological examination. The diagnosis of "large cell neuroendocrine carcinoma" was made histopathologically. The patient was diagnosed as the distant metastasis of the large cell lung cancer, considered inoperable and referred to oncology clinics.

Keywords

Lung Neoplasms; Skin Metastasis; Carcinoma, Large Cell

DOI: 10.4328/JCAM.1689 Received: 22.02.2013 Accepted: 22.03.2013 Printed: 01.04.2016 J Clin Anal Med 2016;7(suppl 2): 96-8
Corresponding Author: İsmail Ertuğrul Gedik, Göğüs Cerrahisi Anabilim Dalı, Çanakkale Onsekiz Mart Üniversitesi Tıp Fakültesi, Çanakkale, Türkiye.
T.: +90 2862635950-1050-1129 GSM: +905323313067 F.:+90 2862635957

Introduction

Lung cancer has the highest incidence among all cancer types in the world [1]. Skin is an uncommon organ that lung cancers metastasize and the incidence of cutaneous metastasis has been reported between 1-12% [2]. These metastasis can present themselves to the physician as painless subcutaneous or intramuscular masses that erode the tissues above and become chronic cutaneous ulcers. In this report, we would like to present the case of patient that was diagnosed as the cutaneous metastasis of the large cell lung cancer without the risks of the open biopsy techniques and emphasize the importance of a thorough physical examination including the cutaneous system.

Case Report

A 67 year old male patient admitted to our hospital after admitting to another physician with the complaint of multiple swollen masses on the different parts of his skin and has a homogenous mass with the width of 3 cm on chest x ray. In the past medical history he had an 80 packs/year of smoking and in the physical examination there were multiple, hard and immobile subcutaneous nodules at suprapubical area, left suprascapular area, the intersection of the right 6th intercostal space with the mid-axillary line, and left upper quadrant of the abdomen with the dimensions of 3x2 cm, 5x4 cm, 1.5x1 cm and 1x1 cm respectively (Figure 1). Respiratory system examination revealed



Figure 1. Subcutaneous nodule at the left upper quadrant of the abdomen.

bilateral softened breath sounds. Cervical, supraclavicular and axillary lymph node examinations revealed no lymphadenopathies. Thoracic computerized tomography (CT) was performed and revealed a mass in the posterior segment of the right upper lobe with the dimensions of 4x3 cm and multiple subcutaneous nodules (Figure 2). Patient was hospitalized to the thoracic surgery clinics for taking excisional biopsy from one of his cutaneous lesions. After making the necessary preparations for the surgery, the nodule that was localized at the intersection of the right 6th intercostal space and the mid-axillary line and with the dimensions of 1.5x1 cm was excised under local anesthesia and the specimen was sent to the pathology laboratory for histopathological examination. Immunohistochemical stains of cytokeratin 7 (CK7, Thermo Scientific®), CK20 (Genemed®), epithelial membrane antigen (EMA, Dako), thyroid transcription factor 1 (TTF1, Dako®), synaptophysin (Thermo Scientific®), chromogranin (Genemed®), pankeratin (Thermo Scientific®), high molecular weight cytokeratin (HMWCK, Genemed®) and

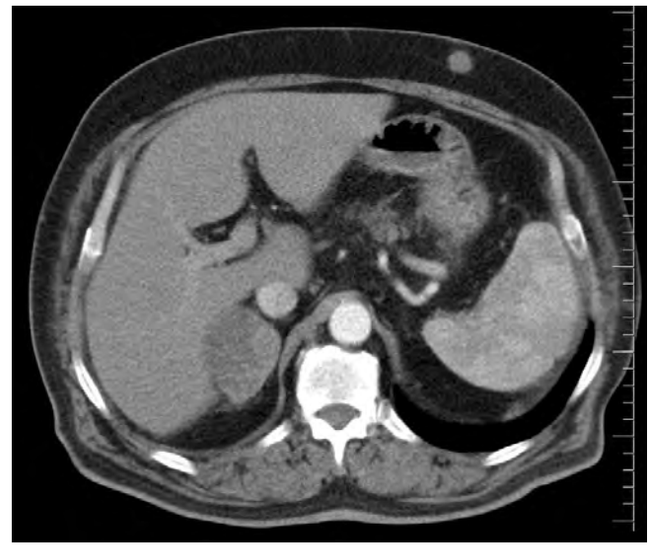

Figure 2. CT section of the subcutaneous nodule at the intersection of the right 6th intercostal space with the mid-axillary line with dimensions of 1.5x1 cm.

tumor protein 63 (p63, Dako®) were tested. Immunohistochemical stains were performed via the automatic immune staining machine (Leica-Bondmax®). The slides were evaluated at a light microscope (Carl Zeiss Axioscope® Photomicroscope) and photographs were taken with an onboard camera system (Carl Zeiss Axiocam ICc3® 3.3 Mp digital camera and Carl Zeiss Axiovision Software®). A tumor that was formed of groups of cells with organoid and trabecular pattern, which includes many atypical mitoses and large necrotic areas, was found in the histopathological examination. Strongly positive immune staining with Pankeratin, EMA, TTF1, CK7 and weakly positive immune staning with synaptophysin and chromogranin. The staining pattern of pankeratin was diffuse not dot-like. There was no immune staining with CK20, p63 and HMWCK (Figure 3). Basaloid type squamous cell carcinoma was eliminated with HMWCK

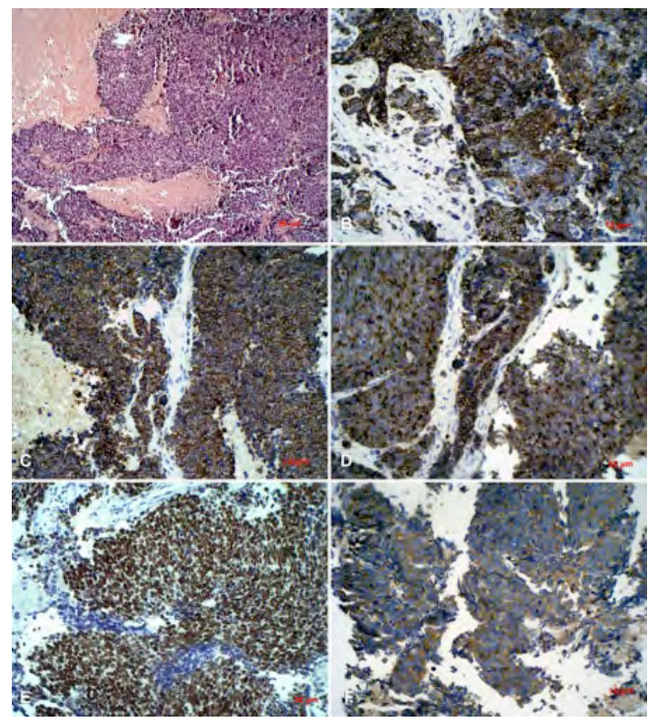

Figure 3. Picture A: Tumor with large necrotic areas that is composed of large cells with hyperchromatic nuclei (HEx100), Immunohistochemical stains: B: CK7 positivity (x200), C: Pankeratin positivity (x200) D:EMA positivity (x200), E:TTF1 positivity (x200), F: sinaptofizin positivity (x200).

and p63 negativity. The diagnosis of "large cell neuroendocrine carcinoma" was reported when histopathological findings were considered along with immunohistochemical findings. TTF1 can also be expressed in extrapulmonary tumors such as thyroid, bladder and prostate along with lungs. The primary pulmonary malignancy was considered in our patient since there was no other focus of malignancy. Patient was discharged on the same day because his postoperative reexamination revealed no abnormalities. The patient was diagnosed as the distant metastasis of the large cell lung cancer. He was considered inoperable and referred to oncology clinics.

Discussion

Cutaneous metastasis of lung cancer was reported more frequently in men than women [2,3,4]. Especially in obese patients subcutaneous nodules are thought of benign origin such as lipomas as in the case of our patient and usually neglected. Cutaneous metastasis, which is rarely seen in lung cancer, can be undiagnosed and thus advanced stage diseases are underrated and unnecessary thoracic surgeries are performed. Several studies indicate that adenocarcinoma of the lung is the most common type of lung cancer that metastasize to skin. But it is also emphasized in other studies that large cell cancer has a higher tendency to metastasize to skin than other types of lung cancer despite the fact that it is a less frequently seen type of lung cancer [2,3]. The cutaneous nodules of our patient that were excised was reported as "metastasis of large cell carcinoma" with histopathological examination. The cutaneous metastasis of the lung cancer was reported to be frequently localized at the head and neck region, thorax and abdomen [4]. Cutaneous nodules were found at the neck, thorax and abdomen of our patient. He also had a nodule at the inguinal region.

The expected mean survival time in a patient with cutaneous metastasis of any cancer type is 6.5 months. But it is reported as low as 2.9 months in cutaneous metastasis of lung cancer [5]. Lung cancer with skin metastasis is considered as inoperable because of these facts. Chemotherapy, radiotherapy or the combination of these two entities can be the treatment of choice in patients with skin metastasis. But despite these treatments achieving complete remission is usually not possible [6]. Biopsy methods can vary according to their level of invasiveness from the trans-thoracic fine needle aspiration biopsy to the biopsies taken via thoracotomy may cause a lot of complications in patients especially with short life expectancies such as lung cancer with cutaneous metastasis. Complications like pneumothorax, hemothorax and hemorrhage will compromise the general condition of the patient and delay the necessary treatments such as chemo-radiotherapy. Physical examination must be thorough and consist of all systems in the body because of these possible complications. Finding a suspicious skin nodule, which can easily be undiagnosed during the physical examination, can prevent unnecessary biopsy operations. But the most important thing in these kinds of situations is performing an unnecessary operation to the patient because of an undiagnosed skin metastasis. Preventing this big mistake can be prevented by a thorough physical examination.

In conclusion, a thorough physical examination should be performed in a patient with an intensive smoking history and cutaneous metastasis of the lung cancer should be suspected if early onset skin nodules are found in the dermatological examination.

Competing interests

The authors declare that they have no competing interests.

References

1. Ferlay J, Shin HR, Bray F, Forman D, Mathers C, Parkin DM. Estimates of worldwide burden of cancer in 2008: GLOBOCAN 2008. Int J Cancer 2010;127:2893–917.
2. Mollet TW, Garcia CA, Koester G. Skin metastasis from lung cancer. Dermatol Online J 2009;15: 1.
3. Hidaka T, Ishii Y, Kitamura S. Clinical features of skin metastasis. Intern Med 1996;35:459-62.
4. Kamble R, Kumar L, Kochupillai V, Sharma A, Sandhoo MS, Mohanti BK. Cutaneous metastases of lung cancer. Postgrad Med J 1995;71:741-3.
5. Schoenlaub P, Sarraux A, Grosshans E, Heid E, Cribier B. Survival after cutaneous metastasis: a study of 200 cases. Ann Dermatol Vereneol 2001;128:1310-15.
6. Lookingbill DP, Spangler N, Helm KF. Cutaneous metastases in patients with metastatic carcinoma: a retrospective study of 4020 patients. J Am Acad Dermatol 1993; 29:228-36.

How to cite this article:
Gedik İE, Alar T, Muratlı A. Cutaneous Metastasis of Large Cell Lung Cancer: A Case Report. J Clin Anal Med 2016;7(suppl 2): 96-8.