Case Report
JCAM

Ischemic Changes in a Case of Unilateral Pseudoexfoliation Syndrome

Tek Taraflı Psödoeksfoliasyon Sendromlu bir Olguda İskemik Değişiklikler

Ischemic Changes in Pseudoexfoliation Syndrome

Tolga Kocaturk[1], Isıl Isıklıgil[1], Volkan Dayanir[1], Yelda Ozsunar[2], Harun Cakmak[1]
[1]Department of Ophthalmology, [2]Department of Radiology, Adnan Menderes University Medical School, Aydin, Turkey

Özet

66 yaşında, glokomatöz görme alanı kayıplarını taklit eden, normotansif, tek taraflı psödoeksfoliasyon sendromlu bir erkek hasta sunulmaktadır. Hastada, tek taraflı belirgin iskeminin eşlik ettiği retinal sinir lifi tabakasında incelme ve ardışık görme alanlarında nazal adım defektleri vardı. Klinik olarak psödoeksfoliasyonun görüldüğü sol gözde, optik disk görünümü glokomatöz çukurlaşmayı desteklemese de; sağ göze göre daha soluk ve retinal damarlar daralmış görünümdeydi. Sol oftalmik arterin renkli Doppler görüntülemesinde, rezistivite indeksinin 0.88 gibi oldukça yüksek bir değerde olduğu görüldü. Olgu, psödoeksfoliasyonun oküler iskeminin bir sebebi olduğunu belirten yeni literatür bilgileri ışığında tartışıldı.

Anahtar Kelimeler

Psödoeksfoliasyon Sendromu; Renkli Doppler; Retina; Sinir Lifi Tabakası; İskemi

Abstract

A 66 year old man with normotensive unilateral pseudoexfoliation syndrome associated with ipsilateral marked ischemia with nerve fiber layer thinning and nasal step on successive visual field tests mimicking glaucomatous visual field loss is presented. Although the optic disc appearance of the clinically visible pseudoexfoliative left eye was not suggestive of glaucomatous cupping the disc appeared much pale and retinal vessels narrowed compared to the right eye. Color Doppler imaging of the left ophthalmic artery showed extremely high resistivity index of 0.88. The case is discussed in light of recent literature underscoring the fact that pseudoexfoliation is a cause of ocular ischemia.

Keywords

Pseudoexfoliation Syndrome; Color Doppler; Retina; Nerve Fiber Layer; Ischemia

DOI: 10.4328/JCAM.1698 Received: 26.02.2013 Accepted: 13.03.2013 Printed: 01.04.2016 J Clin Anal Med 2016;7(suppl 2): 87-9
Corresponding Author: Tolga Kocatürk, Department of Ophthalmology, Adnan Menderes University Medical School, 09010 Aydin, Turkey.
T.: +90 2564441256 GSM: +905333444111 E-Mail: tolgakocaturk@yahoo.com

Introduction

Pseudoexfoliation syndrome (PXS) is the most common identifiable cause of open angle glaucoma worldwide [1]. Pseudoexfoliative material on the walls of iris vessels, posterior ciliary arteries, vortex veins, and central retinal vessels [2] may alter blood flow parameters by causing several types of vascular damage [2,3].

Accumulation of pseudoexfoliative material in iridial vessel walls is associated with increased permeability, narrowing, and finally obstruction [2]. Increased ophthalmic artery resistivity index (RI) in pseudoxfoliation have been reported by two independent studies [4,5]. Saatçi et al. found presence of pseudoexfoliative material as a likely risk factor for retinal vein occlusion [6]. Puska et al. observed optic disc changes in the affected eyes of unilateral PXS patients over time and concludes that the pseudoexfoliative process itself may be a risk factor for optic disc changes [7].

We here in describe a normotensive case of unilateral PXS with marked increase in RI of the ipsilateral ophthalmic artery and significant retinal vascular attenuation associated with optic disc pallor and a visual field defect resembling nasal step in the left eye. To the best of our knowledge, this is the first case of optic neuropathy associated with marked ischemia mimicking glaucomatous visual field loss in a patient having PXS.

Case Report

A 66 year old man presented to our outpatient clinic with a chief complaint of itching, burning and stinging in both eyes. He had no prior medical history of diabetes mellitus, hypertension or family history of glaucoma. He was not using any chronic topical or oral medication. Best corrected visual acuities were 0.00 logMAR equivalent with +1.00 D refraction in the right, and 0.10 logMAR equivalent with +1.00 (+0.25x110) refraction in the left eye. Intraocular pressures (IOP) measured with a non contact tonometer (Reichert, Xpert NCT Plus, Buffalo, NY) on the day of outpatient visit were 13 mmHg and 12 mmHg on the right and left eyes respectively. Biomicroscopic examination showed pseudoexfoliative material at the pupil margin of the left eye. Dilated fundus examination showed cup-to-disc ratio to be 0.35 and 0.3 in the right and left eyes respectively, there were no nerve fiber layer defect or disc notching, and vertical disc size was 1.1 mm (as measured using a +78D lens) in both eyes.

The patient was considered to be unilateral PXS and was planned to be recruited in a clinical study. Office-hour IOPs were 15, 13, 12 mmHg, and 14, 13, 12 mmHg for the right, and left eyes respectively with Goldmann applanation tonometry. Corneal pachymetry (IOPac Advanced Pachymeter, Heidelberg Engineering, StarFish, Victoria, BC, Canada, V8V 2T2) in the right, and left eyes were 541 ± 3.5 µm, and 554 ± 2.0 µm respectively. The visual field test that was repeated three times within 4 months was normal for the right eye whereas the left eye consistently had a superior nasal step. The last follow-up visual field had been done in 17th month follow-up (Figure 1).

Due to the superior nasal step visual field defect observed in the left eye, the diagnosis of "unilateral PXS" was reconsidered and the patient had a second dilated fundus examination. Significant disc pallor especially prominent inferotemporally corresponding to the superior nasal step visual field defect as well



Figure 1. Left eye had a superior nasal step that was consistent in all visual field tests and Glaucoma Progression Analysis of the last visual field test showing no progression

as decreased caliber and irregular contour of all retinal vessels were observed in the left eye compared to the right (Figure 2).

Scanning laser polarimetry (GDx VCC, Carl Zeiss, USA) (Figure 3) and optical coherence tomography (OCT/SLO, Ophthalmic

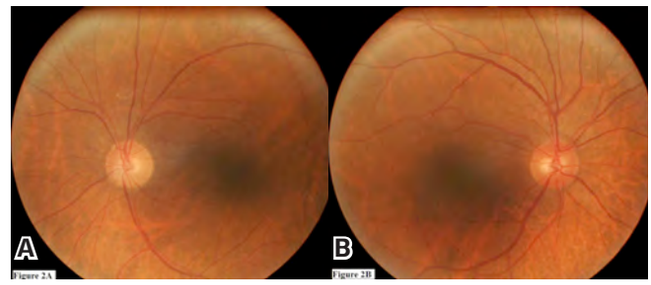

Figure 2. (A) Left fundus showing a c/d 0,3, pale optic disc and vessels of decreased caliber compared to the right eye. (B) Right fundus showing a c/d 0,35.

Technologies Inc., Canada) (Figure 4) revealed thinned nerve fiber layer in the left eye.

The subject had normal color vision with Ishihara plates and no relative afferent pupillary defect.

Brain and orbital magnetic resonance imaging (MRI) revealed non-specific periventricular gliosis and mild thinning of the left

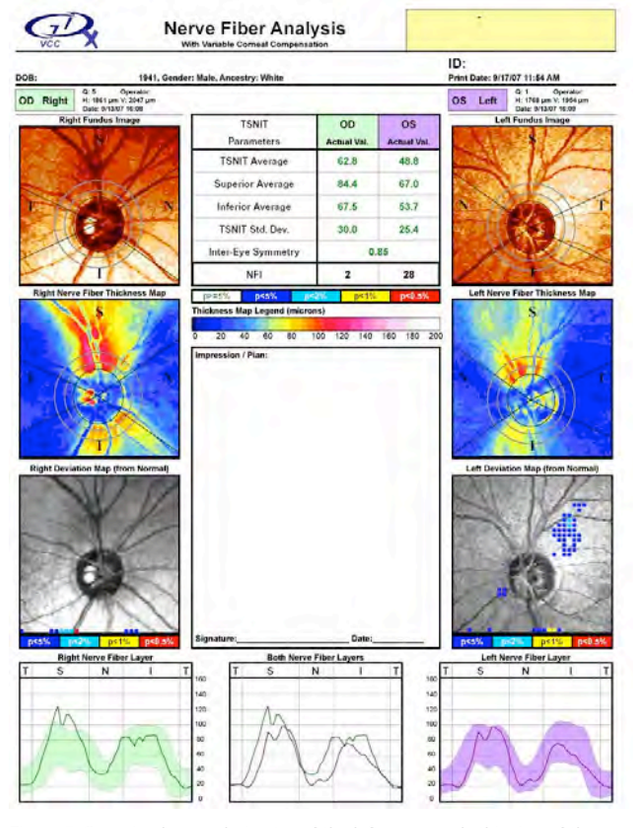

Figure 3. Scanning laser polarimetry of the left eye reveals thinning of the nerve fiber layer inferiorly although it is within normal limits.

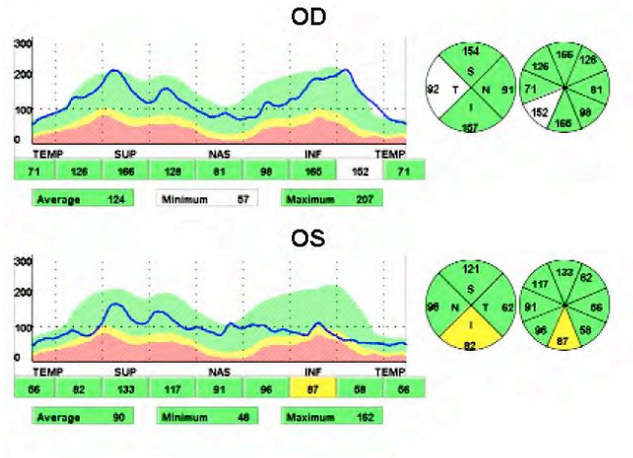

Figure 4. Optical coherence tomography showed nerve fiber layer thinning in the left eye.

optic nerve.

Color Doppler imaging of ophthalmic artery showed peak systolic velocity (PSV) of 24.9 cm/s and 42.1 cm/s, end diastolic velocity (EDV) of 7.2 cm/s and 5.0 cm/s, and RIs of 0.71 and 0.88 in the right and left eyes respectively.

Discussion

The RI is a comparison of the flow in systole and diastole and provides an indication of the resistance in the peripheral vascular bed; it can be used to facilitate an evaluation of perfusion of an organ [8]. We have previously shown that in unilateral PXS, the affected side has significantly higher mean ophthalmic artery RI (mean ± SD, 95% CI; 0.74 ± 0.04 cm/s, 0.72-0.75) compared to age-sex matched controls (0.69 ± 0.07 cm/s, 0.66-0.72; p=0.009) [5]. Similar results were obtained by Yüksel et al. [4] We have suggested a value of 0.72 for RI to be the cut-off value for differentiation of PXS.

The case in discussion had a left ophthalmic artery RI of 0.88 which is far above what we had reported for the unilateral PXS [5]. We believe that the attenuated retinal vessels and pale optic disc seen on the left fundus are a reflection of increased vascular resistance in the ophthalmic artery due to buildup of pseudoexfoliative material in vessel walls. The chronic ischemia might have led to progressive thinning of the nerve fiber layer which might eventually lead to marked cupping of the optic disc. Indeed, presence of thinner retinal nerve fiber layer has been shown in PXS when compared to the controls [9].

Repo et al. [10] suggested pathologic changes in the blood supply of PXS eyes by showing strong correlations between PSX and patients who had had a transient ischemic attact with abnormal iris transluminance.

We believe that the case described is an extreme example of normotensive ocular ischemia caused by pseudoexfoliation. Such cases are probably missed on clinical grounds since they are normotensive and are not given routine visual fields or other ancillary glaucoma tests. We suggest routine glaucoma work-up to all pseudoexfoliation patients regardless of their IOPs and use the ophthalmic artery RI of 0.72 as the cut-off value when evaluating increased vascular resistance for ophthalmic artery.

Competing interests

The authors declare that they have no competing interests.

References

1. Ritch R. The most common identifiable cause of open angle glaucoma. J.Glaucoma 1994; 3:176-178.
2. Shimizu T. Changes of iris vessels in capsular glaucoma: three-dimensional and electron microscopic studies. Jpn J Ophthalmol 1985;29:434-452.
3. Hollo G, Lakatos P, Farkas K. Cold pressor test and plasma endothelin-1 concentration in primary open- angle and capsular glaucoma. J Glaucoma 1998;7:105–110.
4. Yüksel N, Karabaş VL, Arslan A, Demirci A, Cağlar Y. Ocular hemodynamics in pseudoexfoliation syndrome and pseudoexfoliation glaucoma. Ophthalmology 2001;108:1043–1049.
5. Dayanir V, Topaloğlu A, Ozsunar Y, Keceli M, Okyay P, Harris A. Orbital blood flow parameters in unilateral pseudoexfoliation syndrome. Int Ophthalmol. 2008;29:27-32.
6. Saatci OA, Ferliel ST, Ferliel M, Kaynak S, Ergin MH. Pseudoexfoliation and glaucoma in eyes with retinal vein occlusion. International Ophthalmology 1999;23:75-78.
7. Puska P, Vesti E, Tomita G, Ishida K, Raitta C. Optic disc changes in normotensive persons with unilateral exfoliation syndrome: a 3-year follow-up study. Graefes Arch Clin Exp Ophthalmol 1999;237:457-462.
8. Meritt CRB. Physics of Ultrasound. In: Rumack CM, Wilson SR, Charboneau JW, Johnson JM, eds. Diagnostic Ultrasound. St Louis: Mosby Year Book; 2005: 3-34.
9. Gumus K, Bozkurt B, Sonmez B, Irkeç M, Orhan M, Saracbası O. Diurnal variation of intraocular pressure and its correlation with retinal nerve fiber analysis in Turkish patients with exfoliation syndrome. Graefe's Arch Clin Exp Ophthalmol. 2006;244:170–176.
10. Repo LP, Suhonen MT, Terasvirta ME, Koivisto KJ. Color Doppler imaging of the ophthalmic artery blood flow spectra of patients who have had a transient ischemic attack. Correlations with generalized iris transluminance and pseudoexfoliation syndrome. Ophthalmology 1995; 102:1199-1205.

How to cite this article:
Kocaturk T, Isıklıgil I, Dayanir V, Ozsunar Y, Cakmak H. Ischemic Changes in a Case of Unilateral Pseudoexfoliation Syndrome. J Clin Anal Med 2016;7(suppl 2): 87-9.