Simultaneous Radial Lengthening and Ulnar Shortening for a Delayed Presentation of Radius Distal Physeal Arrest: A Case Report

Distal Radius Fizyal Arreste Bağlı Eş Zamanlı Radius Uzatma ve Ulna Kısaltma: Vaka Sunumu

Simultaneous Radius Lengthening and Ulnar Shortening

Erdal Uzun, Alper Çıraklı, Fuat Duygulu
Department of Orthopedics and Traumatology, Kayseri Training and Research Hospital, Kayseri, Turkey

Özet

Distal radius kırıkları çocuklar ve yaşlılarda sık görülen el bileği yaralanmalarıdır (% 18% 25). Distal radius kırığı sonrası büyüme plağının etkilenmesi ve fizyal arrest gelişmesi ise daha nadirdir. Fizyal arrest sonrası gelişen ana deformite radius kısalığı ve bununla ilişkili olarak ulna aşırı büyümesidir, el bileği ağrısı ve fonksiyonel kısıtlılık ise ana yakınmalardır. Bu yazıda travma sonrası distal radius fizyal arrest gelişen adölosan hastanın deformitesine yönelik uygulanan eş zamanlı radyal uzatma ve ulnar kısalma cerrahi prosedürünün sunulması amaçlanmıştır.

Anahtar Kelimeler

Radiyal Uzatma; Ulna Kısaltma; Eşzamanlı Osteotomi; Fizyal Arrest; Pozitif Ulnar Varyans

Abstract

Distal radius fractures are common injuries in both children and in the elderly (25%; 18%). Distal radius physeal fractures have a high incidence, but physeal growth arrest occurs at a low rate. As a main deformity, radial shortening occurs with relative ulnar overgrowth leading to significant complaints of pain and functional limitations after distal radial growth arrest. In this paper we aim to report on the restoration of the wrist mechanics attained by performing a surgical technique of simultaneous radial lengthening and ulnar shortening procedures in an adolescent with a significant ulnar overgrowth deformity due to a posttraumatic growth arrest of distal radius.

Keywords

Physeal Arrest; Positive Ulnar Variance; Treatment; Radial Lengthening; Ulnar Shortening; Simultaneous Osteotomy

DOI: 10.4328/JCAM.4432 Received: 22.02.2016 Accepted: 08.03.2016 Printed: 01.04.2016 J Clin Anal Med 2016;7(suppl 2): 148-50
Corresponding Author: Erdal Uzun, Ortopedi ve Travmatoloji Bölümü, Kayseri Eğitim ve Araştırma Hastanesi, Kayseri, Turkey.
T.: +90 3523368884 E-Mail: nuzuladre@gmail.com

Introduction

Distal radius fractures are common injuries in both children and the elderly (25%; 18%) [1]. Although physeal fractures of the distal radius have a high incidence, physeal growth arrest occurs at a low rate (1%-7%) [1]. As a main deformity of distal radial growth arrest, radial shortening occurs with relative ulnar overgrowth leading to significant complaints of pain and functional limitations. The deformity of disturbed radio-ulnar variance is mostly associated with triangular fibrocartilage complex (TFCC) lesions and distal radio-ulnar joint (DRUJ) instability. If the dome of the distal ulna is more distal than the ulnar corner of the distal radius it is called 'positive ulnar variance' [2]. Positive ulnar variance can be the reason for the wrist pain, abnormal wrist mechanics, and limited ulnar deviation and rotation of the forearm. To reestablish a neutral radio-ulnar variance and to achieve the best possible functional results, as many authors described, ulnar shortening or radial lengthening osteotomies can be performed for this type of injury. In the literature, in a symptomatic patient with positive ulnar variance, the largest ulnar shortening performed was 15 mm in length [3]. Taylor spatial frames and external fixators are more commonly used for the correction of radial deformity and length. Ulnar shortening osteotomy is considered the standard procedure for correcting positive ulnar variance [4]. In the literature there are some studies comparing the two techniques, but our search indicates that there is no study about simultaneously performing radial and ulnar osteotomies for radial growth arrest deformity. We think that radial lengthening osteotomy can be added to ulnar shortening for more severe deformities.

In this paper we report the treatment of both acute ulnar shortening and gradual radial lengthening for the ulnar overgrowth deformity in a case of an adolescent with a significant growth arrest of the distal radius and with significantly limited ulnar deviation.

Case Report

An adolescent 16-year-old male presented to our outpatient clinic with complaints of ulnar-sided wrist pain, wrist deformity, and difficulty with movements, especially opening doors with his dominant right hand. The patient's stature was normal for his age. Reporting no family history or previous surgery of the affected extremity, he gave the history of previous treatment of distal radius fracture with closed reduction and casting, 7 years before at the same extremity. He first noticed the deformity 2 years after the fracture and the deformity increased with time. When he experienced difficulties with daily activities and increased pain with wrist movements, he came to our outpatient clinic. At presentation, there was a prominence of the distal ulna and radial deviation deformity at his right dominant wrist. At the wrist joint flexion, extension and pronation was normal but supination was limited at nearly 30°. There was a severe pain with movements, especially of ulnar deviation and supination. At the radiography, XR imaging showed nearly a 17 mm positive ulnar variance (Figure 1). The contralateral wrist had no physical or radiologic abnormalities. We considered undertaking an acute ulnar shortening osteotomy together with gradual radial lengthening osteotomy because of the severe ulnar overgrowth deformity. We notified the patient and his family



Figure 1. Preoperative photograph and XR imaging showing nearly a 17 mm positive ulnar variance

about the procedure, the possible complications, as well as the duration of the process. Informed consent was obtained from the family. Under general anaesthesia with a direct approach to distal ulna, making an oblique osteotomy, first we performed 10 mm shortening. For fixation, a 6-hole dynamic compression plate was used (Figure 2). Then with a dorsal approach to distal radius, a metaphyseal osteotomy was performed. Then the osteotomy side was fixed with a monolateral external fixator, inserting both two 3.3mm schantz screws proximally and distally (Figure 2). To control the rotation, both osteotomy sides were marked. After the operation we set the forearm in a spina cast for 2 weeks. After removing the cast, radial lengthening process was initiated at a rate of 1 mm/day. Simultaneously, physical therapy was started to regain wrist movements. After 10 days we stopped lengthening. The monolateral external fixator supported the bone for 3 more weeks during the consolidation phase and allowed for the removal of the external fixator 6 weeks following the operation. The bone regeneration and deformity correction were usually assessed every two weeks by taking X-ray images. The rate of lengthening was adjusted to ensure the bone formation. Cefazolin (1 g/TDS) was adminis-

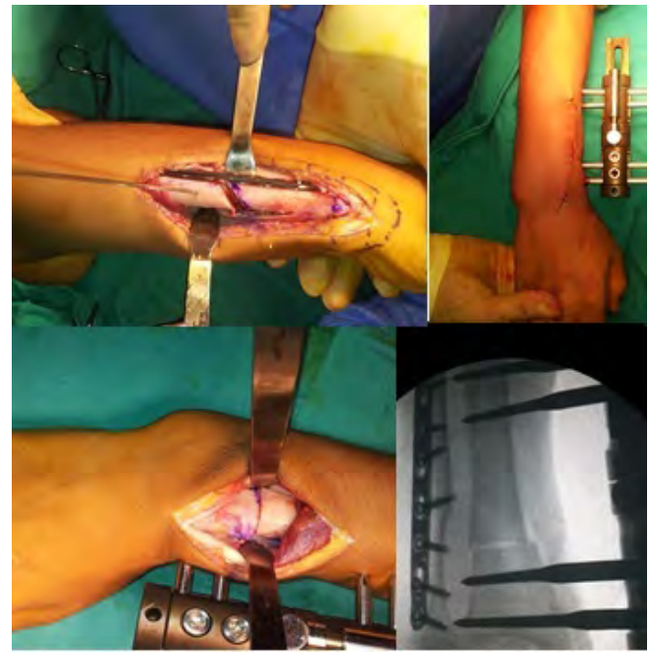

Figure 2. Intraoperative photograph showing distal ulna oblic osteotomy and fixation with a 6-hole dynamic compression plate. Distal radius metaphyseal osteotomy fixation with monolateral external fixator inserting both two 3.3mm schantz screws proximally and distally.

tered during hospitalization and 7–10 days oral antibiotic was also prescribed. During the lengthening, in case of a clinical diagnosis of infection (including pin-tract infection, osteomyelitis), appropriate antibiotic was administered. Nonsteroidal anti-inflammatory drugs were prescribed for pain management as needed. The patient was followed up for six months so that his range of motion, level of pain, and regenerated bone quality could be evaluated. Three years after the surgery, the patient had no ulnar prominence or pain with movements and had significant improvement of forearm supination. The X-ray imaging showed that the osteotomy sides were both healed with a neutral radio-ulnar variance (Figure 3). There were no complications during the follow-up period.

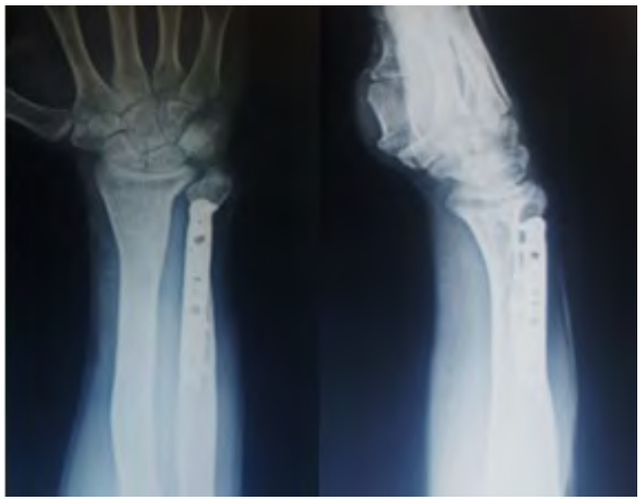

Figure 3. The final control X-Ray imaging showing that the osteotomy sides were both healed with a neutral radio-ulnar variance.

Discussion

Although physeal fractures of the distal radius are common injuries in children, physeal growth arrest occurs at a low rate (1%-7%) [1]. In the literature there are several studies including case reports and case series regarding the surgical management of distal radial growth arrest resulting in ulnar overgrowth deformities [3,5]. There are different techniques such as ulnar shortening and radial lengthening osteotomies to reestablish a neutral radio-ulnar variance for this type of deformities. Ulnar shortening osteotomy is considered the standard procedure for correcting positive ulnar variance [4]. External fixators, radial volar plates with grafting, or Taylor spatial frames are more commonly used for the correction of radial deformity and length [5,6]. Although different methods were presented for the surgical treatment of positive ulnar variance deformity, in severe deformities acute correction can sometimes be difficult to achieve, as radial lengthening osteotomy requires a large amount of strut bone graft, and ulnar shortening osteotomy of over 1 cm is difficult owing to soft tissue contracture [7]. Supporting this idea, Bowers [7] pointed out that ulnar shortening of more than 5–6 mm presents several problems with alignment and matching of bone ends because of soft tissue pressure on the construct. Miura et al. [8] also reported that distal radio-ulnar joint acute reduction can cause excessive joint loading and joint pain, stiffness, or instability. As an alternative Gong et al. [6] have reported satisfactory results after the gradual correction of distal radial malunion or physeal arrest using distraction osteogenesis. In the literature, in a symptomatic patient with positive ulnar variance, the largest ulnar shortening performed was 15 mm in length [3]. We here report a case of a delayed presentation of radius distal physeal arrest due to a prior fracture in an adolescent with nearly 17 mm positive ulnar variance. Because of the limitation of ulnar shortening, we considered making another osteotomy simultaneously to the distal radius to gradually lengthen the radius with a monolateral external fixator until we reestablished the neutral radio-ulnar variance. We performed ulnar oblique osteotomy because of the faster healing rate and lower nonunion rate when compared to the tranverse osteotomy. Using gradual lengthening of the radius, we allowed the distal radio-ulnar joint sufficient time for soft tissue adaptation. At the final follow up rebalancing the wrist, we had satisfactory results as improved range of motion, improved function, and decreased wrist pain were achieved. Also we had no complications such as pin-tract or wound infection, delayed union, or nonunion of the osteotomy side. We think while the ulnar shortening osteotomy is a suitable procedure for distal radial growth arrest in patients with little or no growth potential, radial lengthening osteotomy can be added for more severe deformities, affording a good outcome and restoration of the radio-ulnar variance.

Conclusion

In symptomatic adolescents, surgery for posttraumatic distal radial growth arrest can reduce the level of pain and loss of motion. To reestablish a neutral radio-ulnar variance and to achieve the best possible functional results for more severe positive ulnar variance deformities, ulnar shortening and radial legthening osteotomies can be performed simultaneously.

Competing interests

None of the authors has any conflict of interest to declare.

References

1. Nellans KW, Kowalski E, Chung KC. The epidemiology of distal radius fractures. Hand Clin 2012;28(2):113-25.
2. Luria S, Lauder AJ, Trumble TE. Comparison of ulnar-shortening osteotomy with a new Trimed dynamic compression system versus the Synthes dynamic compression system: clinical study. J Hand Surg Am 2008;33(9):1493-7.
3. Ellanti P, Harrington P. Acute ulnar shortening for delayed presentation of distal radius growth arrest in an adolescent. Case Rep Orthop 2012;2012:928231.
4. Schattenkerk ME, Nollen A, van Hussen F. The treatment of lunatomalacia. Radial shortening or ulnar lengthening? Acta Orthop Scand 1987;58(6):652-4.
5. Waters PM, Bae DS, Montgomery KD. Surgical management of posttraumatic distal radial growth arrest in adolescents. J Pediatr Orthop 2002;22(6):717-24.
6. Gong HS, Roh YW, Oh JH, Lee YH, Chung MS, Baek GH. Computed tomographic assessment of reduction ofthe distal radioulnar joint by gradual lengthening of the radius. J Hand Surg Eur Vol. 2009;34(3):391-6.
7. Bowers WH. The distal radioulnar joint. In: Green DP, Hotchkiss RN, Pederson WC (Eds.) Green's operative hand surgery. Philadelphia, Churchill Livingstone, 1999: 986–1032.
8. Miura T, Firoozbakhsh K, Cheema T, Moneim MS, Edmunds M, Meltzer S. Dynamic effect of joint-leveling procedure on pressure at the distal radioulnar joint. J Hand Surg Am 2005;30:711–8.

How to cite this article:
Uzun E, Çıraklı A, Duygulu F. Simultaneous Radial Lengthening and Ulnar Shortening for a Delayed Presentation of Radius Distal Physeal Arrest: A Case Report. J Clin Anal Med 2016;7(suppl 2): 148-50.