Acquired Hypothyroidism in an Adolescent Associated with Radioactive Iodine-131 Therapy of the Mother

Radyoaktif İyot-131 Tedavisi Alan Annenin Adolesan Çocuğunda Gelişen Hipotiroidi

Hypothyroidism and I131 Treatment

Filiz Serdaroğlu[1], Özgür Pirgon[2]
[1]Pediatri, [2]Pediatrik Endokrinoloji, SDÜ Tıp Fakültesi, Isparta, Türkiye

Özet

Çocukların radyoaktif iyota maruz kalması sonucu hipotiroidi ve tiroid kanserleri gelişebilir. Bu yüzden özellikle küçük çocuk ve gebelerin bu tedaviyi alanlardan bir süre uzak tutulması gerekir. Literatürde bu tedaviyi alanlarda kendilerinin tedavi alması sonucu iki olgu ve annesinin aldığı tedaviden etkilenerek bir olgu olmak üzere toplam sadece üç tiroid kanseri geliştiren adolesan olgu mevcuttur. Bu olgu sunumunda, radyoaktif iyot tedavisi alan bir anneyle aynı ortamda yaşayan ve annesinin bu tedavisine bağlı olarak hipotiroidi gelişen 11 yaşındaki kız olgu sunulup, literatür bilgileri ışığı altında tartışılması planlandı.

Anahtar Kelimeler

Çocuk; Hipotiroidi; Radyoaktif İyot

Abstract

Hypothyroidism or thyroid cancer may develop in children as a result of exposure to radioactive iodine. Therefore, young children and pregnant women in particular should not be in close physical proximity to patients receiving this therapy. We found only three cases of adolescents developing thyroid cancer in the literature. Two were affected by radioactive iodine treatment of themselves and one was affected by treatment of the mother. Here we report on an 11-year-old girl living in the same environment as her mother, who was receiving radioactive iodine therapy. The girl developed transient hypothyroidism in association with her mother's treatment. We discuss the case in light of the literature.

Keywords

Children; Hypothyroidism; Radioactive Iodine

DOI: 10.4328/JCAM.4470 Received: 07.03.2016 Accepted: 25.03.2016 Printed: 01.04.2016 J Clin Anal Med 2016;7(suppl 2): 151-3
Corresponding Author: Filiz Serdaroğlu, Çocuk Sağlığı ve Hastalıkları ABD, SDÜ Tıp Fakültesi, Isparta, Türkiye.
GSM: +905065782378 E-Mail: drserdaroğlu@gmail.com

Introduction

Radioactive iodine (131I) therapy is an effective, economical, and simple method, used widely, particularly to treat Graves' disease and thyroid gland malignities in adults. However, due to insufficient evidence regarding its reliability, it is still not widely used in children. Hypothyroidism, autoimmune thyroiditis, and thyroid neoplasms may develop as the result of accidental exposure of children to radioactive iodine [1]. All people, and particularly young children and pregnant women, are advised to avoid being in proximity to patients receiving this treatment. Cases of exposure in the prenatal period and the resultant development of congenital hypothyroidism and thyroid nodules have been widely reported in the literature [2,3]. Thyroid cancer has been reported in two adolescents receiving radioactive MIBG therapy, and there has been only one publication reporting papillary thyroid carcinoma developing as a result of 131I therapy administered to the mother [4,5]. Here we report a case of hypothyroidism in the 11-year-old child of a mother receiving 131I therapy due to thyroid cancer.

Case Report

An 11-year-old girl presented to our clinic with symptoms of lethargy, fatiguing easily, and swelling in the neck region over the previous 1.5 months. Her mother had been operated on due to papillary thyroid carcinoma approximately 2 months previously, after which she had received 131I therapy. The mother's two other children had been removed from the home due to the radioactive therapy she received, but our patient had remained with the mother. At physical examination, the patient's weight was 26 kg (3%) and height was 132.5 cm (10%). Head and neck examination revealed stage 1 thyromegaly. No tachycardia was observed, and arterial blood pressure values were normal for her age (110/65 mmHg). Laboratory examination revealed fT4: 0.39 ng/dL (N= 0.61-1.12 ng/dL) and TSH: 54.4 uIU/mL (N=0.34-4.2 uIU/mL), while anti-TPO and anti-thyroglobulin were negative. At thyroid ultrasonography, the left and right thyroid lobes were large for her age, while the thyroid parenchyma was homogeneous. No lymph nodes were pathological in size. The patient was started on L-thyroxin 2 mcg/kg/day due to hypothyroidism. At thyroid function follow-up one month later, the patient was euthyroid while the right and left thyroid lobes had decreased to an age-appropriate size (Figure 1). The case was monitored as euthyroid under low-dose L-thyroxin therapy for 2 years. Growth rate, weight gain, and pubertal development were within physiological limits throughout monitoring. Treatment was concluded at the end of 2 years.

Discussion

Immune system-related causes and iodine deficiency are the most important factors in the etiology of childhood hypothyroidism. In our patient who presented with hypothyroidism, the medical history revealed no etiological factor, other than the mother's having received 131I therapy due to papillary cancer. The fact that the child's symptoms developed 15 days after the mother's receipt of this treatment, and the exclusion of other causes, suggested that exposure to radioactive 131I in the child, who had not been removed from the mother's presence during her 131I therapy, was involved as the agent in the disease.

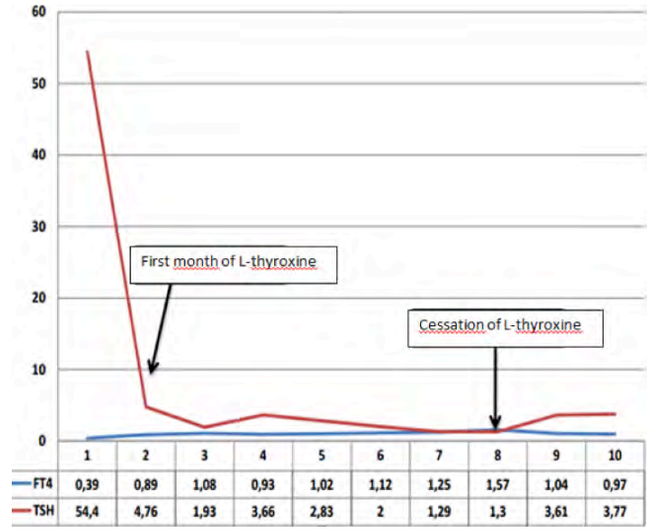

	1	2	3	4	5	6	7	8	9	10
FT4	0,39	0,89	1,08	0,93	1,02	1,12	1,25	1,57	1,04	0,97
TSH	54,4	4,76	1,93	3,66	2,83	2	1,29	1,3	3,61	3,77

Figure 1. The course of thyroid function

Radioactive iodine therapy is an effective, economical, and simple method that has been used to treat hyperthyroidism and thyroid neoplasms in adults for approximately 50 years. The radiation damages thyroid follicle cells and prevents hormone synthesis. This method is contraindicated in pregnancy and lactation. It is not popular with pediatricians because tissues in early adulthood and childhood are more sensitive to radiation. Individuals receiving radioactive iodine therapy must avoid pregnant women and children for at least 1 week for safety reasons, must use separate eating and cleaning implements than other members of the family, must keep a distance of at least 60 cm between themselves and others, and must sleep alone. The relationship between radioactive iodine and malignity has not been proven. However, data from nuclear accidents have shown an increase in cases of non-immune hypothyroidism and thyroid cancers among exposed individuals [1,6,7]. Thyroid cancer was reported to develop in two adolescents receiving 131I MIBG therapy for neuroblastoma [4]. Cases of congenital hypothyroidism and thyroid cancer have been reported to develop following intrauterine exposure [2,3]. However, we encountered only one case of thyroid cancer developing in a child in close proximity to an individual receiving treatment [5]. We encountered no reports of transient hypothyroidism as was seen in our case. We attributed thyroid follicle cell injury and transient hypothyroidism in our patient to the radioactive iodine therapy received by the mother. The laboratory findings in our case showed that hypothyroidism developed due to non-immune causes; the condition was temporary since it resolved completely with monitoring and treatment. Although there are previous cases in the literature of congenital hypothyroidism developing as an effect of radioactive iodine administered to the mother in the intrauterine period, to the best of our knowledge, ours is the first case of hypothyroidism developing in an adolescent child exposed to radioactivity via the mother. We think that this report will make a significant contribution to the literature, and that greater care should be taken over safety precautions following radioactive iodine therapy.

Competing interests

The authors declare that they have no competing interests.

References

1. Davis S, Kopecky KJ, Hamilton TE, Onstad L; Hanford Thyroid Disease Study Team. Thyroid neoplasia, autoimmune thyroiditis, and hypothyroidism in persons exposed to iodine 131 from the hanford nuclear site. JAMA 2004;292(21):2600-13.
2. Kurtoğlu S, Ali Akın M, Daar G, Akin L, Memur S, Korkmaz L, et al. Congenital Hypothyroidism Due To Maternal Radioactive Iodine Exposure During Pregnancy. J Clin Res Pediatr Endocrinol 2012;4(2) :111-13.
3. Perry RJ, Ainine A, Butler S, Donaldson MDC. Hypoechoic thyroid nodules on ultrasound 4 years after prenatal exposure to radioiodine: resolution with thyroxine therapy. Acta Pædiatrica/Acta Pædiatrica 2008; 97(4):509–12.
4. van Santen HM, Tytgat GA, van de Wetering MD, van Eck-Smit BL, Hopman SM, van der Steeg AF, et al. Differentiated thyroid carcinoma after 131I-MIBG treatment for neuroblastoma during childhood:description of the first two cases. Thyroid 2012;22(6):643-6.
5. Sangkhathat S, Patrapinyokul S, Chiengkriwate P, Kritsaneepaiboon S, Kayasut K, Pramphapa T, et al. Papillary carcinoma of the thyroid gland in a child of thyrotoxicosis patient receiving radioactive iodine therapy:report of a case. Pediatr Surg Int 2008;24(6):747–50.
6. Ostroumova E, Rozhko A, Hatch M, Furukawa K, Polyanskaya O, McConnell RJ, et al. Measures of thyroid function among Belarusian children and adolescents exposed to iodine-131 from the accident at the Chernobyl nuclear plant. Environ Health Perspect 2013;121(7):865-71.
7. Cardis E , Kesminiene A , Ivanov V , Malakhova I, Shibata Y, Khrouch , et al. Risk of Thyroid Cancer After Exposure to 131 I in Childhood. J Natl Cancer Inst 2005;97(10):724 – 32.

How to cite this article:
Serdaroğlu F, Pirgon Ö. Acquired Hypothyroidism in an Adolescent Associated with Radioactive Iodine-131 Therapy of the Mother. J Clin Anal Med 2016;7(suppl 2): 151-3.