Nonsustained Repetitive Upper Septal Idıopathic Fascicular Left Ventricular Tachycardia: Rare Type of VT

Tekrarlayan Süreksiz İdiyopatik Sol Ventriküler Üst Septal Fasiküler Taşikardi: Nadir Tip VT

Upper Septal Fascicular Left Ventricular Tachycardia

Gökhan Aksan[1], Remzi Sarıkaya[2], Ali Elitok[2], Ahmet Kaya Bilge[2], Kamil Adalet[2]
[1]Department of Cardiology, Şişli Hamidiye Etfal Training and Research Hospital,
[2]Department of Cardiology, İstanbul Faculty of Medicine, İstanbul University, İstanbul, Turkey

Özet

Üst septal fasiküler ventriküler taşikardi, idiyopatik fasiküler ventriküler taşikardi subtipleri arasında oldukça nadir görülen bir taşikardidir. Üst septal fasiküler taşikardi anterograd yolunda posterior fasikülü, retrograd yolunda ise septal fasikülü kullanmaktadır. Dar QRS morfolojisi ve normal aks özelliğine sahip bu taşikardinin elektrokardiyografik bulguları supraventriküler taşikardi ile karıştırılabilmektedir. Biz burada His-Purkinje sisteminin proksimalinden kaynaklanan oldukça nadir bir fasiküler taşikardi alt tipini raporladık.

Anahtar Kelimeler

Üst Septal Fasiküler Taşikardi; Ablasyon; Purkinje Potansiyel

Abstract

Upper septal fascicular ventricular tachycardia is a very rare form of idiopathic fascicular ventricular tachycardia. Upper septal fascicular tachycardia uses the posterior fascicle as the anterograde limb and the septal fascicle as the retrograde limb. When evaluating the electrocardiography for this form of tachycardia, the presence of narrow QRS morphology and normal axis may be misinterpreted as supraventricular tachycardia. Here, we report a very rare subtype of fascicular tachycardia that originates more proximally in the His-Purkinje system at the base of the heart.

Keywords

Upper Septal Fascicular Tachycardia; Ablation; Purkinje Potential

DOI: 10.4328/JCAM.4517 Received: 31.03.2016 Accepted: 24.04.2016 Printed: 01.04.2016 J Clin Anal Med 2016;7(suppl 2): 161-4
Corresponding Author: Gökhan Aksan, Department of Cardiology, Şişli Hamidiye Etfal Training and Research Hospital, 34371 İstanbul, Turkey.
T.: +90 2123735000 F.: +90 2122240772 E-Mail: aksan55@yahoo.com

Introduction

Idiopathic fascicular ventricular tachycardia (VT) of the left ventricle is a rare type of VT. It occurs predominantly in young males (15-40 years old). Unlike idiopathic right ventricular outflow VT, which usually occurs as either nonsustained or sustained monomorphic VT, idiopathic fascicular left VT usually occurs as sustained monomorphic [1]. Verapamil-sensitive fascicular VT is the most common form of idiopathic left VT. The mechanism of this tachycardia is reentry within the left-sided specialized conduction system. The most common form of these tachycardias affects the posterior fascicle and is therefore known as posterior fascicular VT. Left posterior fascicular VT exhibits right bundle branch block (RBBB) morphology and superior axis. A less common form, left anterior fascicular VT shows RBBB morphology and right axis. A very rare form affecting the septal fascicle, known as upper septal fascicular VT, has narrow QRS morphology and normal or right axis deviation [2-4].

Case Report

A 46-year-old female patient was admitted to the cardiology outpatient clinic with symptoms of intermittent attacks of palpitations and discomfort. An initial electrocardiogram (ECG) revealed that she had sinus rhythm with repetitive nonsustained 185-190 bpm narrow QRS complex tachycardia without an axis deviation (Figure 1). The patient's complete blood count (CBC),

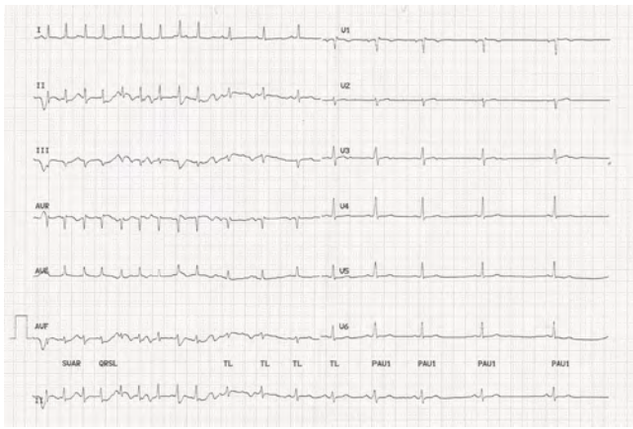

Figure 1. Twelve-lead electrocardiogram of nonsustained fascicular ventricular tachycardia with narrow QRS morphology and normal axis

renal function tests, thyroid function tests, and serum electrolyte levels were normal. Echocardiography was performed and left ventricular systolic and diastolic functions were normal. There was no evidence of structural heart disease. The patient used B-blocker medicine at times when she had palpitation attacks; she refused the chronic antiarrhythmic treatment. We offered a diagnostic electrophysiological study and planned an ablation procedure.

A quadripolar electrophysiology and radiofrequency ablation catheter (7F Marinr ablation catheter, Medtronic, USA) were used via the right femoral vein and artery. In the electrophysiological study, AH-HV intervals were normal. Simultaneously with the catheter manipulations, a sustained 187 bpm narrow QRS tachycardia with normal axis that was almost identical to the clinical tachycardia was induced (Figure 2). Atrioventricular dissociation (AV) was observed during tachycardia (Figure 3). Clinical tachycardia was easily induced with programmed



Figure 2. Twelve-lead electrocardiogram of sustained upper septal idiopathic fascicular left ventricular tachycardia

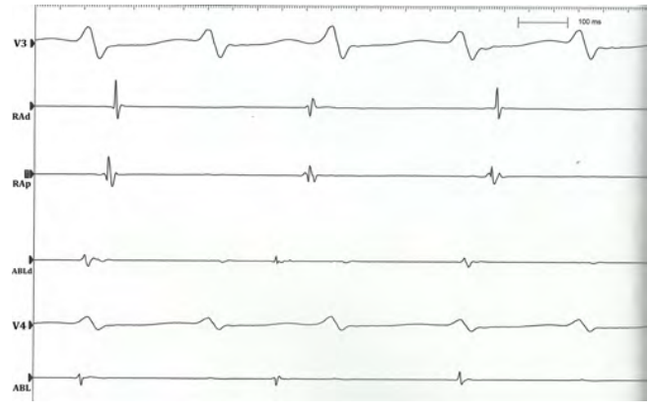

Figure 3. Intracardiac recordings during upper septal fascicular tachycardia with atrioventricular dissociation

electrical stimulations (PES) from right ventricular apex (RVA). Tachycardia was not induced with PES from high right atrium (HRA) under isoproterenol infusion. During VT, retrograde activation of the His bundle was recorded before the onset of the QRS complex with a His-ventricular interval that was shorter during VT than that during sinus rhythm (26 msn vs. 51 msn respectively). Endocardial mapping was made by retrograde transaortic approach within the left ventricle. Early Purkinje potentials before the onset of QRS were detected by an activation mapping technique during tachycardia. At the upper ventricular septum activation mapping during tachycardia, at the level od distal His bundle or proximal left bundle branch, early Purkinje potential was observed 23 msn before the onset of QRS (Figure 4). During tachycardia, five radiofrequency ablations were performed to the site of earliest Purkinje potential (40 W, temperature 42°C -52°C). Due to the proximity to the His bundle, RF ablations were performed carefully and for a short time. After the procedure, clinical tachycardia was not inducable with PES from RVA. Following the procedure, a twelve-lead ECG revealed no AV complete block and left bundle branch block (LBBB) (Figure 5). Following the RFA procedure, the tachycardia could not be reinduced, stable sinus rhythm without bursts of VT was maintained, and baseline QRS morphology remained unchanged. After a follow up of 3 months without antiarrhythmic drugs, the patient was asymptomatic without new episodes of tachycardia.

Discussion

Ventricular tachycardias spreading from the anterior and posterior divisions of the left bundle branch are generally called fascicular tachycardia. Fascicular tachycardia has been classified

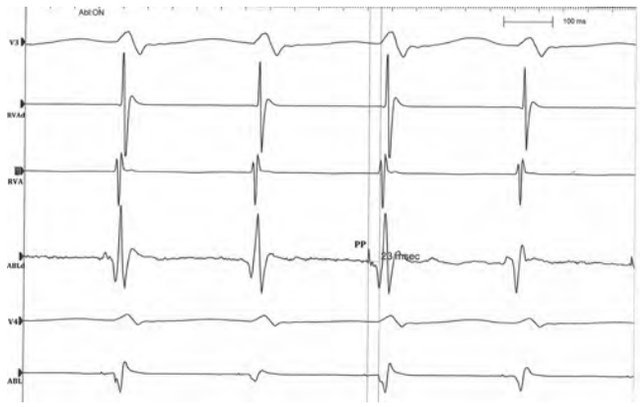

Figure 4. Purkinje potential (PP) preceding the onset of QRS during fascicular tachycardia at the successful ablation site at the left upper septum

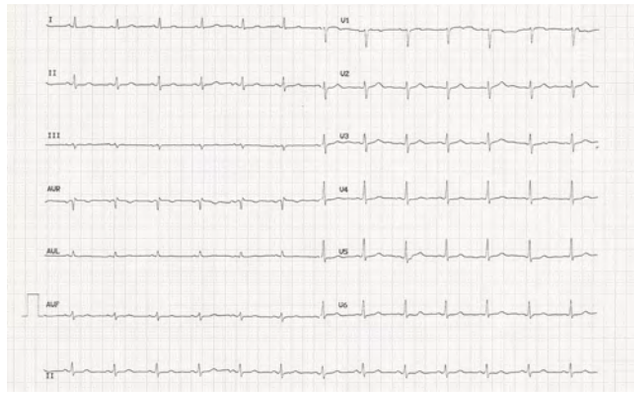

Figure 5. Twelve-lead electrocardiogram after tachycardia ablation

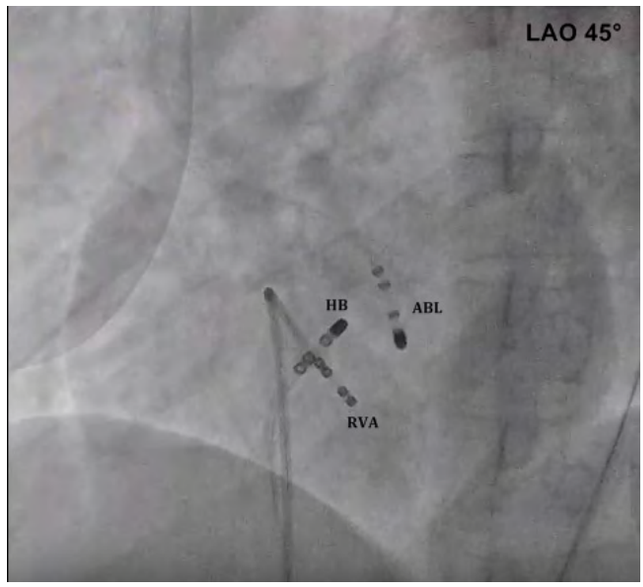

Figure 6. Fluoroscopy of catheter position at successful ablation site

into three subtypes. First, left posterior fascicular VT with right bundle branch block (RBBB) pattern and superior axis deviation. Second, left anterior fascicular VT with RBBB pattern and right axis deviation. Third, upper septal fascicular VT with a narrow QRS and normal axis configuration. Upper septal tachycardia usually exhibits incomplete RBBB morphology [4]. Rare cases exhibiting LBBB (precordial R wave transition between V3 and V4) and a normal frontal plane axis have been reported [5]. The most common form of fascicular tachycardia is the posterior fascicular type, which accounts for nearly 90% of the cases. Left anterior fascicular VT is uncommon (approximately 10%), and left upper septal fascicular VT is very rare (less than 1%). Overwhelming evidence suggests that idiopathic fascicular left ventricular tachycardia is caused by a re-entrant circuit incorporating the Purkinje system with an excitable gap and slow conduction area [4]. Upper septal idiopathic fascicular tachycardia uses portions of the posterior fascicular normal Purkinje fibers as the anterograde limb (which can be considered an orthodromic form of posterior fascicular VT) and the septal fascicular abnormal Purkinje fibers as the retrograde limb. There is simultaneous passive activation of the right bundle branch and anterior fascicle; this accounts for the relatively narrow QRS, which can be very similar to baseline QRS [4]. In our patient, the QRS morphology of the tachycardia was similar to the baseline QRS morphology of the twelve-lead ECG at admission. Upper septal fascicular tachycardia is often associated with a history of ablation of a typical posterior fascicular VT, although our patient had not undergone this procedure. The fascicular tachycardia circuit can be constructed from the observations during VT. During fascicular tachycardia two distinct potentials can be observed before the ventricular electrogram, namely the Purkinje potential (PP) and pre-Purkinje potential (pre-PP), also designated P2 and P1 respectively. In upper septal fascicular tachycardia, Purkinje potentials were activated in a reverse direction to that of left posterior fascicular tachycardia; namely, pre-Purkinje potential (P1) was activated retrogradely but the Purkinje potential (P2) was activated anterogradely. Purkinje potential (PP or P2) , first described by Nakagawa et al. [6], represents the activation of the left posterior fascicle or the Purkinje fibers near the left posterior fascicle; this potential precedes the onset of QRS during tachycardia. The pre-Purkinje potential (pre-PP or P1) was first described by Tsuchiya et al. [7]. It represents excitation at the entrance to the specialized zone in the ventricular septum which has decremental properties and is sensitive to verapamil. Pre-PP potential precedes PP potential during fascicular tachycardia. Nogami et al. [8] observed that the interval between PP at the site of successful ablation and the onset of the QRS complex during VT was 18±6 msn (6±3% VT cycle length). In our case, at the upper ventricular septum activation mapping during tachycardia, early Purkinje potential was observed 23 msn before the onset of QRS. At this point in the procedure, it was possible to entrain the tachycardia. A difference was obtained between the post-pacing interval (PPI) and tachycardia cycle length (0 msn), with an interval between the peak pacing level and the QRS onset equal to the interval between the fascicular potential and QRS onset. These findings indicate that there was a reentry mechanism and the ablation catheter was positioned at the site of the tachycardia circuit. Finally, in such cases, ventricular tachycardias reflecting RBBB morphology, such as mitral anular VT, intramyocardial reentry VT, and interfascicular VT, should be considered in the differential diagnosis. The main cause for arrhythmia in this case was the reentry mechanism associated with slow entrance of calcium into Purkinje fibers.

Competing interests

The authors declare that they have no competing interests.

References

1. Belhassen B, Rotmensch HH, Laniado S. Response of recurrent sustained ventricular tachycardia to verapamil. Br Heart J 1981;46:679–82

2. Sung RK, Kim AM, Tseng ZH, Han F, Inada K, Tedrow UB, et al. Diagnosis and ablation of multiform fascicular tachycardia. J Cardiovasc Electrophysiol 2013;24:297–304.
3. Ma W, Wang X, Cingolani E, Thajudeen A, Gupta N, Nageh MF, et al. Mapping and ablation of ventricular tachycardia from the left upper fascicle. How to make the most of the fascicular potential ?. Circ Arrhythm Electrophysiol 2013;6:47–51.
4. Talib AK, Nogami A, Nishiuchi S, Kowase S, Kurosaki K, Matsui Y, et al. Verapamil sensitive upper septal idiopathic left ventricular tachycardia: prevalence, mechanism, and electrophysiological characteristics. J Am Coll Cardiol EP 2015;1(5):369-80.
5. Shimoike E, Ueda N, Maruyama T, Kaji Y. Radiofrequency catheter ablation of upper septal idiopathic left ventricular tachycardia exhibiting left bundle branch block morphology. Journal of Cardiovascular Electrophysiology 2000;11(2): 203-7.
6. Nakagawa H, Beckman KJ, McClelland JH, Wang X, Arruda M, Santoro I, et al. Radiofrequency catheter ablation of idiopathic left ventricular tachycardia guided by a Purkinje potential.Circulation 1993;88(6):2607-17
7. Tsuchiya T, Okumura K, Honda T, Honda T, Iwasa A, Yasue H, et al. Significance of late diastolic potential preceding Purkinje potential in verapamil-sensitive idiopathic left ventricular tachycardia. Circulation 1999;99(18):2408–13.
8. Nogami A, Naito S, Tada H, Taniguchi K, Okamoto Y, Nishimura S, et al. Demonstration of diastolic and presystolic purkinje potentials as critical potentials in a macroreentry circuit of verapamil-sensitive idiopathic left ventricular tachycardia. J Am Coll Cardiol 2000;36(3);811-23.

How to cite this article:
Aksan G, Sarıkaya R, Elitok A, Bilge AK, Adalet K. Nonsustained Repetitive Upper Septal Idıopathic Fascicular Left Ventricular Tachycardia: Rare Type of VT. J Clin Anal Med 2016;7(suppl 2): 161-4.