Gastrointestinal Stromal Tumor with Mesenteric Localization Fistulized to Proximal Jejunum Causing Massive Rectal Bleeding

Masif Rektal Kanamaya Neden olan Proksimal Jejunuma Fistülize Mesenterik Yerleşimli Gastrointestinal Stromal Tümör

Gastrointestinal Stromal Tumor with Mesenteric Localization Fistulized to Proximal Jejunum

Mehmet Tolga Kafadar[1], Işılay Nadir[2], Mikdat Bozer[1]
[1]Department of General Surgery, [2]Department of Gastroenterology, Turgut Özal University Faculty of Medicine, Ankara, Turkey

Özet

Gastrointestinal stromal tümörler (GİST) gastrointestinal sistemin en yaygın mezenkimal tümörleridir. Epitelyal olmayan bu tümörler gastrointestinal traktus duvarının muskularis propria tabakasından çıkarlar. En sık lokalizasyonu mide ve ince barsaklardır. Nadiren gastrointestinal sistem ile bağlantısız olarak retroperitonda veya abdomende ortaya çıkabilirler. Sıklıkla gastrointestinal sistem hastalıklarının endoskopik ve radyolojik incelemelerinde veya hemoraji, obstrüksiyon ve organ perforasyonu gibi acil durumların cerrahi tedavisi sırasında, tesadüfen tanı konur. Bu yazıda proksimal jejunuma fistülize, nadir lokalizasyonuyla masif rektal kanamaya yol açan 59 yaşında bir GİST olgusu sunuldu. Histopatolojik inceleme ile kesin tanı alan olguya, total kitle eksizyonu ile birlikte yaklaşık 20 cm jejunum rezeksiyonu yapıldı.

Anahtar Kelimeler

Gastrointestinal Kanama; Jejunum; Stromal Tümör

Abstract

Gastrointestinal stromal tumors (GISTs) are the most common mesenchymal tumors of the gastrointestinal system. These non-epithelial tumors originate from the muscularispropria layer of the wall of the gastrointestinal tract. Their most common locations of origin are the stomach and small intestine. Rarely, they may originate from the retroperitoneum or abdomen, and may have no connection with the gastrointestinal system. They are usually incidentally detected in endoscopic and radiological examinations of the gastrointestinal system or during surgical treatment of emergency conditions such as hemorrhage, obstruction, or organ perforation. In this paper, we report a 59-year-old man with GIST located in the proximal jejunum that caused massive bleeding owing to its rarely encountered location. Histopathological examination made the definitive diagnosis, and the patient underwent total excision of the mass and the resection of a 20-cm jejunal segment.

Keywords

Gastrointestinal Bleeding; Jejunum; Stromal Tumor

DOI: 10.4328/JCAM.4582 Received: 24.04.2016 Accepted: 10.05.2016 Printed: 01.04.2016 J Clin Anal Med 2016;7(suppl 2): 180-2
Corresponding Author: Mehmet Tolga Kafadar, Department of General Surgery, Turgut Özal University Faculty of Medicine, 06510, Ankara, Turkey.
T.: +90 3122035555 F.: +90 3122213670 E-Mail: drtolgakafadar@hotmail.com

Introduction

Gastrointestinal stromal tumors (GISTs) normally originate from the interstitial Cajal cells or the neoplastic transformation of their precursors. Their estimated annual incidence is 10-20 per million [1]. They are mostly of gastric origin (50-60%) and constitute 1% of all malignancies. GISTs that are equal to or smaller than 2 cm are usually asymptomatic and incidentally detected by endoscopic or radiological studies or during surgery performed for other indications [2]. Herein we report a case of GIST with mesenteric localization that was fistulized to the proximal jejunum and presented with massive rectal bleeding. We also provide a discussion of the relevant literature.

Case Report

A 59-year-old man presented to the gastroenterology clinic with rectal bleeding and weakness. On physical examination, he had an abdominal tenderness that was predominantly of epigastric location, but he had no guarding and rebound tenderness. Rectal digital examination revealed melena. Blood pressure was 90/60 mmHg, pulse rate 92/min. He had an admission hemoglobin of 9.3 g/dl. White blood cell count and basic biochemistry panel were all within normal values. Gastroduodenoscopy did not reveal any pathology. Colonoscopy was suboptimal due to thrombosed blood within the lumen. The axial arterial phase of whole abdomen computed tomography (CT) revealed a mass lesion with heterogeneous contrast uptake at the level of the gastrocolic ligament, that was located in the neighbourhood of the inferior wall of the gastric body and the superior part of transverse colon. The mass compressed proximal jejunal segments, displaced transverse colon anteriorly, and extended to the anterior paraaortic region at the renal level (Figure 1). As the patient had a progressively decreasing Hb level despite the replacement of 4 units of erythrocyte suspension, he was admitted to the general surgery ward and operated on under emergency conditions. Explorative laparotomy revealed a mesenteric mass with a size of 9x6 cm and a patchy necrotic surface that was located 10 cm distal to the Treitz ligament, the mass fistulized to the jejunum. The mass was completely excised together with a 20-cm jejunal segment (Figure 2a,b) and a jejunojejunal anastomosis was established. Histopathological examination showed a GIST (spindle cell type). The tumor was diffusely stained with CD117 (C-Kit) in the immunohistochemical examination (Figure 3a,b). The patient was discharged on day 7 postoperatively and scheduled to receive imatinib. He returned for a follow-up appointment 10 days later, at which time he had no clinical problem at all.



Figure 1. The axial arterial phase of whole abdomen CT shows a mass lesion with heterogeneous contrast uptake at the level of gastrocolic ligament, that was located in the neighbourhood of the inferior wall of gastric body and superior part of transverse colon (blue arrow), the mass compresses proximal jejunal segments, displaces transverse colon anteriorly, and extends to the anterior paraaortic region at the renal level (red arrow)

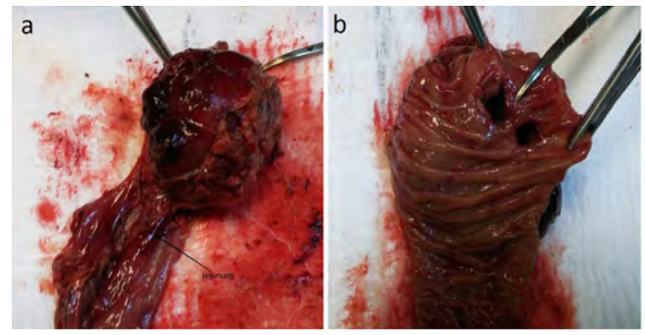

Figure 2. Appearance of the mass after total excision and the jejunal segment to which the mass fistulized (a, b)

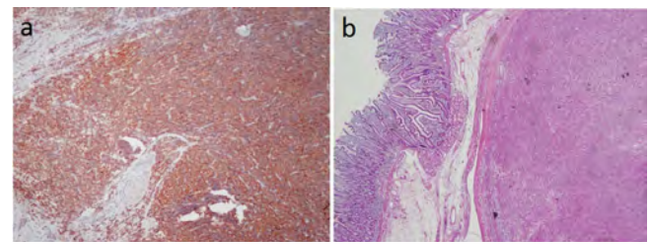

Figure 3. Microscopic appearance after histological staining (+CD 117-C-Kit X100, HEX40) (a, b)

Discussion

GISTs constitute roughly 80% of all gastrointestinal mesenchymal tumors. The majority of GISTs possess a benign character. They are usually observed after the 4th decade, usually during the decade of the 60's. Their size ranges between a few millimeters and 35 cm, with a mean size of 5 cm. The tumor becomes symptomatic when it exceeds 4 cm. When symptomatic, GISTs present with symptoms depending on localization; these can include abdominal pain, anemia, abdominal mass, dyspeptic complaints, and dysphagia. They also sometimes cause emergency conditions such as intraabdominal bleeding, massive gastrointestinal bleeding, perforation, or obstruction [3,4]. Our patient presented with massive rectal bleeding.

Omental and mesenteric primary stromal tumors show the typical immunohistochemical properties of GISTs. As no Cajal cells exist in this localization, one may consider it odd to encounter this tumor outside the gastrointestinal system. This situation is explained by the fact that GISTs may develop from multipotent mesenchymal stem cells (precursors of Cajal cells), since there exist CD117 positive cells immediately beneath the mesothelium and in the omentum [5].

Radiological studies and endoscopy may suggest the diagnosis of GIST in patients with abdominal complaints. Barium swallow may show intraluminal growth or submucosal lesions, but there may also be an extrinsic compression of an adjacent segment

by an exophytic growth [1]. On USG, CT, and magnetic resonance imaging (MRI) these tumors usually appear as lesions, originating from the gastrointestinal wall, that have exophytic, but sometimes also intraluminal, extensions. Our patient's CT examination revealed a mass lesion with heterogeneous contrast enhancement and cystic and solid components that were located at the level of the gastrocolic ligament, inferior to the gastric body, and adjacent to the superior border of the transverse colon and major vessels; it had a compressive effect on proximal jejunal segments and displaced the transverse colon in the anterior direction. GIST may also appear as a submucosal mass in endoscopy or colonoscopy or as a hypoechoic lesion originating from muscularis propria in endoscopic USG. FDG-PET is sensitive but nonspecific for GIST. However, it may be used to monitor disease extension and metabolic activity. Since it also allows whole-body imaging, it is also useful for the detection of distant metastases [6].

GIST usually shows direct invasion, although it may also metastasize to the liver, lungs, and bones via a hematogenous route. Approximately 50% of GISTs have already metastasized at the time of diagnosis. Although the liver and peritoneum are the most common sites of metastasis, lymph nodes, lungs, and bone marrow may also be involved [7]. We did not detect any metastasis in our patient.

After the introduction of C-Kit into practice as a cellular marker, GISTs have been more frequently diagnosed. C-Kit protein (CD117) is a transmembrane growth factor that is the product of the Kit protooncogene. GISTs usually (85-100%) express C-Kit protein. Additionally, 60-70% of tumors are CD34 positive, 30-40% are SMA positive, and 5% are S-100 positive [6]. Our patient's tumor was diffusely stained with CD117(C-Kit) but it was negative for SMA, Desmin, CD34, and S-100. A proliferation index of 1-3% was detected with Ki-67.

Although tumor diameter and number of mitosis are the parameters that are most commonly used for determining prognosis, Bucher et al. [8] suggested a practical staging system for postoperative staging, which is composed of 5 minor and 2 major criteria. Minor criteria are tumor size ≥ 5 cm, mitotic index ≥ 5 mitosis, presence of necrosis, extension to adjacent tissue, and MIBI (Ki-67) index > 10%. Lymph node invasion and metastasis are the major criteria. Fewer than 4 minor criteria indicate a low-grade GIST; 4-5 minor criteria, or 1 major criterion are indicative of high-grade GIST. Our patient's tumor had a diameter of 9x6 cm and a mitotic ratio of 1-3%. There was 10-20% necrosis in tumor tissue and 5 lymph nodes with reactive changes in the small intestine. Its pathological stage was reported as T3,N0,Mx.

Despite advances in medical treatment of GISTs, surgical resection still plays the main role in the management of these tumors. A careful tumor dissection should be done to avoid rupture of the tumor that became fragile. Wedge or segmental resections usually suffice. Lymph node involvement is rare and therefore no routine lymphadenectomy is needed unless macroscopic lymph node involvement is apparent [9]. The recommended approach for recurrent GISTs is the oral administration of imatinib, a tyrosine kinase inhibitor, which is able to induce remission and regression in 50-80% of cases. Imatinib is also the agent of choice for the treatment of patients with metastatic GIST or those who are not candidates for surgery owing to overall poor status [10].

Conclusion

Currently, no radiological or endoscopic study is sufficient to make the definitive diagnosis of GISTs, and biopsy sampling is necessary in most cases. Definitive diagnosis is made with the help of immunohistochemical markers. Although rare, GIST associated with the small intestine should be considered in the case of massive rectal bleeding. In this circumstance, primary treatment of the tumor is surgical therapy, where total excision is the recommended method.

Competing interests

The authors declare that they have no competing interests.

References

1. Joensuu H, Kindblom LG. Gastrointestinal stromal tumors: a review. Acta Orthop Scand Suppl 2004;75(311):62-71.
2. Downs-Kelly E, Rubin BP. Gastrointestinal stromal tumors: Molecular mechanisms and targeted therapies. Patholog Res Int 2011;2011:708596. doi: 10.4061/2011/708596.
3. Dinc T, Kayilioglu SI, Erdogan A, Cetinkaya E, Akgul O, Coskun F. Small intestinal and mesenteric multiple gastrointestinal stromal tumors causing occult bleeding. Case Rep Gastrointest Med 2016:5137975. doi: 10.1155/2016/5137975.
4. Uçar AD, Oymaci E, Carti EB, Yakan S, Vardar E, Erkan N, et al. Characteristics of emergency gastrointestinal stromal tumor (GIST). Hepatogastroenterology 2015;62(139):635-40.
5. Miettinen M, Monihan JM, Sarlomo-Rikala M, Kovatich AJ, Carr NJ, Emory TS, et al. Gastrointestinal stromal tumours/ smooth muscle tumours (GISTs) primary in the omentum and mesentery: clinicopathologic and immunohistochemical study of 26 cases. Am J Surg Pathol 1999;23(9):1109-18.
6. Sturgeon C, Chejfec G, Espat N. Gastrointestinal stromal tumors: a spectrum of diseases. Surg Oncol 2003;12(1):21-6.
7. Kingham TP, DeMatteo TP. Multidisciplinary treatment of gastrointestinal stromal tumors. Surg Clin North Am 2009;89(1):217-33.
8. Bucher P, Villiger P, Egger JF, Buhler LH, Morel P. Management of gastrointestinal stromal tumours: from diagnosis to treatment. Swiss Med Wkly 2004;134(11-12):145-53.
9. Everett M, Gutman H. Surgical managenent of gastrointestinal stromal tumors: analysis of outcome with respect to surgical margins and technique. J Surg Oncol 2008;98(8):588-93.
10. Rabin I, Chikman B, Lavy R, Sandbank J, Maklakovsky M, Gold-Deutch R, et al. Gastrointestinal stromal tumors: A 19 year experience. Isr Med Assoc J 2009;11(2):98-102.

How to cite this article:
Kafadar MT, Nadir I, Bozer M. Gastrointestinal Stromal Tumor with Mesenteric Localization Fistulized to Proximal Jejunum Causing Massive Rectal Bleeding. J Clin Anal Med 2016;7(suppl 2): 180-2.