Primary Pulmonary Leiomyoma in a Male

Primer Pulmoner Leiomiyomlu Bir Erkek Olgu

Primary Pulmonary Leiomyoma

Ali Cevat Kutluk[1], Kasım Çağlayan[2], Hasan Akın[1], Hasan Güçer[3], Halil Doğan[4]
[1]Yedikule Chest Diseases and Chest Surgery Hospital, Istanbul,
[2]Department of General Surgery, University of Bozok, Yozgat,
[3]Department of Pathology, University of Recep Tayyip Erdogan, Rize,
[4]Department of Emergency Medicine, Bakirkoy Sadi Konuk Hospital, Istanbul, Turkey

1.Eurasian Congress on Emergency Medicine 2008'de P028 kodu ile poster olarak sunulmuştur.

Özet

Akciğerin primer pulmoner leiomiyomu benin natürlüdür ve en nadir mezodermal kökenli tümörlerdendir. Rutin göğüs röntgeni çekimlerinin artması ile birlikte bu lezyonlarla daha sıklıkla karşılaşılmağa başlanmıştır. Tedavisi parankim koruyucu rezeksiyondur ve prognozu oldukça iyidir. Otuz yaşında, öksürük, balgam çıkarma ve gece terlemesi şikâyetleri ile başvuran bir erkek hastanın görüntüleme tetkiklerinde sol alt lobda kitle saptanması üzerine yapılan rezeksiyon sonucu primer pulmoner leiomiyom tanısı alan olguyu sunduk.

Anahtar Kelimeler

Primer; Pulmoner; Leiomiyom

Abstract

Primary pulmonary leiomyoma of the lung is benign in nature and is one of the rarest tumors of mesodermal origin. Because of the increasing number of routine chest roentgenograms, these lesions are being discovered more frequently. Treatment is by conservative surgical resection and carries a favorable prognosis. We presented a 30-year-old patient with expectoration cough and night sweats who undergone resection due to a mass in left lower lobe and diagnosed primary pulmonary leiomyoma.

Keywords

Primary; Pulmonary; Leiomyoma

DOI: 10.4328/JCAM.4740 Received: 11.07.2016 Accepted: 25.07.2016 Printed: 01.06.2016 J Clin Anal Med 2016;7(suppl 3): 247-9
Corresponding Author: Ali Cevat Kutluk, Yedikule Göğüs Hastalıkları ve Göğüs Cerrahisi Eğitim ve Araştırma Hastanesi, İstanbul, Türkiye.
GSM: +905056309187 E-Mail: dralikutluk@gmail.com

Introduction

A lung tumor may manifest as a solitary nodule, as a mass, or as an endobronchial obstructing lesion. A variety of uncommon primary tumors and pseudotumors may sporadically affect the lung, although they represent less than 1% of all lung neoplasms. These rare pulmonary tumors can be either benign or malignant and have a broad spectrum of mesenchymal, epithelial, lymphoreticular, and vascular causes [1-3].

Primary leiomyoma of the lung is benign in nature and is one of the rarest tumors of mesodermal origin [4]. Primary pulmonary leiomyoma (PPL) is thought to arise from the smooth muscle of the bronchi, bronchioles, or bronchial arterioles. Leiomyomas were first described by Forkel in 1910 [5]. About one third of these lesions are of endobronchial origin [6,7]. Because of the increasing number of routine chest roentgenograms, these lesions are being discovered more frequently. On occasions, this type of tumor has been followed roentgenographically over an interval of several years and definite growth has been observed. Exploratory thoracotomy with removal and definitive diagnosis is certanly advisable [4]. We aim to report an additional pulmonary leiomyoma case and to review the literature.

Case Report

A 30-year-old smoker male was admitted to our clinic with complaints of productive cough and night sweating for two months. At physical examination, breath sounds were slightly decreased in the left base. Body temperature was 37.6 °C with a pulse rate of 89 beats/minute and a respiratory rate of 20/minute. Blood count examination, routine biochemical tests and urine analysis were within normal values. Erythrocyte sedimentation rate was 13 mm in the first hour. The patient's chest radiograph showed a 36 mm nodular lesion with smooth contours (Figure 1).



Figure 1. PA graph demonstrating a 36 mm nodular lesion with smooth contours.

For detailed characterization of the lesion, computed tomography (CT) of the thorax was performed. CT demonstrated a homogenous nodular lesion in the posterior segment of the left lung with a smooth, slightly lobulated contours. The attenuation value of the lesion was 45 HU and was isodense with muscular tissue. The lesion had no calcification foci. There was no mediastinal or hilar lymphadenomegaly. To delineate the endobronchial anatomy a fiberoptic bronchoscopy was performed and revealed no lesion. A transthoracic needle aspiration biopsy was performed and yielded no diagnosis. The size, slightly lobulated contour, absence of benign calcification the natures of the lesion, the smoking history of the patient all indicated a referral to surgery. Before surgery, positron emission tomography was performed. It found that the lesion had a standard uptake value (SUV-max) of 1.5 and subcarinal lymph nodes had 1.3 SUV-max. An exploratory left thoracotomy was performed and a smooth-lobulated solid mass was found in the posterior segment of the lower lobe. A needle biopsy was taken for frozen section analysis and it was found to be a benign spindle cell mesenchymal tumor. A wedge resection was performed to remove the lesion. Macroscopic examination showed a grey-white, smooth contoured lesion, measured at 5x3x3cm. Microscopic examination with Hemotoxylin-Eosin (H&E) showed uniform, nonpleomorphic spindle cells with elongated nuclei which are characteristic of smooth muscle cells, no mitosis, necrosis or pleomorphism was detected. An immunohistochemical study was positive for desmin and smooth muscle actin (SMA) (Figure 2). In light of these findings the lesion was diagnosed as primary pulmonary leiomyoma. The patient attends follow-up at an outpatient clinic and has continued doing well 6 years following surgery.

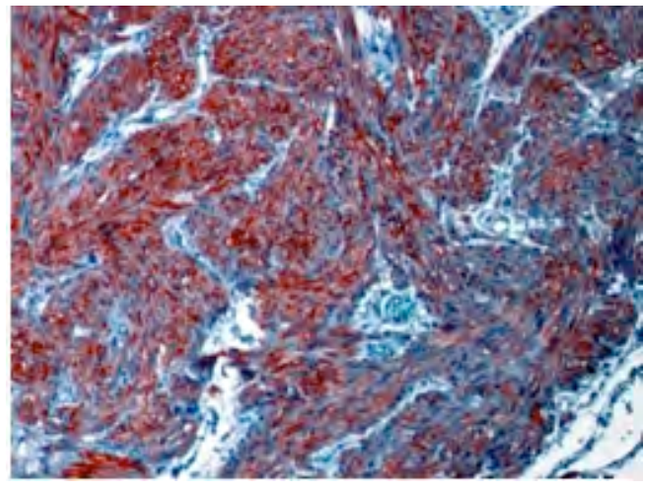

Figure 2. Immunohistochemical study demonstrating positive reaction for desmin and smooth muscle actin (SMA)

Discussion

Leiomyoma accounts for fewer than 1% of all lung neoplasms [7]. Primary leiomyomas can present as parenchymal, endobronchial, or tracheal. Over half of these lesions arise from the pulmonary parenchyma, one-third from bronchi, and fewer from trachea [8]. There is general agreement that endobronchial leiomyomas originate in the smooth muscle fibers of the bronchial wall [9,10].

In our case, the patient was a 30-year-old male with parenchymal leiomyoma. Leiomyomas are predominantly tumors of the young and middle aged with a mean age of 39.1 years [10]. In adults, while parenchymal leiomyoma occurs twice as often in females as males, endobronchial leiomyoma occurs equally in both sexes [6]. One-third of pulmonary leiomyomas are asymptomatic [8]. Parenchymal lesions rarely cause symptoms. 92.9% of patients with endobronchial leiomyoma have respiratory symptoms due to a partial or total obstruction of a bronchus and superimposing infections resulting from atelectasis or bronchiectasis, distal to the obstruction [10]. Our patient

was suffering from productive cough and night sweating with parenchymal form, there were no parenchymal infiltrative shadows, atelectasis, or air trapping found by chest radiography and CT examination.

Magnetic resonance imaging (MRI) is the most useful imaging modality for characterizing these tumors, because, regardless of their anatomic location, classic leiomyomas have signal intensity similar to that of smooth muscle on images obtained with any MR pulse sequence. However, histopathologic analysis is usually required to confirm the diagnosis [11].

Different surgical and anesthesiologic strategies are used, according to the location of the lesion. But the main principle is to save as much parenchyme as possible. For tracheal tumors and main bronchial lesions that required carinal reconstruction, the operation is performed using an anterior approach via median sternotomy. For tumors located at the lobar bronchus the usual segmentectomy or lobectomy, and for more distal locations a wedge resection should performed with a lateral decubitus position [12]. We preferred wedge resection because the pathology report was a benign lesion at frozen section.

PPL is very rare, and may sometimes arouse suspicion of malignancy in the differential diagnosis nodules or masses in the lung, whilst it carries excellent prognosis with complete resection.

Competing interests

The authors declare that they have no competing interests.

References

1. Sekine I, Kodama T, Yokose T, Nishiwaki Y, Suzuki K, Goto K, et al. Rare pulmonary tumors: a review of 32 cases. Oncology 1998;55:431-4.
2. Dail DH. Uncommon tumors. In. Dail DH, Hammar SP, Colby TV, eds. Pulmonary pathology: tumors. New York, NY: Springer 1995;157-341.
3. Shimosato Y. Pulmonary neoplasm. In. Sternberg SS, ed. Diagnostic surgical pathology. 2nd ed. New York, NY. Raven 1994;1045-93.
4. Zidane A, Elktaibi A, Benjelloun A, Arsalane A, Afandi O, Bouchentouf R. Primary leiomyoma of the lung: an exceptional localization. Asian Cardiovasc Thorac Ann 2016;24(4):393-6.
5. Orlowski TM, Stasiak K, Kolodziej J. Leiomyoma of the lung. J Thorac Cardiovasc Surg 1978;76:257-61.
6. Shahian DM, McEnany MT. Complete endobronchial excision of leiomyoma of the bronchus. J Thorac Cardiovasc Surg 1979;77:87-91.
7. Wu P, Venkatachalam J, Lee VKM, Tan SK. Primary pulmonary leiomyoma. Respirology Case Reports 2016;4(3):153.
8. Garcia JC, Chang AL, Chung V, Shim C, Factor S, Tibb A. Bronchial leiomyoma, a case report and review of literature. Respiratory Medicine Case Reports 2014;12;59–62.
9. Ayabe H, Tsuji H, Tagawa Y, Tomita M, Tsuda N, Chen J. Endobronchial leiomyoma: Report of a case treated by bronchoplasty and a review of the literature. Surg Today 1995;25:1057-60.
10. Karnak I, Akcoren Z, Senocak ME. Endobronchial leiomyoma in children. Eur J Pediatr Surg 2000;10:136-9.
11. Fasih N, Shanbhogue AP, Macdonald DB, Fraser-Hill MA, Papadatos D, Kielar AZ, et al. Leiomyomas beyond the uterus: unusual locations, rare manifestations. Radiographics 2008;28(7):1931-48.
12. Park JS, Lee M, Kim HK. Primary leiomyoma of the trachea, bronchus, and pulmonary parenchyma — a single-institutional experience. Eur J Cardiothorac Surg 2012;41(1):41-5.

How to cite this article:
Kutluk AC, Çağlayan K, Akın H, Güçer H, Doğan H. Primary Pulmonary Leiomyoma in a Male. J Clin Anal Med 2016;7(suppl 3): 247-9.