Case Report
JCAM

Anomalous Right Coronary Artery: A Rare Cause of Recurrent Syncopal Attacks

Anormal Sağ Koroner Arter: Rekürren Senkop Atağının Nadir Bir Nedeni

Osman Beton[1], Hatice Kaplanoğlu[2], Ali Bulut[3], Süleyman Sürer[3], Uğursay Kızıltepe[3]
[1]Cumhuriyet University, Faculty of Medicine, Department of Cardiology, Heart Center Hospital, Sivas,
[2]Department of Radiology, Diskapi Yildirim Beyazit Research and Training Hospital, Ankara,
[3]Department of Cardiovasculer Surgery, Diskapi Yildirim Beyazit Research and Training Hospital, Ankara, Turkiye

Özet

Koroner arterin anormal orjini nadirdir, genellikle myokard infarktüsüne ve ventriküler taşikardiye neden olmaz. Biz sol sinüs valsalvadan köken olan ventriküler taşikardi ve myokard infarktüsü ile birliktelik gösteren, nadir bir vaka olan anormal orjinli sağ koroner arteri sunduk. Kırk iki yaşında erkek hasta dış merkezden senkop ve senkop öncesinde belgelenmiş ventriküler taşikardi atağı ile transfer edildi. MPS' de inferior bölgede küçük iskemik alan saptandı. Koroner BT anjiyografide sağ koroner arterin, LMCA' dan ayrı bir ostiumla sol koroner aortik sinüsten kaynaklandığı, aorta ve pulmoner trunk arasında seyrettiği izlendi. Kardiyovasküler cerrahiyle konsültasyondan sonra, düzeltme cerrahisine karar verildi. Cerrahlar tarafından başarılı bir düzeltme cerrahisi yapıldı ve hasta cerrahiden sonra asemptomatikti.

Anahtar Kelimeler

Koroner Arter Anomalisi; Sağ Koroner Arter; İnterarteryal Seyir

Abstract

Anomalous origin of the coronary artery is a rare anomaly and does not generally lead to myocardial infarction and ventricular tachycardia. We report an uncommon case of anomalous origin of the right coronary artery originating from the left sinus of Valsalva with ventricular tachycardia and myocardial ischemia. A 42-year-old male was transferred from an external facility due to syncope and documented episodes of ventricular tachycardia preceding syncope. MPS showed small ischemic area in the inferior wall. Coronary CT angiography confirmed that RCA was originating from the left coronary aortic sinus with a separate ostium from the LMCA and coursing between the aorta and the pulmonary trunk. After consulting with cardiothoracic surgeons, the decision to perform corrective surgery was made. A successful correction surgery was performed by the surgeons, and the patient was asymptomatic after surgery.

Keywords

Coronary Artery Anomaly; Right Coronary Artery; Interarterial Course

DOI: 10.4328/JCAM.4750 Received: 15.07.2016 Accepted: 10.08.2016 Printed: 01.06.2016 J Clin Anal Med 2016;7(suppl 3): 256-8
Corresponding Author: Hatice Kaplanoglu, Department of Radiology, Diskapi Yildirim Beyazit Training and Research Hospital, 06100, Ankara, Turkiye.
T.: +90 3125084443 F.: +90 31231866 E-Mail: hatice.altnkaynak@yahoo.com.tr

Introduction

The literature shows that approximately 1% of patients undergoing coronary angiography have coronary arterial anomalies[1]. The right coronary artery originating from the left sinus of Valsalva is a rare anomaly, and it is observed in approximately 0.1% of the patients undergoing coronary angiography [2]. This may lead to myocardial ischemia, syncope, and sudden cardiac death, and they often have a silent clinical course [1].

Case Report

A 42-year-old male was referred from an external facility due to syncope and documented episodes of ventricular tachycardia preceding syncope. The patient had sustained ten episodes of syncope within the past 3 years. Six months ago, exercise treadmill test was negative; echocardiography and ECG were all normal. Non-sustained ventricular tachycardia episodes were detected in Holter monitoring. The patient had undergone electrophysiological study three months before, but no sustained ventricular tachycardia was induced. Metoprolol and aspirin have been prescribed by the electrophysiologist, and he was taking his medications regularly. On admission, physical examination, ECG, and echocardiography showed normal findings. The patient was scheduled for exercise myocardial perfusion imaging study. MPS showedsmall ischemic area in the inferior wall. Thus, coronary angiography was performed. LMCA, LAD, and LCx all appeared normal (Figure 1). Attempts to cannulate the

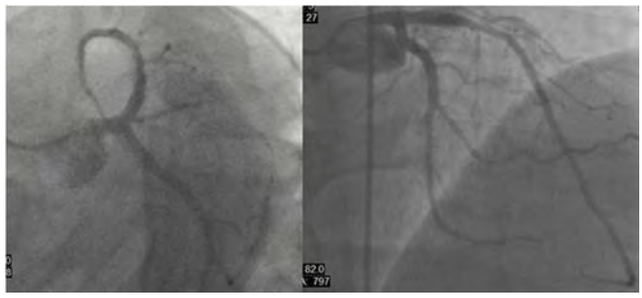

Figure 1. The LMCA, LAD, and LCx were normal in the coronary angiography.

RCA were unsuccessful at the right coronary aortic sinus. The RCA could be cannulated at the left coronary aortic sinus with MP1 catheter, and it had a separate ostium from the LMCA. RCA angiography showed normal findings (Figure 2). This coronary anomaly was very rare affecting 0.024% to 0.044% of the population. Because of the possibility of coursing between the aorta and the pulmonary trunk, the patient was scheduled for coronary multislice CT angiography. RCA was found to be originating from the left coronary aortic sinus with a separete ostium from the LMCA and coursing between the aorta and the pulmonary trunk (Malignant type 3 coronary anomaly) (Figure 3). After consulting with cardiothoracic surgeons, the decision

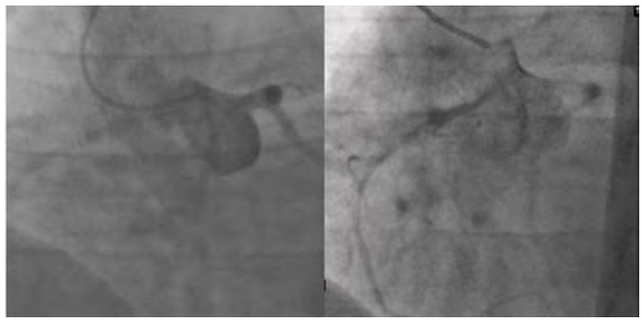

Figure 2. The RCA was normal in the coronary angiography.

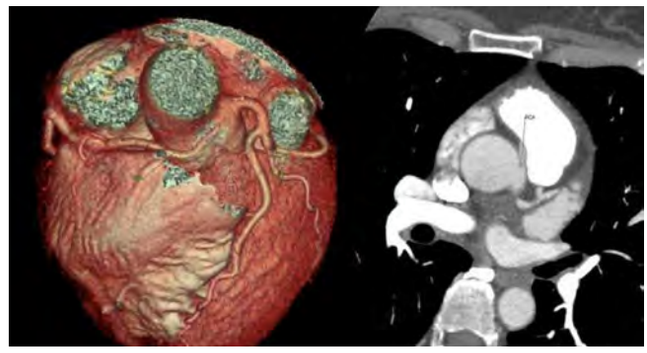

Figure 3. In the coronary CT angiography, the RCA was observed to originate from the left sinus of Valsalva with a separete ostium from the LMCA, and to course between the aorta and pulmonary artery (a,b).

to perform corrective surgery was made. The ostium of the RCA was ligated and detached from the left sinus. Then, the ostium of the RCA was successfully reattached to the proximal RCA using an end-to-side aortocoronary anastomosis to the right sinus of Valsalva.A successful correction surgery was performed by the surgeons, and the patient was asymptomatic after surgery.

Discussion

Coronary artery anomalies account for the most common second-order causes of sudden cardiac deaths associated with exercise, following hypertrophic cardiomyopathy [3]. An abnormally originating RCA is observed in 92% of the general population, and it is detected more frequently than an anomalous origin of the LMCA[3].

If a coronary anomaly would cause complaints, the symptoms most frequently appear before the age of 30 years, and there is a strong correlation with exercise [3].The clinical signs vary from syncope to angina, myocardial infarction, and sudden cardiac death [4]. Sudden cardiac death is more commonly observed in the LMCA anomalies compared to anomalous origin of the RCA [4].Sudden deaths due to coronary artery anomalies may be caused by various mechanisms. The primary ischemic mechanism associated with ACAOS is related to the compression and collapse of the proximal segment of the RCA that courses between the main pulmonary artery and the aorta due to increased intra-aortic pressure during strenuous exercise [5]. Other possible mechanisms include acute takeoff of the orifice of the RCA from the left sinus of Valsalva (acute takeoff), distension or severe angulation of the RCA, and coronary arterial spasm [5]. The presence of an abnormal slit-like ostium in the aortic wall and acute angulation of the RCA may lead to limitations in coronary blood flow [4].Narrow-angle takeoff of the abnormal coronary artery from the aorta and a tortious course of its proximal segment accelerate atherosclerosis [4]. Intussusception of the initial segment of the RCA into the aortic wall is called an intramural part, and the enlarged aorta during increased cardiac output leads to its compression [4].

An evaluation of the anomalous origination of the coronary artery can be made by angiography, intravascular ultrasound, transthoracic and transesophageal echocardiography, coronary

CT angiography, and MRI [6]. The use of coronary angiography is limited in the evaluation of coronary anomalies, since it is sometimes difficult to cannulate the orifice and visualize complex three-dimensional structure of the artery in the two-dimensional plane. Coronary CT angiography is the preferred non-invasive imaging method, because it permits three-dimensional imaging and it has a high spatial resolution [6]. In the present study, a narrow-angle takeoff of the RCA from the left sinus of Valsalva was determined in the coronary CT angiography, and this finding was considered to explain the episodes ofsyncope the patient has experienced during exercise and the mechanisms of ischemia.

The choices of treatment in ACAOS include the following: 1- limitation of a high level of physical exercise, in combination with medical therapy, 2- stent placement into the compressed vessel or 3- surgical treatment. Medical therapy is effective and less invasive; however, a high level of physical exercise must be avoided, since it has a potential risk for sudden cardiac death [7]. Various cases have been reported that underwent stent implantation for a compressed proximal RCA [7]. However, there is an insufficient data on the long-term clinical outcomes and the duration of the stent patency following percutaneous coronary intervention [7].

Surgical treatment is recommended in cases with aberrant RCA showing an interarterial course, if they have signs of cardiac ischemia (class 1, level B evidence) [8]. The choices of surgical treatment recommended for ACAOS are as follows: unroofing procedure for the coronary artery, reimplantation of the coronary ostium, and coronary artery bypass graft (CABG) [8]. In the presence of an intramural segment in the abnormal coronary artery, the intramural segment of the coronary artery is dissected, and reimplantation is performed to the proper sinus of Valsalva. The unroofing procedure is a well-known technique, and it is a safe approach to correct the anomaly [8]. The unroofing technique can also be used in abnormal arteries with a slit-like ostium and with a supracommissural intramural course. Vessel translocation or reimplantation is recommended as a choice of treatment in patients without an intramural segment [8].

The current report presents a case withanomalous origin of the right coronary artery originating from the left sinus of Valsalva that was diagnosed with CT angiography and was successfully treated with RCA reimplantation.

Conclusion

Coronary CT angiography is a helpful, precise, and practical tool, and it is complementary to coronary angiography. It is a non-invasive modality that can be used to reveal relationship between the coronary arteries and large vessels and ventricles, and cases with anomalous origin of the coronary arteries. The signs of various coronary arterial anomalies on CT and understanding of the clinical importance of these anomalies are essential for an accurate diagnosis and treatment planning of the patient.

Competing interests

The authors declare that they have no competing interests.

References

1. Maron BJ, Doerer JJ, Haas TS, Tierney DM, Mueller FO. Suddendeaths in young competitive athletes: analysis of 1866 deaths inthe United States, 1980-2006. Circulation 2009;119(8):1085-92.

2. Fuglsang S, Heiberg J, Byg J, Hjortdal VE. Anomalous origin of the right coronary artery with an interarterial course and intramural part. Int J Surg Case Rep 2015;14:92-4.

3. De Pooter J, Van Driessche L, Bartunek J. Aberrant right coronary artery arising from the left sinus of Valsalva with an interarterial course. Acta Cardiol 2014;69(2):185-8.

4. Angelini P. Coronary artery anomalies: an entity in search of an identity. Circulation 2007;115(10):1296–305.

5. Matsumura K, Matsumoto H, Hata Y, Ueyama T, Kinoshita T, Kuwauchi S, et al. Anomalous Right Coronary Artery Arising from the Left Sinus of Valsalva in a Young Athlete. Intern Med 2016;55(1):55-8.

6. Lee BY. Anomalous right coronary artery from the left coronary sinus with an interarterial course: is it really dangerous? Korean Circ J 2009;39(5):175-9.

7. Bagur R, Gleeton O, Bataille Y, Bilodeau S, Rodés-Cabau J, Bertrand OF. Right coronary artery from the left sinus of vaisalva:multislice CT and transradial PCI. World J Cardiol 2011;3(2):54-6.

8. Conway BD, Bates MJ, Hanfland RA, Yerkes NS, Patel SS, Calcaterra D, et al. A minimally invasive, algorithm-based approach for anomalous aortic origin of a coronary artery. Innovations (Phila) 2015;10(2):101-5.

How to cite this article:

Beton O, Kaplanoğlu H, Bulut A, Sürer S, Kızıltepe U. Anomalous Right Coronary Artery: A Rare Cause of Recurrent Syncopal Attacks. J Clin Anal Med 2016;7(suppl 3): 256-8.