Case Report
JCAM

Large Nabothian Cyst: Manifestation with Pelvic Organ Prolapse in a Nulliparous Patient

Büyük Nabothi Kisti: Nullipar Hastada Pelvik Organ Prolapsusa Neden Olan Olgu

Nabothian Cyst Caused Pop

Tayfur Çift, Engin Korkmazer, Rampia Nizam, Merve Olgun, Beril Şenkutlu
Department of Gynecology and Obstetrics, Bursa Yüksek Ihtisas Training and Research Hospital, Bursa, Turkey

Özet

Pelvik organ prolapsusu(POP) pelvik organların herniasyonu olarak tanımlanmaktır. POP genellikle postmenapozal dönemde oluşmaktadır. Multiparite, ağır yük kaldırma, obezite, ileri yaş, menopoz, uzamış doğum eylemi ve sigara POP için risk faktörünü oluşturabilmektedir.Nullipar kadınlarda seyrek olarak görülmektedir. Nullipar kadınlarda ana risk faktörü pelvik taban desteğinde kalıtımsal defektlerdir. Nabothi kistleri iyi huylu oluşumlardır. Genelde kendiliğinden kaybolur ve rutin pratikte klinik bulgu vermezler. POP'a neden olan nabothi kisti klinik pratikte çok nadir görülür. Yaptığımız olgu sunumunda 20 yaşında virgo hastada prolapsusa neden olan nabothi kisti ve tedavisi sunulmaktadır.

Anahtar Kelimeler

Servikal Kist; Pelvik Organ Prolapsusu; Cerrahi Girişimler

Abstract

Pelvic organ prolapse (POP) is described as the herniation of pelvic organs. POP generally occurs at postmenopausal age. Multiparity, increased intraabdominal pressure (e.g., bearing heavy weights, exerting physical effort), obesity, advanced age, menopause, prolonged labor, and smoking constitute prevailing risk factors of POP. It is seen rarely in nulliparous women. The main risk factors in nulliparous women are inherent defects in pelvic support. Nabothian cysts are benign entities in nature. They usually dissolve spontaneously and do not cause any clinical symptoms in routine practice. Nabothian cysts that cause POP are very rare in clinical practice. In this case report, we present the management of a large nabothian cyst causing POP in a 20-year-old patient without any prior intercourse.

Keywords

Cervical Cyst; Pelvic Organ Prolapse; Surgical Procedures

DOI: 10.4328/JCAM.4770 Received: 27.07.2016 Accepted: 15.08.2016 Printed: 01.06.2016 J Clin Anal Med 2016;7(suppl 3): 262-4
Corresponding Author: Tayfur Çift, Cumhuriyet M. Ozan S. 6/11 Ataevler, Nilüfer, Bursa, Turkey.
GSM: +905325521928 E-Mail: tayfur_cift@yahoo.com

Introduction

Pelvic organ prolapse (POP) is the herniation of pelvic organs to or beyond the vaginal wall and generally occurs at postmenopausal age (1,2). Weakness of pelvic muscles, connective tissues, and pelvic fascia may cause the prolapse. In apical compartment prolapse, the apex of the vagina descends into the lower vagina. Pelvic masses might be a reason for prolapse as well (3). Multiparity, increased intraabdominal pressure (e.g., bearing heavy weights, exerting physical effort), obesity, advanced age, menopause, past hysterectomies, crouching at labor, prolonged labor, and smoking are risk factors for POP(1,4). In the nulliparous young age population, prevalence is about 2%. The main risk factors are inherent defects in pelvic support (Ehler-Danlos syndrome, congenital shortness of vagina, and deep uterovesical and uterorectal pouches) (5). Additionally, a nabothian cyst might rarely lead to prolapse of genital organs in nulliparous women.

In this report, we describe the excision of a large nabothian cyst in a 20-year-old patient without any prior intercourse.

Case Report

A 21-year-old female patient without any prior intercourse presented with a complaint of a smooth-surfaced mass protruding out of her vagina (Figure 1). The first time she discovered a



Figure 1. Clinical presentation of cervical mass

mass protruding out of the vagina was around 2 years previously. She had no medical conditions in her medical history and no problem in her family history. General physical and systemic examinations were normal. During the inspection of genitals at the lithotomy position, the cervix was detected to pass 1 cm beyond the hymeneal line and there was a cystic mass with dimensions approximately 5x4 cm which originated from the cervix (Figure 2). Ultrasound exam showed that the uterus and



Figure 2. Cervical External Os and Nabothian Cyst

ovaries were normal. After the initial assessment, the patient gave her consent for surgical removal.

The large cystic mass was excised from the cervix under spinal anesthesia (Picture 3). Inside, the mass was completely filled with a white mucinous substance (Picture 4). After the cystectomy the cervix was elevated 2 cm up from the hymen so prolapse surgery was no longer needed. After the procedure, the patient was discharged at postoperative 1st day. Prolapse in the pelvic organs was not observed at the follow-up visit 4 weeks after the surgery. Histopathological examination revealed a nabothian cyst.



Figure 3. Mucus filled cystic mass

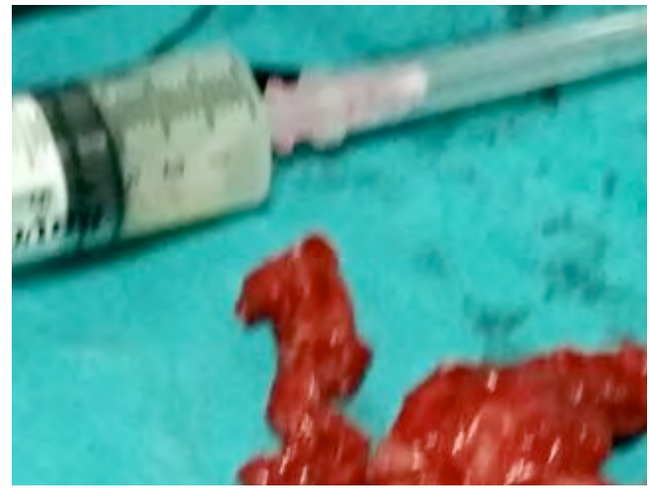

Figure 4. Cyst wall after excision

Discussion

A nabothian cyst is a benign, mucus filled cyst of the cervix and generally occurs at reproductive age. The size of the cysts may vary from microscopic dimensions to several centimeters. Most of them are asymptomatic and may appear translucent or opaque (5,6).

Nabothian cysts usually disappear without intervention. The main indications for surgery are size-related symptoms such as pain, feeling of pressure in the vagina, and prolapse.

The most common period to encounter a nabothian cyst in a woman is menopausal age. It may be seen rarely in nulliparous or women with an intact hymen. Non-obstetric risk factors in young women for symptomatic pelvic organ prolapse: deficient connective tissue, high body mass index (BMI), family history

of prolapse, asthma and chronic cough, chronic constipation, straining in defecation, variations of anatomy, and collagen synthesis and structure(7).

Large nabothian cysts may cause prolapse and as their size grows, they require histopathological evaluation to rule out any malign process (8).

Additionally, uterine prolapse may lead to urinary retention and subsequently this may lead to obstruction during labor or hydronephrosis(9).

In nulliparous women and in women with an intact hymen, POP is seen quite rarely. There is one other case in the literature (5). As this study and our report suggest, cystectomy should be the first step and a decision for a sling operation might be made according to the degree of POP after the cystectomy surgery.

In patients presenting with pelvic organ prolapse, it should be kept in mind that a benign or malignant cervical mass might accompany the situation and the decision to perform a surgical intervention with the purpose of correcting the prolapse should only be made after the cervical mass is totally removed.

Consent

The authors declare that written informed consent was obtained from the patient for publication of this case report with accompanying images.

Competing interests

The authors declare that they have no competing interests.

References

1. Gunasekera P, Sazaki J, Walker G. Pelvic organ prolapse: don't forget developing countries. Lancet 2007;369:1789–90.
2. Fitchett JR, Bhatta S, Sherpa TY, Malla BS, A Fitchett EJ, Samen A.et al.Non-surgical interventions for pelvic organ prolapse in rural Nepal: a prospective monitoring and evaluation study. JRSM Open 2015;3;6(12):2054270415608117.
3. Shrestha B, Onta S, Choulagai B, Paudel R, Petzold M, Krettek A. Uterine prolapse and its impact on quality of life in the Jhaukhel-Duwakot Health Demographic Surveillance Site, Bhaktapur, Nepal. Glob Health Action 2015;10(8):28771.
4. Fritel X, Varnoux N, Zins M, Breart G, Ringa V. Symptomatic pelvic organ prolapse at midlife, quality of life, and risk factors. Obstet Gynecol 2009;113:609–16.
5. Nigam A, Choudhary D, Raghunandan C. Large nabothian cyst: a rare cause of nulliparous prolapse. Case Rep Obstet Gynecol 2012;2012:192526.
6. Vural F, Sanverdi I, Coskun AD, Kusgöz A, Temel O. Large Nabothian Cyst Obstructing Labour Passage. J Clin Diagn Res 2015;9(10):6-7.
7. Miedel A, Tegerstedt G, Maehle-Schmidt M, Nyrén O, Hammarström M. Non-obstetric risk factors for symptomatic pelvic organ prolapse. Obstet Gynecol 2009;113(5):1089-97.
8. Clement PB, Young RH. Deep nabothian cysts of the uterine cervix. A possible-source of confusion with minimal-deviation adenocarcinoma (adenoma malignum). IntJ Gynecol Pathol 1989;8(4):340-8.
9. Kurt S, Guler T, Canda MT, Demirtas Ö, Tasyurt A. Treatment of uterine prolapse with bilateral hydronephrosis in a young nulliparous woman; a new minimally invasive extraperitoneal technique. Eur Rev Med Pharmacol Sci 2014;18(11):1657-60.

How to cite this article:
Çift T, Korkmazer E, Nizam R, Olgun M, Şenkutlu B. Large Nabothian Cyst: Manifestation with Pelvic Organ Prolapse in a Nulliparous Patient. J Clin Anal Med 2016;7(suppl 3): 262-4.