Late Onset Spinal Epidural Abscess After Spinal Anesthesia in a Patient With Anklosing Spondylitis: A Case Report

Ankilozan Spondilitli Hastada Spinal Anestezi Sonrası Geç Dönemde Ortaya Çıkan Spinal Epidural Abse: Olgu Sunumu

Spinal Epidural Abscess

Çağatay Özdöl, Tolga Gediz
Neurosurgery Clinic, Antalya Education and Research Hospital, Antalya, Turkey

Özet

Çalışmamızda sırt, bel ağrısı ve birkaç gündür gelişen bacaklarda güçsüzlük yakınmaları ile acil servise başvuran 61 yaşındaki bir kadın hastayı sunduk. Hastanın hikayesinde travma öyküsü yoktu. Özgeçmişinde 35 yıldır ankilozan spondilit hastası olduğu öğrenildi. Buna ek olarak yaklaşık 2 ay önce spinal anesteziyle total kalça protezi operasyonu geçirdiği öğrenildi. Manyetik rezonans görüntülemede T11-T12 seviyelerinde spinal epidural alanı tutan kitle mevcuttu. Hastanın nörolojik bulguları acil yapılan cerrahi dekompresyon sonrası belirgin olarak toparladı. Spinal epidural abseler spinal anestezinin nadir komplikasyonlarından biridir ve özellikle torakal bölgede görülme sıklığı çok nadirdir. Bu tür vakalarda birincil tedavi cerrahi dekompresyon ve antibiyotik tedavisidir. Nörolojik prognoz 72 saati geçen vakalarda genellikle umut verici değildir.

Anahtar Kelimeler

Ankilozan Spondilit; Epidural Abse; Spinal Anestezi; Cerrahi

Abstract

In this study we present a 61-year-old female patient who was admitted to the hospital with dorsal and lower back pain and recent paraparesis. There was no history of trauma. She was admitted to the hospital due to suffering from ankylosing spondylitis for the past 35 years. Moreover, she had undergone a total hip replacement 2 months prior under spinal anesthesia. Magnetic resonance imaging revealed spinal cord compression due to a mass lesion involving the spinal epidural region at the T11 to T12 level. There were also some imaging findings attributable to discitis. The patient's neurological condition required an urgent surgical decompression. Spinal epidural abscess is an uncommon complication of spinal anesthesia and invovement of the thoracic region is even rarer. Surgical decompression and antibiotherapy are the treatments of choice for patients with spinal epidural abscesses. Neurological prognosis is generally not promising, particularly when treatment is not begun within the first 72 hours.

Keywords

Ankylosing Spondylitis; Epidural Abscess; Spinal Anesthesia; Surgery

DOI: 10.4328/JCAM.4773 Received: 31.07.2016 Accepted: 25.08.2016 Printed: 01.06.2016 J Clin Anal Med 2016;7(suppl 3): 265-7
Corresponding Author: Çağatay Özdöl, Neurosurgery Clinics, Antalya Education and Research Hospital, 07100, Muratpaşa, Antalya, Turkey.
T.: +90 2422494400 F.: +90 2422494462 E-Mail: drcagatayozdol@gmail.com

Introduction

Spinal infections can manifest in various clinical conditions such as vertebral osteomyelitis, epidural empyema, discitis, and intramedullary abscess [1]. Clinical findings vary according to infection site, extent, chronicity, or pathologic agent [1]. Infections may spread either by hematogenous dissemination or direct extension [2]. Comorbidities such as diabetes mellitus, chronic alcoholism, intravenous drug abuse, chronic renal failure, recent spinal or epidural procedures, recent spinal trauma or surgery, and chronic corticosteroid use are potential risk factors for spinal infections [3]. The peak incidence occurs in the sixth and seventh decades of life [4].

We describe a rare case of late onset spinal epidural abscess (SEA) after spinal anesthesia in a patient with ankylosing spondylitis.

Case Report

A 61-year-old female patient was admitted with dorsal and lower back pain and paraparesis, which had started a week prior and progressed. She had a history of ankylosing spondylitis for 35 years; her medical treatment included corticosteroids. She also reported a surgery for total hip replacement 2 months prior that was performed under spinal anesthesia, at the L4-5 level according to hospital records. The records also revealed that the induction of spinal anesthesia was difficult and spinal puncture had to be repeated three times. Neurological examination of the patient, who did not have a personal history of trauma, revealed a Medical Research Council Scale for Muscle Strength grade 0/5 motor strength in the right, 2/5 in the left lower extremity muscle groups and complete numbness below the T11 sensory level. There was hyperreflexia in deep tendon reflexes, such as the knee and ankle jerk tests. There were no dermatological signs on the skin where spinal anesthesia was performed.

The patient was not febrile at the time of admission. The erythrocyte sedimentation rate (ESR) was 56 mm/h (normal range, 0-26 mm/h), and highly sensitive C- reactive protein (CRP) was 94.3 mg/L (normal range, <8.0mg/L). All other blood test results were within normal limits.

X-rays showed the classical bamboo spine appearance of ankylosing spondylitis and sclerosis (Figure 1). Magnetic resonance imaging (MRI) of the whole spine revealed a ventral spinal epidural mass extending from T11 to T12 vertebrae causing significant compression of the spinal cord in the thoracic region (Figure 2). Discitis at the T11-12 disc level was also present (Figure 3).

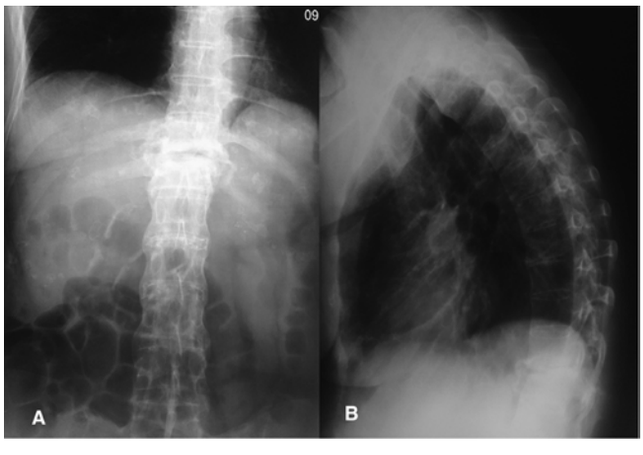

Figure 1. Dorso-lumbar antero-posterior and lateral radiographs show complete fusion of the lumbar vertebral bodies (Bamboo spine appearance).

Due to the patient's neurological condition, urgent surgical decompression was performed. The patient underwent total laminectomy of T11. Both of the T11 nerve roots were surrounded by a solid granulomatous lesion. The epidural space was explored and the lesion was totally removed, while the nerve roots were protected. Contrary to our expectation of pyogenic abscess, a thick soft tissue of rubber consistency was observed and removed.

Microbiological cultures including Mycobacterium tuberculosis and brucellosis were negative. Antibiotherapy with ceftriaxone was started and continued for 6 weeks. There were 100X: 15-16 leucocytes (%90 PMNL) in color microscope. Histopathology revealed fibrosis and chronic lymphohistiocytic inflammatory cell infiltration in the soft tissues consistent with infection.

The postoperative period was uneventful and after nearly six months of rehabilitation the patient was able to walk independently. Medical Research Council Scale for Muscle Strength grade was 4/5 motor strength bilaterally in the lower extremity muscle groups.

Discussion

SEA is an uncommon complication of spinal anesthesia [5]. Historical rates of SEA range from 0.2 to 1.2 cases per 10,000 hospital admissions [5]. Pathogenic microorganisms can be introduced into the epidural space through hematogenous seeding, direct spread from contiguous structures, or through direct

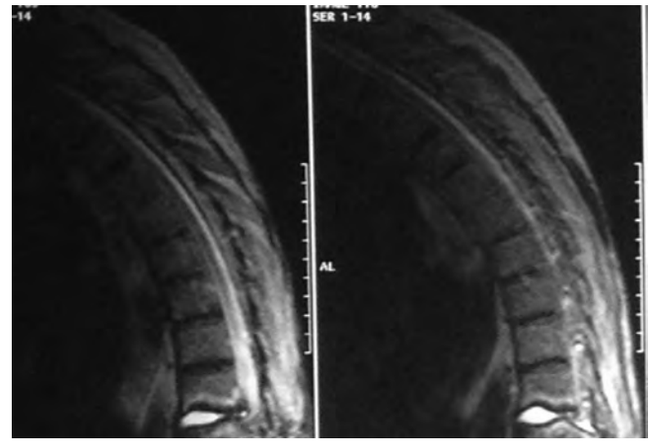

Figure 2. T2-weighted sagittal MRI demonstrates findings consistent with discitis at T11 and T12 disc level and associated subligamentous abscess extending into the spinal canal at T11 and T12 with cord compression and severe central canal stenosis at these levels.

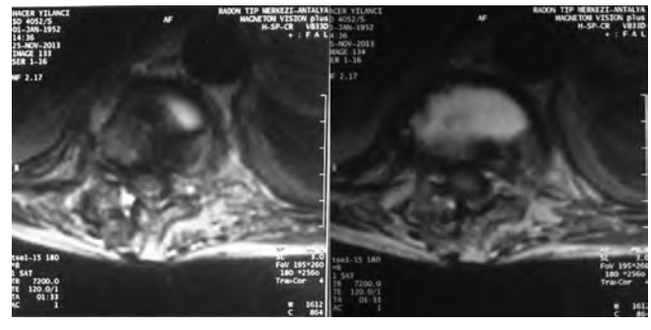

Figure 3. T2-weighted axial MR images at T11 and T12 show an epidural abscess extending into the spinal canal with cord compression and sever central canal stenosis.

inoculation from invasive procedures. In this case, since the location of the spinal anesthesia needle entry point was not close to the epidural abscess, hematogenous seeding seems to be a more probable route.

Diabetes, malignancy, dialysis-dependent chronic renal disease, AIDS, and corticosteroid use are well-established causes of immunosuppression that are associated with spinal epidural abscess as well as other systemic and local infections. We believe that the autoimmune spondyloarthropathy was the predisposing factor in this case.

SEA is classified as acute, sub-acute, or chronic form [5]. Microorganisms that cause the chronic form of SEA are generally less virulent. In this form, as was the case in our patient, fever, leukocytosis, or spinal tenderness usually are not present but back pain always is [5]. Staphylococcus aureus is the most common infectious agent responsible for spinal epidural abscesses [6]. However culture results can be negative in nearly 10% of all the cases [6].

Spinal epidural abscesses most often occur at the lumbar level (48%), followed by the thoracic (31%) and cervical levels (21%) [7]. In our case, the abscess occurred in the thoracic spinal epidural space. Panagiotopoulos et al. have found that 69% of spinal epidural abscesses were located anterior, 17% posterior, and 14% anteroposterior to the cord [8]. The abscess in our case was located anterior to the spinal cord.

The most sensitive method of diagnosis of a spinal epidural abscess is contrast-enhanced MRI with gadolinium [6]. In addition to its ability to depict soft tissues, MRI is superior at identifying alternative pathologies such as neoplasms. In the MRI, the contrast-enhancing pattern of spinal epidural abscess can be either homogeneous or peripheral. The typical MRI appearance is a dense homogenous contrast-enhancing pattern, as observed in our case. MRI myelogram shows equal sensitivity in diagnosis of spinal epidural abscesses (91-92%). In our case, MRI myelogram showed a total block on the T11-12 level (Figure 4).



Figure 4. MRI myelogram shows total block on the T11-12 level.

Surgical decompression and antibiotherapy are the treatments of choice for patients with spinal epidural abscesses. Empirical antibiotherapy should be started immediately after surgical decompression until the culture results are obtained. Neurological prognosis is significantly poor in patients who are not treated within the first 72 hours. The mortality rate is 5-10% because of delay; early detection of the pathology significantly reduces morbidity and mortality rates.

Our patient was operated on immediately after she was admitted to the hospital and empirical antibiotherapy was started immediately after the decompression.

Spinal epidural abscesses should be included in the differential diagnosis in patients with severe dorsal or lower back pain who have predisposing risk factors such as diabetes mellitus, chronic renal failure, or autoimmune diseases, and who have had spinal anesthesia. In such cases, diagnosis should be carried out promptly and appropriate treatment should be initiated without any delay. The gold standard of treatment is a combination of decompression surgery and antibiotherapy.

Competing interests

The authors declare that they have no competing interests.

References

1. Strauss I, Carmi-Oren N, Hassner A, Shapiro M, Giladi M, Lidar Z. Spinal epidural abscess: in search of reasons for an increased incidence. Isr Med Assoc J 2013; 15(9):493-6.
2. Graham SM, Fishlock A, Millner P, Sandoe J. The management gram negative bacterial haematogenous vertebral osteomyelitis: a case series of diagnosis, treatment and therapeutic outcomes. Eur Spine J 2013;22(8):1845-53.
3. Curry WT Jr, Hoh BL, Amin-Hanjani S, Eskandar EN. Spinal epidural abscess: clinical presentation, management, and outcome. Surg Neurol 2005;63(4):364-71.
4. Hwang DW, Lee CW, Nam HT, Kim BM, Choi HJ. Long level (t4-l1) spinal epidural abscess in a diabetic patient - a case report. Asian Spine J 2008;2(1):55-8.
5. Horlocker TT, Wedel DJ. Infectious complications of regional anesthesia. Best Pract Res Clin Anaesthesiol 2008; 22(3):451-75.
6. Connor DE Jr, Chittiboina P, Caldito G, Nanda A. Comparison of operative and nonoperative management of spinal epidural abscess: a retrospective review of clinical and laboratory predictors of neurological outcome. J Neurosurg Spine 2013;19(1):119-27.
7. Choi CH, Kim HJ, Pai HJ, Park YS. Cervical and thoracolumbar epidural abscess -a case report. J Korean Spine Surg 2007;14(2):105-9.
8. Panagiotopoulos V, Konstantinou D, Solomou E, Panagiotopoulos E, Marangos M, Maraziotis T: Extended cervicolumbar spinal epidural abscess associated with Paraparesis successfully decompressed using a minimally invasive technique. Spine 2004;29:300-3.

How to cite this article:
Özdöl Ç, Gediz T. Late Onset Spinal Epidural Abscess After Spinal Anesthesia in a Patient With Anklosing Spondylitis: A Case Report. J Clin Anal Med 2016;7(suppl 3): 265-7.