Acute Uterine Inversion Leading to Postpartum Bleeding: Case Report

Postpartum Kanamaya Neden Olan Akut Uterin İnversiyon: Olgu Sunumu

Acute Uterine Inversion

Muzeyyen Uyanık[1], Ozlem Oruc Sener[1], Ergun Uyanık[2]
[1]Obs&Gyn, VM Medical Park Hospital, [2]Obs&Gyn, Bursa Yuksek Ihtisas Training and Research Hospital, Bursa, Turkey

Öz

Akut uterin inversiyon doğumun üçüncü evresinde nadir olarak görülebilen bir obstetrik acildir. Uterin inversiyon sıklığı 1200 -57000 'de bir doğum arasında değişmektedir. İnversiyon durumunda kan kaybı ve şok gelişebilmesi nedeni ile maternal mortalite gelişebileceğinden erken tanı ve erken müdahale önemlidir. Tanı klinik olarak koyulurken, uterin inversiyon geliştiğinde henüz en iyi yaklaşım netlik kazanmamış olsa da cerrahi olmayan manuel manevralar ile çeşitli cerrahi yaklaşımlar uygulanmaktadır. Biz bu vakada multipar bir hastada normal doğum sonrası 2. derece uterin inversiyon olup kanama ve atoni gelişmesi üzerine laparatomi ile uterusun normal hale getirilmesi olgusunu sunmayı amaçladık. 26 yaşında multipar (G3P2) hasta, 39. haftasında düzenli sancı şikayeti ile acil servise başvurmuş ve yapılan vajinal muayenesinde poşu mevcut ,4-5 cm %80 açıklık saptanması üzerine doğumhaneye kabul edilmiştir. Düzenli ağrıları olması sebebi ile spontan takip edilmiştir. Doğum 5 saat içinde gerçekleşmiş ve 3060 gr sağlıklı kız bebek dünyaya gelmiştir. Plasenta çıkmadan bir kez fundusa Crede manevrası uygulanmış ve 10 dakika içerisinde plasenta kendiliğinden ayrılmıştır. Plasenta ayrılmasını takiben aşırı uterin kanama izlenmiş , vajinal ekartör ile kanama kontrolü yapılırken miyoma uteri zannedilen , fakat uterin masajda fundusun hissedilmemesi üzerine uterin inversiyondan şüphenilerek manuel olarak inversiyon düzeltilmeye çalışılmış fakat başarılı olamayınca ve kanamanın fazla olması nedeni ile hasta ameliyathaneye alınmış ve laparatomi yapılarak redüksiyon sağlanmıştır. Histerektomi' ye gerek kalmamıştır. Hastanın genel durumunun iyi olması üzerine 4 gün sonra hasta şifa ile taburcu edilmiştir. Uterin inversiyon uterin fundusun ters dönerek serviksten dışarı çıkması durumudur. İnversiyonu hazırlayıcı faktörler kesin olarak bilinmediğinden öngörmek mümkün olmamaktadır. Tanı klinik olarak koyulurken, uterin inversiyon geliştiğinde henüz en iyi yaklaşım net olmasa da cerrahi olmayan manuel manevralar , medikal tedavi ve çeşitli cerrahi yaklaşımlar uygulanmaktadır. Özetle, postpartum kanama nedeni ve bir obstetrik acil olan uterin inversiyon nadir olarak görülse de ,oluştuğunda erken tanı konması ve kötü prognoz oluşmasını önlemede erken müdahale ve tedavi yaklaşımlarını bilmek çok önemlidir.

Anahtar Kelimeler

Obstetrik Acil; Uterin Kanama; Uterin İnversiyon

Abstract

Acute uterine inversion is an obstetric emergency that is a rare occurrence in the third stage of labour. The incidence of uterine inversion ranges from 1/1200 to 1/57000 deliveries. Early recognition and appropriate intervention are important as it may cause maternal mortality due to loss of blood and shock. While making a clinical diagnosis, various surgical approaches along with nonsurgical manual maneuvers are performed even if the best approach is not determined at the time of uterine inversion. We aimed to report the case of there positioning of the uterus of a multiparous patient by laparotomy following postpartum hemorrhage and atony caused by second degree uterine inversion following a vaginal delivery. A 26-year-old multiparous (G3P2) patient came to the emergency room with regular contractions in her 39 th week. She was hospitalized following examination performed as membrane intact and 4-5 cm 80% dilation were determined. She was followed up regularly due to her regular pains. She gave birth to a healthy baby girl weighing 3060 grams in five hours. The Crede maneuver had been executed once before the placenta came out, and placental separation took place within ten minutes. Following the placental separation, excessive uterine bleeding was observed. When performing bleeding control with a vaginal extractor, the patient was suspected of having myoma uteri. However, since the fundus could not be felt during the uterine massage and uterine inversion was thought to exist, manual repositioning of the uterus was performed without any success. The patient was taken to the operating room due to excessive bleeding that was reduced following laparotomy. Hysterectomy was not needed. The patient was discharged after four days with good general health. Uterine inversion is the state in which the uterine fundus reverses and extends beyond the cervix. It is not possible to foresee inversion as the factors that trigger inversion are not fully known.When uterine inversion occurs, while making a clinical diagnosis, medical treatment and various surgical approaches along with nonsurgical manual maneuvers are performed even when the best approach is not determined at the time of uterine inversion.To sum up, though uterine inversion is a rare obstetric emergency that causes postpartum bleeding, early recognition and appropriate intervention are essential to prevent poor prognosis.

Keywords

Obstetric Emergency Uterine Bleeding; Uterine Inversion

DOI: 10.4328/JCAM.4909 Received: 10.01.2017 Accepted: 25.01.2017 Printed: 01.02.2017 J Clin Anal Med 2017;8(suppl 1): 35-7
Corresponding Author: Muzeyyen Uyanik, Department of Obs&Gyn. VM Medical Park Hospital, Osmangazi, Bursa, Turkey.
GSM: +905438090882 E-Mail: drmuzeyyenuyanik@gmail.com

Introduction

Acute uterine inversion is an obstetric emergency that is a rare occurrence in the third stage of labour. Uterine inversion is described as the state in which the uterine fundus reverses and extends beyond the cervix. The incidence of uterine inversion ranges from1/1200 to 1/57000 deliveries [1-3]. Early recognition and appropriate intervention are important as it may cause maternal mortality due to loss of blood and shock [4]. Symptoms are similar to those of tumoral mass or myoma uteri incases of first and second degree inversion [5]. When uterine inversion occurs, uterine reduction can be achieved with the help of various surgical approaches along with nonsurgical manual maneuvers even if the best approach is not known at the time of uterine inversion.We aimed to present the case of repositioning the uterus by laparatomy due to the development of a second degree uterine inversion, bleeding and atony in a multiparous patient following vaginal delivery, including the approach to the atony that developed and the description, etiology, risk factors, diagnosis and treatment of inversion.

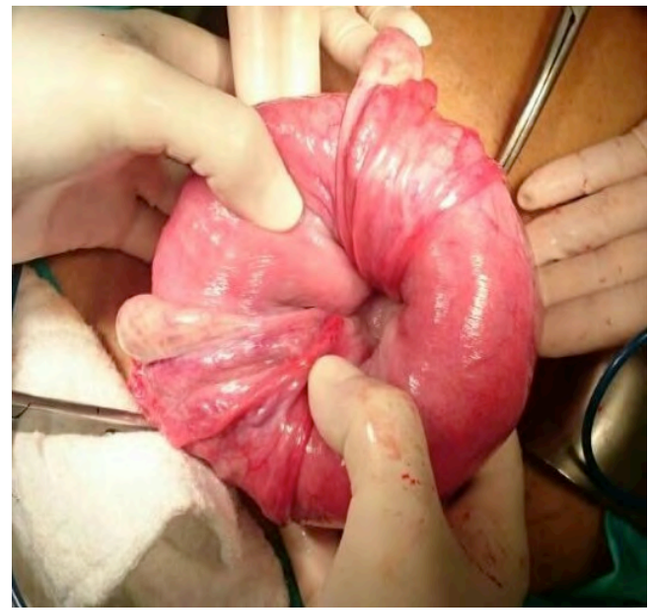

Picture 1.

Case Report

A 29-year-oldmultiparous (G3P2) patient came to the emergency room with regular contractions in her 39 th week and was hospitalized following her examination as membrane intact and 4-5 cm 80% dilation were determined. She had regular check-ups during pregnancy and did not have any illnesses. The stages of labour were followed as her fetal Non-Stress Test (NST) was reactive and she had regular contractions. Spontaneous rupture of the membrane occurred when the cervix was dilated to 7 cm. The delivery took five hours and she delivered a healthy baby girl weighing 3060 grams. Before the placenta came out, the Crede maneuver was executed once and placental separation took place within ten minutes. Following placental separation, excessive uterine bleeding was observed. When performing bleeding control with a vaginal extractor, no cervical os was monitored, yet there were masses resembling myoma uteri. However, since the fundus could not be felt during the uterine massage and uterine inversion was thought to exist, manual repositioning of the uterus was performed without any success. The patient was taken to the operating room due to excessive bleeding. The manual inversion was attempted again under general anesthesia, but it was an unsuccessful attempt. Laparotomy had to be performed. When the abdomen was opened with a Pfannenstiel incision, uterine inversion was determined (Picture 1). Haultain technique was performed due to the contraction ring, and the inversion was corrected. As atony and bleeding continued, the patient underwent an HB control (input Hb:11.2 hgb) with 6 hGb and was given a supportive treatment with 4 units of erythrocytes and 2 units of fresh frozen plasma replacement and uterotonic agents. As the bleeding continued after B- Lynch suture was applied to the uterus, bilateral hypogastric artery ligation was performed. Because the bleeding stopped without the need for a hysterectomy and atony was corrected, the abdomen was closed by placing a drain. The patient was discharged after four days with good general health.

Discussion

Uterine inversion is the state in which the uterine fundus reverses and extends beyond the cervix. Though it may occur during normal or cesarean delivery, approximately 5% of the inversions occur spontaneously and independently of puerperium [6]. Uterine inversion is classified according to the degree of inversion: 1st degree (the fundus is inside the endometrial cavity), 2nd degree (the fundus protudes through the cervical os), 3rd degree (the fundus protudes to or beyond the introitus), 4th degree (both the uterus and vagina are inverted). Based upon the timing of inversion it is classified as acute (occurs within 24 hours of birth), subacute (occurring after 24 hours but within 4 weeks of birth) and chronic (occurs after 4 weeks) [7].

The incidence of uterine inversion ranges from 1/1200 to1/57000 deliveries [1-3]. Its pathogenesis is unclear, but the most likely causes are strong traction of the umbilical cord, fetal macrosomia, short umbilical cord, congenital anomalies of the uterus, excessive fundal massage (Crede maneuver),and fundal placenta [8,9].

Diagnosis of uterine inversion is based on clinical signs and symptoms. Uterine inversion is suspected if the uterine fundus is observed in the vaginal introitus or when the fundus is palpated and there is excessive postpartum blood loss, or in the absence of uterine fundus during abdominal palpation. If the physical examination is not definitive and the patient is hemodynamically stable, radiographic imaging (ultrasonography and magnetic resonance) can be used in diagnosis [10].

If intervention does not occur soon after diagnosis , hypovolemic shock may develop. After uterine inversion is diagnosed, to minimize blood loss and to avoid contraction rings uterine reduction should be attempted with rapid pressure on the fundus from the vagina. This is known as the Johnson maneuver. If the Johnson maneuver fails, the patient should be taken under the care of the surgical and anesthesia team. Another experienced gynecologist and operating room staff should be called for help. Complete blood count and coagulation parameters should be studied while intravenous fluid is administered to the patient. Preparation of the blood products should be quickly performed. If uterine reduction fails even after uterine relaxants (nitroglycerine, terbutaline, magnesium sulphate and inhaler anesthetic

agents such as sevoflurane, desflurane, andisoflurane) are given, surgical approach is performed [11,12]. Methods such as laparoscopic assisted reduction, vaginal surgical approach, reduction using an obstetric vacuum, or hydrostatic reduction can be used, but asurgical approach with Huntington and Haultain techniques is applied most frequently [13,14,15]. The less invasive Huntington technique is recommended [7]. This method involves pulling bilateral ligaments by holding them with Allis clamps. Withdrawal is repeated when the other surgeon, if there is one, pushes through the vaginal route. Since this method generally fails when there is a contraction ring,the other surgical method, Haultain technique is used. In this method, after an anterior or posterior incision is made in the contraction ring, reduction is achieved manually. First the incision is sutured. The same method performed vaginally has beendescribed by Spinelli but no significant success has been observed in acute inversion cases. Hysterectomy is performed if reduction cannot be achieved by any of these methods [14].

Though controversy exists about the time when the placenta should be removed if it fails to separate, it is commonly suggested that removal of the placenta after correction will result in decreased blood loss [16].

A single dose 1st generation cephalosporin antibiotic prophylaxis is recommended to prevent the development of endometritis after reduction has been achieved. From uterotonic agents oxytoxin (20-40 units), misoprostol 800 micrograms intravaginally, dinoprostone 20 mg rectally, or methylergonovine 200 micrograms should be administered intramuscularly in a maximum of 4 doses to prevent atony development [17].

In conclusion, although uterine inversion is a rare obstetric emergency that causes postpartum bleeding, early recognition and appropriate intervention are essential to prevent poor prognosis.

Competing interests

The authors declare that they have no competing interests.

References

1. Morini A, Angelini R, Giardini G. Acute puerperal uterine inversion: a report of 3 cases and an analysis of 358 cases in the literature. Minerva Ginecol 1994; 46:115-27.
2. Baskett TF. Acute uterine inversion: a review of 40 cases. J Obstet Gynaecol Can 2002; 24:953-6.
3. Witteveen T, Van Stralen G, Zwart J, et al. Puerperal uterine inversion in the Netherlands: a nationwide cohort study. Acta Obstet Gynecol Scand 2013; 92:334-7.
4. Watson P, Bejch N, Bowes V.A. Jr. Management of acute and subacute puerperal inversion of the uterus. Obstet. Gynecol 1980;55:12-6.
5. Occhionero M, Restaino G., Ciuffreda M, et al. Uterine inversion in association with uterine sarcoma: a case report with MRI findings and review of the literature. Gynecol Obstet Invest 2012;73:260-4.
6. Lupovitch A, England ER, Chen R. Non-puerperal uterine inversion in association with uterine sarcoma: case report in a 26-year-old and review of the literature. Gynecol Oncol 2005; 97:938-41.
7. Repke J, Ramin S, Barss V. Puerperal uterine inversion. Up to Date.com Nov-2016.
8. Lipitz S, Frenkel Y. Puerperal inversion of the uterus. Eur J Obstet Gynecol Reprod Biol 1988; 27:271-4.
9. Deneux-Tharaux C, Sentilhes L, Maillard F, et al. Effect of routine controlled cord traction as part of the active management of the third stage of labour on postpartum haemorrhage: multicentre randomised controlled trial (TRACOR). BMJ 2013; 28:346-f1541.
10. Hsieh TT, Lee JD. Sonographic findings in acute puerperal uterine inversion. J Clin Ultrasound 1991; 19:306-9.
11. Smith GN, Brien JF. Use of nitroglycerin for uterine relaxation. Obstet Gynecol Surv 1998; 53:559-65.
12. Yoo KY, Lee JC, Yoon MH, et al. The effects of volatile anesthetics on spontaneous contractility of isolated human pregnant uterine muscle: a comparison among sevoflurane, desflurane, isoflurane, and halothane. Anesth Analg 2006; 103:443-45.
13. Shepherd LJ, Shenassa H, Singh SS. Laparoscopic management of uterine inversion. J Minim Invasive Gynecol 2010; 17:255-7.
14. Antonelli E, Irion O, Tolck P,et al. Subacute uterine inversion: description of a novel replacement technique using the obstetric ventouse. BJOG 2006; 113:846-7.
15. Tan KH, Luddin NS. Hydrostatic reduction of acute uterine inversion. Int J Gynaecol Obstet 2005; 91:63-4.
16. You W., Zahn C. Postpartum hemorrhage: abnormally adherent placenta,uterine inversion and puerperal hematomas. Clin Obstet Gynecol 2006;49:184-97.
17. Adesiyun A. Septic postpartum uterine inversion. Singapore Med J 2007;48:943-5.

How to cite this article:
Uyanık M, Sener OO, Uyanık E. Acute Uterine Inversion Leading to Postpartum Bleeding: Case Report. J Clin Anal Med 2017;8(suppl 1): 35-7.