Hip Ultrasonography in Classification of Proximal Focal Femoral Deficiency: Two Case Reports

Proksimal Fokal Femur Yetmezliği Sınıflamasında Kalça Ultrasonografisi: İki Olgu Sunumu

Proximal Focal Femoral Deficiency

Ümit Yaşar Ayaz[1], Sevin Ayaz[2], Mehmet Ercüment Döğen[1], Baki Hekimoglu[3]
[1]Department of Radiology, Mersin Women's and Children's Hospital, Mersin,
[2]Department of Medical Imaging Techniques, Toros University, Vocational School; Department of Nuclear Medicine, Mersin State Hospital, Mersin,
[3]Department of Radiology, Dışkapı Yıldırım Beyazıt Training and Research Hospital, Ankara, Turkey

*Presented in 22nd International Congress of Radiology, July 1-5, 2002 in Cancun, Mexico.

Özet

Proksimal fokal femur yetmezliği (PFFY) bulunan iki infantta femur başlarını sonografik olarak göstermeyi ve ultrasonografi (US) katkısı ile PFFY sınıflaması yapmayı amaçladık. Sağ uyluğunda kısalık bulunan yedi aylık erkek olgunun (Olgu 1) radyografisinde sağ femurun proksimal yarısında belirgin hipoplazi saptandı. Aynı taraf asetabulum displazikti. US'de femur başı hipoplazikti. Sağ uyluğunda kısalık bulunan 16 günlük erkek olgunun (Olgu 2) radyografisinde sağ femurun sola kıyasla daha kısa ve ince olduğu görüldü. Aynı taraf asetabulumun gelişimi yeterliydi. US'de femur başı normaldi. US, PFFY'li infantlarda kıkırdak femur başlarının durumunu göstererek Olgu 1 ve Olgu 2'nin, sırasıyla Aitken sınıf C ve A olarak sınıflandırılmasına yardımcı olmuştur. US, radyografi ile birlikte PFFY sınıflamasında ve diğer kalça eklemini değerlendirmede kullanılabilir.

Anahtar Kelimeler

Süt Çocuğu; Ultrasonografi; Kalça Eklemi; Femur; Alt Ekstremite Deformiteleri, Doğumsal

Abstract

Our purpose was to sonographically demonstrate the femoral heads of two infants with proximal focal femoral deficiency (PFFD) and to classify PFFD with the contribution of ultrasonography (US). On the radiograph of Case 1, a seven-month-old male with a short right thigh, there was marked hypoplasia of the proximal half of the right femur. Ipsilateral acetabulum was dysplastic. On the US, the femoral head was hypoplastic. On the radiograph of Case 2, a 16-day-old male with a short right thigh, the right femur was shorter and thinner than the left femur. An adequate ipsilateral acetabulum was found. US revealed a normal femoral head. US helped the classification of Case 1 as Aitken class C and Case 2 as and Aitken class A, by demonstrating the status of cartilaginous femoral heads in PFFD. Combined with radiography, US can be used in the classification of PFFD and in the evaluation of the unaffected hip.

Keywords

Infant; Ultrasonography; Hip; Femur; Lower Extremity Deformities, Congenital

DOI: 10.4328/JCAM.4842 Received: 20.10.2016 Accepted: 17.11.2016 Printed: 01.06.2017 J Clin Anal Med 2017;8(suppl 3): 187-91
Corresponding Author: Ümit Yaşar Ayaz, Mersin Women's and Children's Hospital, Department of Radiology, Mersin, Turkey.
T.: +90 3242230701 GSM: +905377639442 F.: +90 3242230722 E-Mail: umityasarayaz@gmail.com

Introduction

Proximal focal femoral deficiency (PFFD) is a rare developmental disorder of the proximal segment of the femur and the acetabulum, resulting in a shortening of the affected limb and ensuing functional impairment. The incidence of PFFD was reported as one per 52,029 of the population (0.002%) [1]. According to the radiological classification proposed by Aitken [2], femoral head is present in class A PFFD, with an adequate acetabulum and a very short femoral portion. Initially, there is no bony fusion between that portion and the femoral head in Aitken class A PFFD. However, through skeletal growth and maturation, a bony fusion develops between the diaphysis of the femur and the head, neck, and trochanteric component. In Aitken Class C PFFD, the acetabulum is seriously dysplastic; the diaphysis of the femur is short with a tapered upper part; the femoral head is absent or very small with no connection with femoral diaphysis; and the femoral head (if present) never gets ossified [2]. Our aim in presenting the following two case reports was to ultrasonographically demonstrate the femoral heads of infants with PFFD, to present their plain radiography findings, and to classify them with the contribution of US data. Aitken's classification [2] was used as the reference.

Case Report 1

The male infant was seven months old on admittance, born at term after an uneventful pregnancy. No maternal risk factors including gestational diabetes or exposure to teratogenic agents during pregnancy were reported by the parents. Family history was unremarkable and there was no consanguinity. The physical examinations of the parents, including their limbs, were normal. The patient's parents were informed about the examination procedures and consent was obtained from them. All procedures were performed according to the World Medical Association Declaration of Helsinki (revised in 2000, Edinburgh). On physical examination of the infant, his right thigh was shorter than the left one and was bulky. The left leg, upper limbs, and face were normal. Physical examination, routine laboratory tests, and bone density evaluations revealed no systemic disease or rickets. On plain radiograph there was marked hypoplasia of the proximal 1/2 portion of the right femur with a tapered proximal end. The distal 1/2 portion of the right femur was thinner and shorter than that of the contralateral femur. The right acetabulum was dysplastic. There was a small notch superior to the right acetabulum, thought to represent a pseudoacetabulum formation. There was some superior displacement of the right femur; its tapered proximal end pointed to the pseudoacetabulum formation. On the left side, the acetabular angle was 41°, representing a relatively shallow acetabulum. Tibias and fibulas were present on both sides and no skeletal abnormality was observed in the left leg (Figure 1). On US images obtained by a 7.5 MHz linear-array transducer, a hypoplastic cartilaginous femoral head was demonstrated on the right side. Its diameter was 13.4 mm with no ossification center, while the left femoral head with an echogenic ossification center had a diameter of 19 mm. During the Barlow maneuver, US demonstrated that the right femoral head was superiorly displaced and located in an acetabulum-like depression on the iliac bone (Figure 2), concordant with the pseudoacetabulum

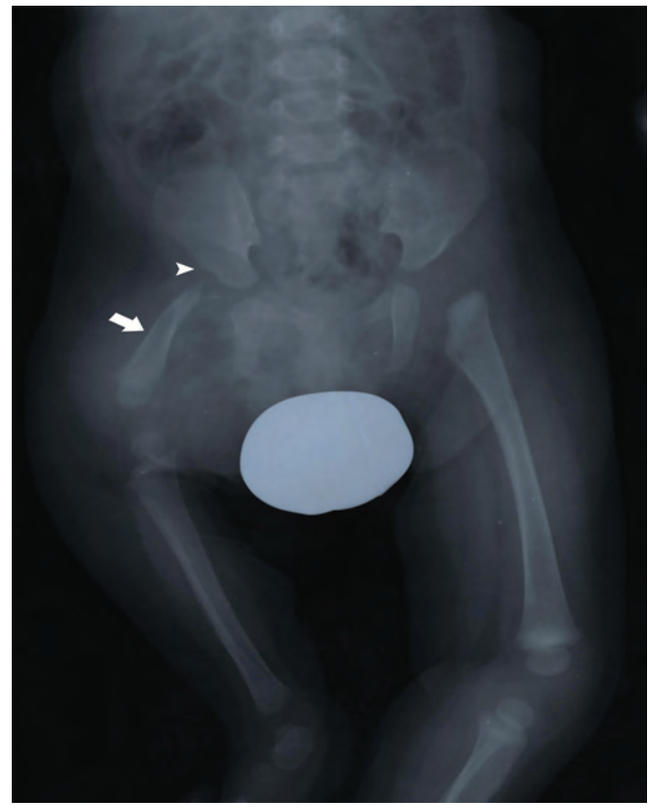

Figure 1. Anteroposterior plain radiograph of Case 1. Short and thin right femur with a tapered proximal end (white arrow). Ipsilateral acetabulum is dysplastic. Small notch superior to the right acetabulum was thought to represent a pseudoacetabulum (white arrowhead). Tibias and fibulas are present on both sides.

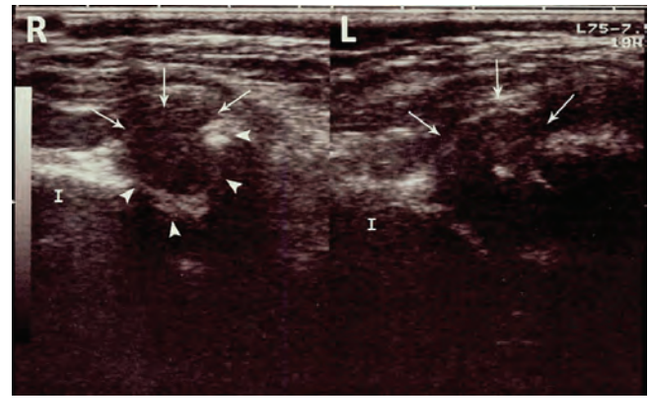

Figure 2. Coronal US views of both hips in Case 1 during Barlow maneuver (R: Right side, L: Left side, I: Iliac bone). Smaller cartilaginous femoral head on the right side (white arrows) with no ossification center and normal-sized femoral head on the left side (white arrows) with a tiny echogenic ossification center. Right femoral head is located in a notch on iliac bone, concordant with a pseudoacetabulum (white arrowheads), in which no hypoechoic Y cartilage could be demonstrated.

detected on plain radiograph. The left femoral head coverage (FHC) was 50% in neutral position and decreased to 38% during the Barlow maneuver. The presence of a dysplastic acetabulum with an ipsilateral hypoplastic cartilaginous femoral head that was lacking an ossification center suggested that the PFFD in the present case had features consistent with Aitken class C.

Case Report 2

The male infant was 16 days old on initial admittance. He was born at term after an uneventful pregnancy. His nonconsanguineous parents reported no maternal risk factors including gestational diabetes or exposure to teratogenic agents during pregnancy. Family history was unremarkable. The physical ex-

aminations of the parents including their limbs were normal. The patient's parents were informed about the examination procedures and gave their consent. All the procedures were performed according to the World Medical Association Declaration of Helsinki (revised in 2000, Edinburgh). On physical examination of the infant, his right thigh was shorter than the left one and was bulky. The left lower limb, upper limbs, and face were normal. His physical examination and routine laboratory tests revealed no systemic disease or rickets. On his first plain radiograph obtained on initial admittance, his right femur was shorter and thinner than the left femur. An adequate right acetabulum was found to be similar to the left acetabulum. There was a separate ossification center in the proximal portion of his right thigh representing the femoral neck (Figure 3), which was seen to have enlarged and to have fused with the more distal portion of the right femur four months later (Figure 4). Tibias and fibulas were present on both sides and no skeletal abnormality was observed on the left leg. On the last control radiograph obtained 12 months after the initial one, ossification centers of both femoral heads were visible and rather symmetrical. Right femoral length and thickness gradually increased and substantial improvement was observed. The right acetabular angle was 16° and the left acetabular angle was 30°, both within normal ranges (Figure 5). The first US examination performed by a 7.5 MHz linear-array transducer on initial admittance revealed a normal cartilaginous femoral head with no ossification center on the right side. Its diameter was 15.4 mm, close to the diameter of the left femoral head which was measured as 15.9 mm.



Figure 3. Anteroposterior plain radiograph of Case 2 on initial admittance. Right femur is short and thin (white arrow). Tibias and fibulas are present on both sides. A separate ossification center in more proximal portion of his right thigh representing the femoral neck is visible (white arrowhead).



Figure 4. Anteroposterior radiograph of Case 2, four months after initial radiograph. Enlarged ossification center (black arrow) is fused with more distal portion of the right femur. An increase in length and thickness of right femur is observed.

During the Barlow maneuver, the right FHC was 22.6% (Figure 6), concordant with marked subluxation and the left FHC was 31%, higher than the right one but also concordant with subluxation. With the Ortolani maneuver both femoral heads returned

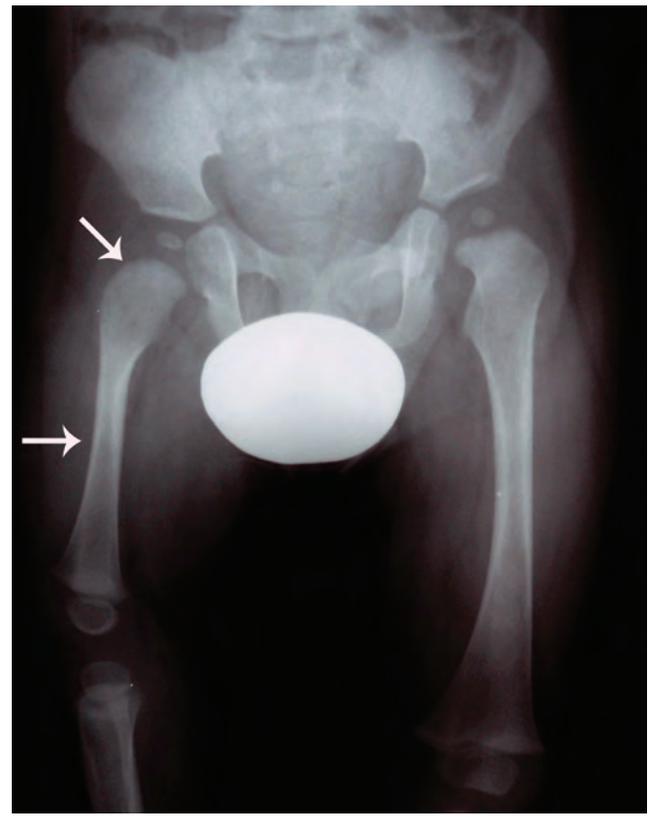

Figure 5. Anteroposterior radiograph of Case 2, 12 months after initial radiograph. Ossification centers of femoral heads are visible on both sides. Substantial improvement in development of right femur is observed (white arrows). Acetabular angles are within normal range on both sides.

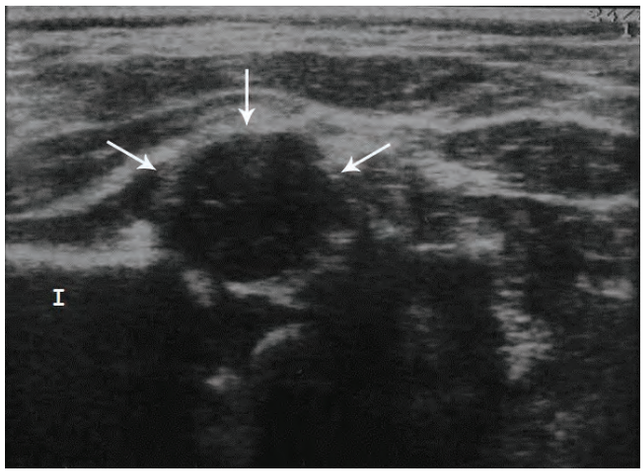

Figure 6. Coronal US view of the affected hip (right) in Case 2 during Barlow maneuver, obtained on initial admittance. Decreased femoral head coverage (FHC) and marked subluxation of cartilaginous femoral head (white arrows). I: Iliac bone.

to their resting positions. With the contribution of initial US findings, Case 2 was classified as Aitken class A. Four months later, control US revealed marked increase in FHC on both sides without any sign of overt subluxation, the right one being 48.2% (Figure 7) and the left one being 47.5% during the Barlow maneuver. On the last control US performed 12 months after the initial one, the right FHC was 49.2% (Figure 8) and the left FHC was 51% during the Barlow maneuver. Overt subluxation could not be detected on both sides. Eventually, follow-up data helped confirm the initial classification of the case as Aitken class A.

Discussion

The term PFFD is applied to a spectrum of conditions characterized by partial absence and shortening of the proximal femur(s). The pathology is mostly sporadic but familial PFFD cases have also been reported [3]. Aitken's classification [2] is most widely employed in both diagnosis and therapeutic planning. Radiological features of PFFD are present at birth. Except in the most severe cases, the distal end of the femur is usually normal. In milder forms (classes A and B), the femoral head and neck ossify and fuse, but a non-progressive subtrochanteric varus deformity is constant. In more severe types, the acetabulum and the femoral head are absent, an iliac bony projection is observed lateral to and above the dysplastic acetabulum, and the femoral diaphysis is either rounded, pointed proximally, or almost completely absent. In all four forms, the femur is prominently shortened. After age two, evaluation of plain radiographs and appropriate assignment into one of the four Aitken's classes become more feasible and more definitive than in infants below this age. The growth ratio of the abnormal to the normal limb throughout childhood is usually constant [4]. The Amstutz classification [5], another common classification system, has also been used in PFFD and has been applied to MRI [6].

To compensate for the inability of radiographs to demonstrate cartilage, MRI and US have been used to obtain more data in cases with PFFD [6–8]. Kayser et al. [7] reported that with US, the iliac line, femoral head, and greater trochanter could reliably be visualized in their patients with PFFD. In our cases, both the acetabuli and cartilaginous femoral heads could be evaluated using US, which helped us in classification of PFFD. Case 1 was a delayed case and the formation of a small pseudoacetabulum on the right side was thought to be due to a long-standing pressure effect of superiorly dislocated hypoplastic right femoral head on iliac bone. Though Case 1 had features consistent with Aitken class C, clinical follow-ups, control radiographs, and US examinations were recommended to the parents to verify the initial classification. Contact with the patient could not be established after the first examination, so we could not re-evaluate him. In Case 2, control US examinations revealed a normal-sized cartilaginous femoral head in its normal position on the affected side. We concluded that these features of Case 2 represented Aitken class A deformity, the mildest form of PFFD. Maldjian et al. [6] used MRI in diagnosis and classification of PFFD, stating that MRI was more accurate than radiographic evaluation for the classification of PFFD, particularly prior to the ossification of cartilaginous components in the femurs. MRI has perfect contrast resolution and it is superior to US in demonstrating all the bony elements (femoral

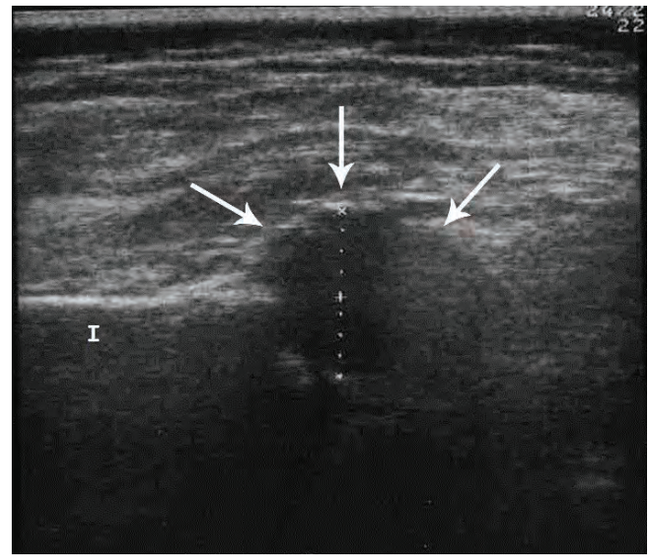

Figure 7. Coronal US view of the affected hip (right) in Case 2 during Barlow maneuver, obtained four months after the first US examination. Marked increase in FHC (calipers) without any sign of overt subluxation (white arrows). I: Iliac bone.

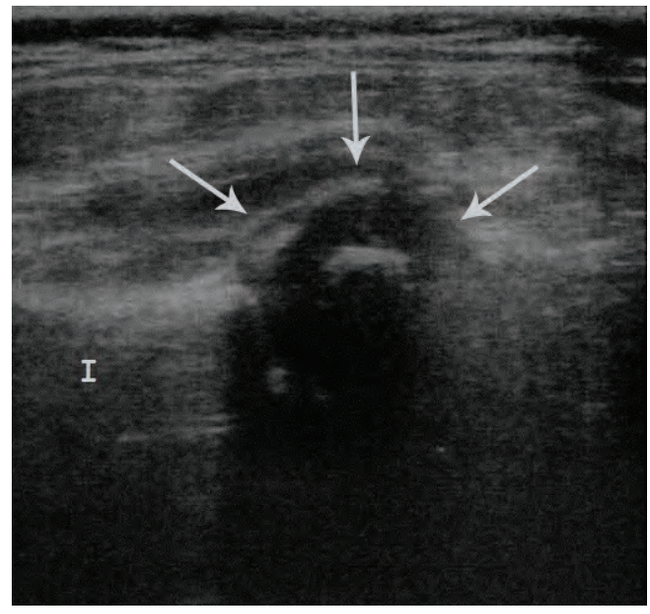

Figure 8. Coronal US view of the affected hip (right) in Case 2 during Barlow maneuver, obtained 12 months after the first US examination. Ossification center with posterior acoustic shadowing is visible in the center of femoral head. Marked increase in FHC without any sign of overt subluxation (white arrows). I: Iliac bone.

head, femoral neck and shaft, acetabulum, iliac bone) and cartilage together, in clearly depicting their relationship with each other, and in showing any impingement [8], regardless of any limiting factor experienced with US, such as adverse effects of tissue thickness and acoustic shadowing caused by bone. However MRI is more costly than US and sedation is required in infants. Among all the imaging modalities, US seems to be the most practical method to evaluate non-ossified femoral head in PFFD. Like MRI, US is also free of ionizing radiation, but unlike MRI, it does not require sedation and it is relatively less costly. US also provides real-time images during maneuvers applied in dynamic hip examination. US is particularly useful as a rapid and practical tool in the very first diagnosis and classification of PFFD, prior to detailed MRI examinations which are stressful for the infant and the family. But experience in assessment of infant hips with US is essential; otherwise, misdiagnosis would be inevitable due to drawbacks in imaging. In our cases, combined with the radiographs, US was sufficient to evaluate the existence, size, and position of cartilage femoral head, both on the affected and unaffected sides. But we consider that MRI and US can be performed together, particularly in indeterminate cases, to combine the advantages of both techniques and to more confidently make the classification.

In conclusion, US was useful both in demonstration of cartilaginous femoral heads and in evaluation of their diameters/positions in our two infants with PFFD. Combined with plain radiography findings, US can be used in the classification of the affected femur and in evaluation of the unaffected side to rule out the coexistence of a possible developmental hip dysplasia.

Competing interests

The authors declare that they have no competing interests.

References

1. Rogala EJ, Wynne-Davies R, Littlejohn A, Gormley J. Congenital limb anomalies: frequency and aetiological factors. Data from the Edinburgh Register of the Newborn (1964-68). J Med Genet 1974; 11(3):221–33.
2. Aitken GT. Proximal femoral focal deficiency-definition, classification and management. In: Aitken GT (ed). Proximal femoral focal deficiency. A congenital anomaly. Washington DC: National Academy of Sciences 1969:1–22.
3. Sen Gupta DK, Gupta SK. Familial bilateral proximal femoral focal deficiency. Report of a kindred. J Bone Joint Surg Am 1984; 66(9):1470–2.
4. Murray RO, Jacobson HG, Stoker DJ. The radiology of skeletal disorders. 3rd ed. Edingburg: Churchill Livingstone, 1990;37–8.
5. H. C.Amstutz. The morphology, natural history and treatment of proximal femoral deficiency. In Proximal Femoral Focal Deficiency: A Congenital Anomaly, G. T. Aitken, Ed., p. 50, National Academy of Sciences,Washington, DC, USA, 1969.
6. Maldjian C, Patel TY, Klein RM, Smith RC. Efficacy of MRI in classifying proximal focal femoral deficiency. Skeletal Radiol 2007; 36(3):215–20.
7. Kayser R, Mahlfeld K, Grasshoff H, Merk HR. Proximal focal femoral deficiency-a rare entity in the sonographic differential diagnosis of developmental dysplasia of the hip. Ultraschall Med 2005; 26(5):379–84.
8. Biko DM, Davidson R, Pena A, Jaramillo D. Proximal focal femoral deficiency: evaluation by MR imaging. Pediatr Radiol 2012;42(1):50–6.

How to cite this article:
Ayaz ÜY, Ayaz S, Döğen ME, Hekimoglu B. Hip Ultrasonography in Classification of Proximal Focal Femoral Deficiency: Two Case Reports. J Clin Anal Med 2017;8(suppl 3): 187-91.