# Leriche Syndrome in the Emergency Department: Two Case Reports

# Acil Serviste Leriche Sendromu: İki Olgu Raporu

Leriche Syndrome

Mustafa Yilmaz[1], Mehtap Gurger[1], Metin Atescelik[1], Mehmet Cagri Goktekın[1], Ihsan Yigit[2]
[1]Department of Emergency Medicine, Firat University School of Medicine, Elazig,
[2]Department of Emergency Medicine, Basaksehir State Hospital, Istanbul, Turkey

*This manuscript was presented at the 2nd Intercontinental Emergency Medicine Congress, 16-19 April 2015, Antalya, Turkey.*

**Özet**

Aortik bifürkasyonun oklüzyonu sonucu meydana gelen Leriche sendromu, cerrahi olarak tedavi edilen, ciddi morbidite ve mortaliteye neden olan nadir görülen periferik vasküler hastalıklardandır. Tek yada iki taraflı alt ekstremitede kladicasyo, femoral nabızların azalması yâda yokluğu ile karakterizedir. Alt ekstremitelerde ağrı ya da güçsüzlük şikâyeti olan hastalarda ayırıcı tanıda düşülmelidir.

**Anahtar Kelimeler**

Acil Servis; Leriche Sendromu; Trombozis

**Abstract**

Leriche syndrome, resulting in occlusion of the aortic bifurcation, is a rarely seen peripheral vascular disease that is treated surgically and causes severe morbidity and mortality. It is characterized by claudication in one or both lower extremities and by absent or decreased femoral pulses. It should be considered in the differential diagnosis in patients with complaints of pain or weakness in the lower extremities.

**Keywords**

Emergency Service; Leriche Syndrome; Thrombosis

DOI: 10.4328/JCAM.5010 Received: 05.04.2017 Accepted: 20.05.2017 Printed: 01.06.2017 J Clin Anal Med 2017;8(suppl 3): 202-5
Corresponding Author: Mustafa Yilmaz, Department of Emergency Medicine, Firat University Faculty of Medicine, 23200, Elazig, Turkey.
T.: +90 4242370000/1443 GSM: +905057700734 E-Mail: drmylmz@hotmail.com

## Introduction

Leriche syndrome (LS), first described in 1923, is a clinical condition with a high mortality, which usually occurs due to thrombosis at the infrarenal aorta or bilateral iliac artery bifurcations on an atherosclerotic basis [1].The thrombus is usually at the level of the aortic bifurcation and can reach the level of the renal arteries over time. The mortality and morbidity rates of LS have been reported to be between 4.5-5.0% and 18-20%, respectively [2-6]. Two forms have been described, namely acute and chronic [7]. In the acute form, ischemic symptoms as a result of acute occlusion of peripheral arteries include leg pain, pulselessness, paresthesia, decreased temperature, pallor, and paralysis due to thrombosis in the aorta and iliac arteries. Symptoms and signs of intestinal ischemia or renal failure due to impaired blood flow in intestinal and renal arteries may develop. Leriche syndrome often occurs in males over 50 years of age, and it characteristically causes claudication in one or both lower extremities, absent or decreased femoral pulses, and erectile dysfunction in males [1,2]. In the literature, atypical findings such as paraplegia, urinary incontinence, flank pain, and shortness of breath have been reported according to the occluded level of the abdominal aorta [8-10]. The main treatment is surgery in LS, but angioplasty and endovascular stenting are the other treatment options in cases of focal involvement [11]. Abdominal aortic dissection, vertebral degenerative diseases, mechanical pain due to disc herniation, neuropathy, and Guillain-Barre syndrome should be considered in the differential diagnosis.

In this article, we aimed to present two LS cases that presented with symptoms of paresis, pain, and bruising in both legs.

## Case Report 1

A 77-year-old female patient was admitted to the emergency room with complaints of bruising and pain in the foot. Her medical history included hypertension, type 2 diabetes mellitus, and an ischemic stroke 15 days before., It was learned that she was taking her low molecular weight heparin, antihypertensive, and oral antidiabetic drugs regularly. The patient had pain, bruising, and coldness in both legs that had started approximately 10 hours before and that had increased progressively. Her vital signs were as follows: blood pressure=150/100 mmHg, pulse=88 beats/min, respiratory rate=18/min, temperature=36 °C, and oxygen saturation=97%. Physical examination revealed pulselessness in the popliteal-dorsalis pedis and posterior tibial arteries in both lower extremities, and coldness and ecchymotic areas on both lower extremities. Other systemic examinations were normal except for the sequel flat left nasolabial fold from a previous ischemic stroke. Laboratory tests were as follows: WBC=10.4x103/mm3, Hg=17.1 g/dL, Hct=55.3%, APTT=15.7 sec, INR=1.003, Troponin=0.48 ng/mL, creatinine=1.50 mg/dL, CK=233 U/L, and CKMB=105.8 U/L. Both lower extremity arterial color Doppler examinations showed no blood flow to the main femoral arteries or distally. The occlusion was found to extend to the upper parts of the main femoral artery. Abdominal CT angiography revealed that there was no contrast filling from the proximal part of the right main internal iliac artery and that there was blood flow in the left main internal iliac artery, but there was no contrast filling after the external iliac artery due to thrombosis (Figure 1, 2). The patient was diagnosed as having LS, and underwent emergent embolectomy by the Cardiovascular Surgery Clinic and was discharged one week later.



Figure 1. The appearance of total occlusion of main iliac arteries (Case 1)

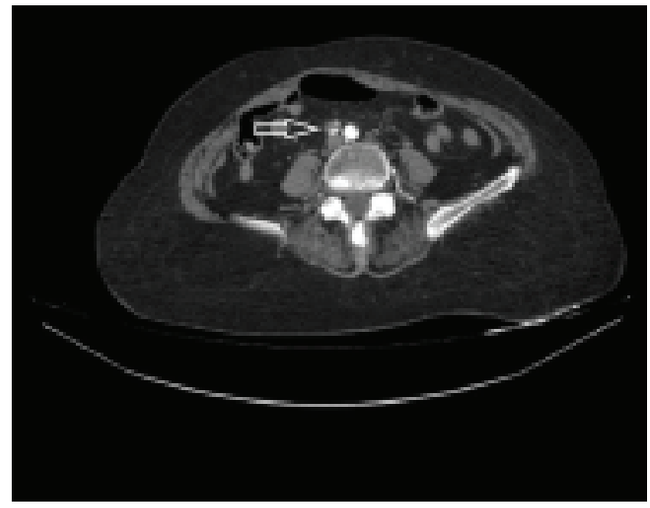

Figure 2. The appearance of total occlusion of the right main iliac artery (Case 1)

## Case Report 2

A 72-year-old male patient was admitted to the emergency department with a complaint of weakness in both lower extremities. His medical history included lumbar disc herniation, as well as a surgery due to bladder tumor. He had mild difficulty in walking and leg pain during the previous two days, but was admitted to the emergency department due to acute plegia and anesthesia in both legs for the previous 1-hour. His vital signs were as follows: blood pressure=140/90 mmHg, pulse=104 beats/min, respiratory rate=22/min, temperature=36 °C, and oxygen saturation=96%. On physical examination, bilateral lower extremity was paraplegic and deep tendon reflexes were negative. Although the pulses were weak in the femoral, popliteal-dorsalis pedis, and posterior tibial arteries, the lower extremities were cold and pale. Laboratory tests were as follows: WBC=11.3x103/mm3, Hg=13.6 g/dL, Hct=40.8%,

Troponin=<0.01 ng/mL, creatinine=0.88 mg/dL, CK=35 U/L, and CKMB=<2.0 U/L. An abdominal CT angiography revealed a thrombus that led to occlusion in the arterial lumen extending from the infrarenal part of the abdominal aorta to the bilateral main femoral arteries (Figure 3 and 4). The patient was diagnosed as having LS, and underwent emergent surgery. The patient died one day after the operation.



Figure 3. The appearance of total occlusion of the abdominal aorta at the infrarenal level (Case 2)



Figure 4. The appearance of total occlusion of the abdominal aorta at the infrarenal level (Case 2)

## Discussion

Leriche syndrome is an acute or chronic urgent condition with an atherosclerosis background that frequently requires cardiovascular surgery [7]. Symptoms of acute total occlusion are sudden and severe. The higher mortality in acute occlusions suggests that this disease should be diagnosed early and that treatment should be initiated without delay. Findings related to acute occlusion of peripheral arteries such as pain, pulselessness, paresthesia, coldness, pallor, and paralysis are observed in the limbs due to thrombosis in the aorta and iliac arteries. Depending on the level of occlusion, symptoms such as abdominal pain and renal failure may also develop due to impaired blood flow in intestinal and renal arteries. Flask paraplegia as a result of anterior spinal cord ischemia in the early period of acute aortic thrombosis will rarely be the first finding. It may cause the patients to not recognize the pain, one of the classical symptoms of arterial occlusion in patients, thus causing a delay in treatment [12]. Findings related to the dysfunction of affected organs can occur in chronic occlusion. Bayır et al. [11] reported chronic renal failure in a 50-year-old female patient with loss of strength and pain in both legs, as well as abdominal pain. While there was pain, paleness, and coldness that suggested acute obstruction, as in our first case, her presentation to the emergency department was delayed because the numbness in her legs increased gradually over a period of days and because it was thought that the complaints were caused by previously existing lumbar disc herniation.

Initiation of surgical and medical treatment in the early period after diagnosis of Leriche syndrome in the emergency department will prevent deterioration of the quality of life of the patients by avoiding mortality and prevention of organ loss or loss of extremity. However, diagnosis in the emergency department is often delayed because findings suggest other illnesses or the symptoms are perceived as motor deficits. Late admission in our second case due to the presence of numbness rather than pain in the legs supports findings in the literature that the disease is more mortal in cases of late admission.

### *Conclusion*

Leriche syndrome should be considered in the differential diagnosis of each patient who complains of leg pain or numbness in the emergency department. For this reason, the presence/absence of peripheral arterial blood flow should be evaluated, and patients with suspected pulse filling should be confirmed with color Doppler ultrasonography. Advanced imaging techniques should be used when necessary.

### *Acknowledgments*

Oral consent was obtained from the patients. The authors declare that they have no competing interests.

### *Competing interests*

The authors declare that they have no competing interests.

**References**

1. Leriche R, Morel A. The syndrome of thrombotic obliteration of the aortic bifurcation. Annals of surgery 1948;127(2):193.
2. Ligush J, Criado E, Burnham SJ, Johnson G, Keagy BA. Management and outcome of chronic atherosclerotic infrarenal aortic occlusion. Journal of vascular surgery 1996;24(3):394-405.
3. Nevelsteen A, Wouters L, Suy R. Long-term patency of the aortofemoral Dacron graft. A graft limb related study over a 25-years period. The Journal of cardiovascular surgery 1990;32(2):174-80.
4. Szilagyi DE, Elliott JP, Smith RF, Reddy DJ, McPharlin M. A thirty-year survey of the reconstructive surgical treatment of aortoiliac occlusive disease. Journal of vascular surgery 1986;3(3):421-36.
5. Sugimoto T, Ogawa K, Asada T, Mukohara N, Higami T, Obo H et al. Leriche syndrome: surgical procedures and early and late results. Angiology 1997;48(7):637-42.
6. Mavioglu I, Dogan OV, Ozeren M, Dolgun A, Yucel E. Surgical management of

chronic total occlusion of abdominal aorta. Journal of Cardiovascular Surgery 2003;44(1):87.
7. Zankl AR, Blessing E, Volz H, Krumsdorf U, Katus H, Andrassy M. Neurological symptoms in acute Leriche's syndrome. Clinical research in cardiology 2010;99(7):459-62.
8. Mitchell ML, Yucebey E, Weaver MR, Jaehne AK, Rivers EP. "I Can't Walk!" Acute Thrombosis of Descending Aorta Causing Paraplegia. Western Journal of Emergency Medicine 2013;14(5):424.
9. Xiang L, Zhou H, Jiang Z, Pan J, Yang M. Abdominal aortic thrombosis associated with nephrotic syndrome. The American journal of the medical sciences 2014;347(1):91-2.
10. Güllüpınar B. Doc! Where are My Legs? Leriche Syndrome Case Report. J Clin Anal Med 2013;4(suppl 2): 202-4
11. Bayır A, Arzıman I, Kaldırım U, et al. Acute Abdominal Pain and Paraplegia in a Patient with Chronic Renal Disease: Leriche's Syndrome. JEMCR 2013; 4: 154-157. DOI: 10.5505/jaemcr.2013.53215
12. Triantafyllopoulos GK, Athanassacopoulos M, Maltezos C, Pneumaticos SG. Acute infrarenal aortic thrombosis presenting with flaccid paraplegia. Spine 2011;36(15):E1042-E5.

*How to cite this article:*
Yilmaz M, Gurger M, Atescelik M, Goktekın MC, Yigit I. Leriche Syndrome in the Emergency Department: Two Case Reports. J Clin Anal Med 2017;8(suppl 3): 202-5.