Case Report
JCAM

Prenatal Diagnosis of Congenital Cystic Adenomatoid Malformation of the Lung

Prenatal Tanılı Konjenital Kistik Adenomatoid Malformasyonu

Congenital Hyperechogenic Lung Diseases

Ersen Ertekin[1], Özüm Tunçyürek[1], Figen Tunalı Türkdoğan[1], Mustafa Gök[1], Canten Tataroğlu[2]
[1]Radyoloji AD, [2]Adnan Menderes Üniversitesi, Tıp Fakültesi, Patoloji AD, Aydın, Türkiye

Öz

Konjenital Kistik Adenomatoid Malformasyon, terminal solunum yolu bronşiollerinin hamartomatöz proliferasyonudur ve konjenital akciğer hastalıklarının dörtte birini temsil eder. Prenatal ultrasonografide uniform hiperekoik kitle, değişken ekojenik kistler veya ekojenik stroma ile çevrili multikistik kitle şeklinde görülebilir. 20. hafta ikiz gebeliği olan 30 yaşındaki bayan olgumuzun ultrason incelemesinde, fetal sol hemitoraksı tamamen dolduran ve orta şiddette mediastinal kaymaya neden olan hiperekoik kitle lezyonu gözlendi. Sağ akciğer normal sonografik yapıda idi. Plevral efüzyon veya ek patoloji saptanmadı. Bu olgu sunumu, Konjenital Kistik Adenomatoid Malformasyonun prenatal ultrason bulguları eşliğinde hiperekojen akciğer hastalıkları nedenlerini gözden geçirmiştir.

Anahtar Kelimeler

Konjenital Kistik Adenomatoid Malformasyon, Prenatal Tanı, Hiperekojen Akciğer Hastalıkları

Abstract

Congenital cystic adenomatoid malformation (CCAM) is the hamartomatous proliferation of terminal respiratory bronchioles and represents a quarter of congenital lung diseases. On prenatal ultrasonography, uniform hyperechoic mass, variable echogenic cysts, or multicystic mass surrounded by echogenic stroma may be observed. This case report illustrates prenatal diagnosis of a microcystic-type CCAM in a 30-year-old female patient, pregnant with twins (week 20), and confirmed by the microscopic examination of autopsy. The US scan showed a hyperechoic mass filling the left hemithorax completely and causing a moderate mediastinal shift. The right lung was of a normal sonographic structure, and there was no pleural effusion or additional pathology detected. This report has reviewed the causes of hyperechogenic lung diseases of neonatals with a presentation of the prenatal US findings of a case of CCAM.

Keywords

Congenital Cystic Adenomatoid Malformation, Prenatal Diagnosis, Hyperechoic Lung Diseases

DOI: 10.4328/JCAM.5034 Received: 17.04.2017 Accepted: 16.06.2017 Printed: 01.06.2017 J Clin Anal Med 2017;8(suppl 3): 216-8
Corresponding Author: Ersen Ertekin, Radyoloji AD. Adnan Menderes Üniversitesi, Tıp Fakültesi, 09010 Aydın, Türkiye.
GSM: +905332124478 E-Mail: drersen@hotmail.com

Introduction

Congenital cystic adenomatoid malformation (CCAM) is the hamartomatous proliferation of terminal respiratory bronchioles and represents a quarter of congenital lung diseases. Almost 95% of the CCAMs are unilateral. Usually, it is associated with the tracheobronchial tree. As a result of the prevention of alveolar development, cysts occur in the lungs. Cysts are covered by respiratory epithelium [1,2]. Many patients present as respiratory distress in the newborn period. Around 10% of the CCAMs cause recurrent pneumonia with age, while some cases may remain asymptomatic. Many patients present as respiratory distress in the newborn period. Around 10% of the CCAMs cause recurrent pneumonia with age, while some cases may remain asymptomatic. There are three types of CCAMs, which are indicated by the size of the cysts, named macrocystic, microcystic, and mixed-type CCAM [3,4]. On prenatal ultrasonography, uniform hyperechoic mass (microcystic type), variable echogenic cysts (macrocystic type), or multicystic mass surrounded by echogenic stroma (mixed type) may be observed. Cystic masses, especially the microcystic type, can cause mediastinal shift. In this case report, we review prenatal findings of congenital cystic adenomatoid malformation (CCAM) of the lung and hyperechoic lung diseases for which different diagnoses should be considered.

Case Report

A 30-year-old female patient, pregnant with twins (week 20), was admitted to our ultrasound (US) unit for a congenital anomaly scan. The US scan showed a hyperechoic mass filling the left hemithorax completely and causing a moderate mediastinal shift [Figure 1]. The vascularization of the lesion was through the right pulmonary artery. The left lung was of a normal sonographic structure, and there was no pleural effusion or additional pathology detected. According to these findings, we considered a diagnosis of microcystic-type CCAM. Because hydrops and polyhydroamnios were not observed, we recommended close monitoring.

It is not possible to comment on the course of the disease prenatally, as the patient did not come to follow-up examinations. The mother gave birth with caesarian section (C/S) in the 25th gestational week. The male infant with advanced growth retardation was intubated due to cyanosis, and dead on the second day of the follow-up, due to the development of hyaline membrane disease.

In the microscopic examination of autopsy, widely hemorrhagic areas and eosinophilic hyaline membrane formations in the alveoli were observed in both lungs [Figure 2a]. In addition, dilated cystic structures covered by respiratory epithelium similar to bronchus were observed in the lower lung lobe of the left lung [Figures 2b, c, d]

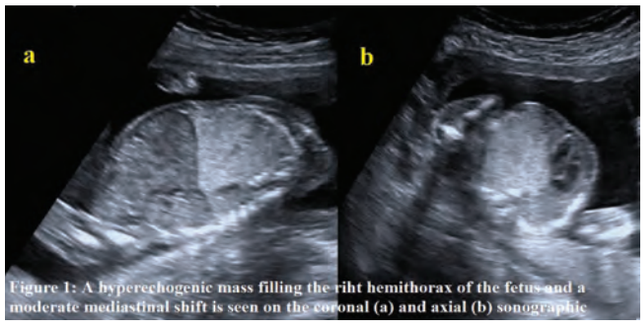

Figure 1. A hyperechogenic mass filling the left hemithorax of the fetus and a moderate mediastinal shift is seen in the coronal (a) and axial (b) sonographic images

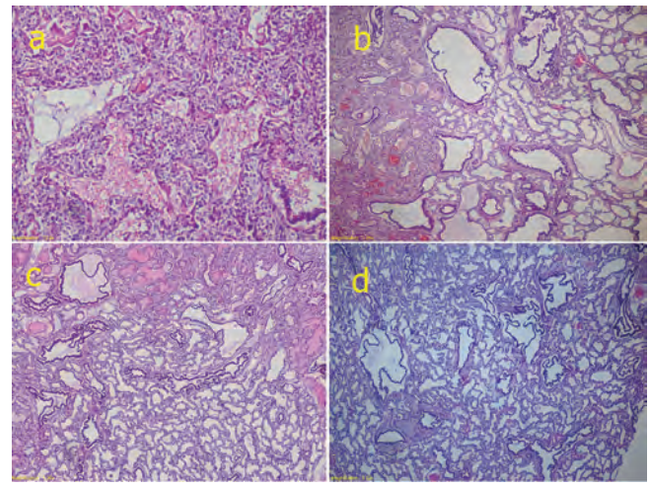

Figure 2. Eosinophilic hyaline membranes in the alveoli (a) and dilated cystic structures covered by respiratory epithelium (b, c, d) are seen in pathological specimens

Discussion

CCAM is the hamartomatous proliferation of terminal respiratory bronchioles and represents a quarter of congenital lung diseases. Almost 95% of the CCAMs are unilateral. Usually, it is associated with the tracheobronchial tree, but vasculatory structures are normal. As a result of the prevention of alveolar development, cysts occur in the lungs. Cysts are covered by respiratory epithelium [1,2]. As in our case, many patients present as respiratory distress in the newborn period. Around 10% of the CCAMs cause recurrent pneumonia with age, while some cases may remain asymptomatic.

There are three types of CCAMs, which are indicated by the size of the cysts, named macrocystic, microcystic, and mixed-type CCAM [3,4]. The best prognosis is where one or more cysts larger than 1 cm are observed (macrocystic CCAM), while solid-looking microcysts indicate the worst prognosis type (microcystic CCAM). On prenatal ultrasonography, uniform hyperechoic mass (microcystic type), variable echogenic cysts (macrocystic type), or multicystic mass surrounded by echogenic stroma (mixed type) may be observed. Cystic masses, especially the microcystic type, can cause mediastinal shift. While macrocystic and mixed types of CCAM may persist during pregnancy, regression is observed in the majority of microcystic CCAM cases [3,5].

Hydrops and polyhydroamnios are common phenomena in microcystic CCAM, as compared to the other types of CCAM. In-utero or postpartum exitus is observed in the vast majority of hydrops cases [6].

For differential diagnosis, the other reasons for hyperechogenic lung (congenital high airway obstruction syndrome [CHAOS] and pulmonary sequestration [PS]) should be kept in mind [1,3]. Display of the feeding arteries from the aorta is diagnostic for PS, although PS cannot be excluded just because it is not shown [2]. In CHAOS, hyperechogenic masses are seen in the bilateral hemithorax, while the mediastinum and hearth are compressed due to the massive enlargement of the lungs [7].

The treatment for microcystic CCAM is open lobectomy, although US guided laser ablation of the feeding arteries can be applied. In macrocystic and mixed-type CCAMs, a thoracoamniotic shunt may be performed, which has a success rate of 2/3 [4,8].

In our case, in accordance with the literature, a uniform hyperechogenic mass filling the left hemithorax and displacing the mediastinum to the right was observed on US examination, and respiratory distress appeared after the birth. The premature birth and low birth weight of the infant led to the development of hyaline membrane disease and, as a consequence of that, the clinical condition declined further.

This report has reviewed the causes of hyperechogenic lung diseases of neonatals with a presentation of the prenatal US findings of a case of CCAM.

Competing interests

The authors declare that they have no competing interests.

References

1. Gajewska-Knapik K, Impey L. Congenital lung lesions: Prenatal diagnosis and intervention. Semin Pediatr Surg. 2015;24(4):156-9. doi:10.1053/j.sempedsurg.2015.01.012.
2. Mendeloff EN. Sequestrations, congenital cystic adenomatoid malformations, and congenital lobar emphysema. Semin Thorac Cardiovasc Surg 2004;16(3):209-14.
3. Adzick NS, Harrison MR, Crombleholme TM, Flake AW, Howell LJ. Fetal lung lesions: management and outcome. Am J Obstet Gynecol 1998;179(4):884-9.
4. Mann S, Wilson RD, Bebbington MW, Adzick NS, Johnson MP. Antenatal diagnosis and management of congenital cystic adenomatoid malformation. Semin Fetal Neonatal Med. 2007;12(6):477-81.
5. Cavoretto P, Molina F, Poggi S, Davenport M, Nicolaides KH. Prenatal diagnosis and outcome of echogenic fetal lung lesions. Ultrasound Obstet Gynecol 2008;32(6):769-83. doi: 10.1002/uog.6218.
6. Vu L, Tsao K, Lee H, Nobuhara K, Farmer D, Harrison M, Goldstein RB. Characteristics of congenital cystic adenomatoid malformations associated with nonimmune hydrops and outcome. J Pediatr Surg 2007;42(8):1351-6.
7. Biyyam DR, Chapman T, Ferguson MR, Deutsch G, Dighe MK. Congenital lung abnormalities: embryologic features, prenatal diagnosis, and postnatal radiologic-pathologic correlation. Radiographics 2010; 30(6): 1721-38. doi: 10.1148/rg.306105508.
8. Min JY, Won HS, Lee MY, Suk HJ, Shim JY, Lee PR, Kim A. Intrauterine therapy for macrocystic congenital cystic adenomatoid malformation of the lung. Obstet Gynecol Sci 2014; 57(2): 102-8. doi: 10.5468/ogs.2014.57.2.102.

How to cite this article:

Ertekin E, Tunçyürek Ö, Türkdoğan FT, Gök M, Tataroğlu C. Prenatal Diagnosis of Congenital Cystic Adenomatoid Malformation of the Lung. J Clin Anal Med 2017;8(suppl 3): 216-8.