

Endometrial Osseous Metaplasia And Infertility: Case Report

Endometriyal Osseöz Metaplazi ve İnfertilite: Olgu Sunumu

Endometrial Osseous Metaplasia

Muzeyyen Uyanık[1], Murat Erdemır[2], Ergun Uyanık[3], Safak Atahan[4]
[1]Department of Obs&Gyn, VM Medical Park Hospital Bahçeşehir University, İstanbul [2]Department of Obs&Gyn, Jinemed IVF Center, Bursa, [3]Department of Obs&Gyn, Yuksek Ihtisas Training and Research Hospital, Bursa, [4]Department of Pathology, Biruni University School of Medicine, Istanbul, Turkey

Özet

Endometriyal osseöz metaplazi infertiliteye sebep olabilen nadir bir durumdur. Sıklıkla geç abortuslardan sonra görülebilmektedir. Etyolojisi net olarak bilinmemekle birlikte teorilerle açıklanmaktadır. Bu olguda; 36 yaşında , nullipar hasta polikliğimize çocuk istemi ile başvurdu. Transvajinal ultrasonografi ile değerlendirmede endometrial alanda rahim içi araç (IUD) benzeri ekojen görünüm saptanması üzerine histeroskopi ile tanı ve tedavisi sağlanmış ,spontan olarak gebe kalmış bir hastayı sunmayı amaçladık. Histeroskopik inceleme ile nadir bir infertilite sebebi olan osseöz metaplazi tanısı konulabilmekte ve histeroskopik yöntem ile kemik parçalarının uzaklaştırılması sonucu fertilite geri dönebilmektedir.

Anahtar Kelimeler

Endometriyal Osseöz Metaplazi; İnfertilite; Histeroskopi

Abstract

Endometrial osseous metaplasia is a rare condition which may cause infertility, and can be seen by following late abortions. Its etiology has not been clearly established, although there are several theories. Herein, we report a 36-year old nullipara patient who was admitted to our clinic with the desire to have a child. She was treated with hysteroscopy based on the presence of an echogenic appearance similar to an intrauterine device (IUD) on the endometrial area as assessed through transvaginal ultrasonography and she subsequently had a spontaneous pregnancy. Osseous metaplasia, which is a rare cause of infertility, can be diagnosed through hysteroscopic examination, and fertility can be restored by removing the bone fragments through hysteroscopy.

Keywords

Endometrial Osseous Metaplasia; Infertility; Hysteroscopy

DOI: 10.4328/JCAM.5048 Received: 25.04.2017 Accepted: 08.06.2017 Printed: 01.06.2017 J Clin Anal Med 2017;8(suppl 3): 213-5
Corresponding Author: Muzeyyen Uyanık, Department of Obs&Gyn. VM Medical Park Hospital, Osmangazi, Bursa, Turkey.
GSM: +905438090882 E-Mail: drmuzeyyenuyanik@gmail.com

Introduction

Endometrial osseous metaplasia is a rare condition which may cause infertility. It may present with pelvic pain, dyspareunia, and menstrual irregularities. It may be seen following late abortions. Its etiology is not clearly known; however, endometrial tissue osseous metaplasia or fetal bone retention are considered as the possible causes [1,2]. Herein, we report a case who was admitted to our clinic due to infertility and diagnosed and treated through hysteroscopy.

Case Report

A 36-year old nullipara patient was admitted to our clinic with the desire to have a child. In the third day of menstruation of the patient, transvaginal ultrasonography (TVUSG) revealed normal findings on the endometrial area, except for an echogenic appearance similar to an intrauterine device (IUD) (FSH: 7.2mIU/mL LH: 4.3mIU/mL E2: 58pg/mL spermiogram: normospermia). In the hysteroscopy, excision was performed by following the presence of fine, calcified, and white bone plaques in the endometrial cavity (Picture 1). The entire cavity was, then curetted with a sharp curette. In the histological evaluation, bone trabeculae with a metaplastic mature appearance within the pseudostratified columnar epithelium laid endometrial gland structures was observed, and pathological result was reported as endometrial osseous metaplasia (Picture 2). The patient had a spontaneous pregnancy following hysteroscopic diagnosis and treatment.

Discussion

Endometrial osseous metaplasia is a rare condition characterized by abnormal bone formation in the endometrial cavity [1]. Although its etiology still remains unclear, there are two theories regarding the pathophysiology of the disease including: fetal bone retention following an abortion later than three -month gestational weeks, and osseous metaplasia of endometrial stroma [1,2]. Inconsistent with the reported cases in the literature, our case had no abortus history. Possible mechanisms of metaplasia can be defined as the conversion of chronic inflammatory dystrophic calcification to bone formation or myeloid metaplasia, which can be observed in the myometrial transitional zone. Bone fragments in the endometrial cavity are also believed to prevent blastocyst implantation, inducing reactive endometritis as an IUD and leading to infertility [3].

In addition to infertility, endometrial osseous metaplasia may present with several findings such as pelvic pain, dyspareunia and menstrual irregularities [2]. It is often suspected in infertile cases due to the presence of calcification similar to an IUD appearance during the ultrasonographic examination. The diagnosis is made based on the presence of osteoid formations in hysteroscopy and histopathological examination of the specimens; obtained, and fertility can be restored by the removal of bone fragments [4]. Furthermore, Garcia Lean et al. [5] and Rodrigues et al. [6] suggested using laparoscopy as well as hysteroscopic approach to reduce the risk of perforation and to investigate other causes of infertility.

In conclusion, endometrial evaluation in infertile patients is of utmost importance. Hysteroscopy in endometrial evaluation is one of the most useful methods used in daily clinical practice. Osseous metaplasia can be diagnosed and treated through hysteroscopic examination and excision.

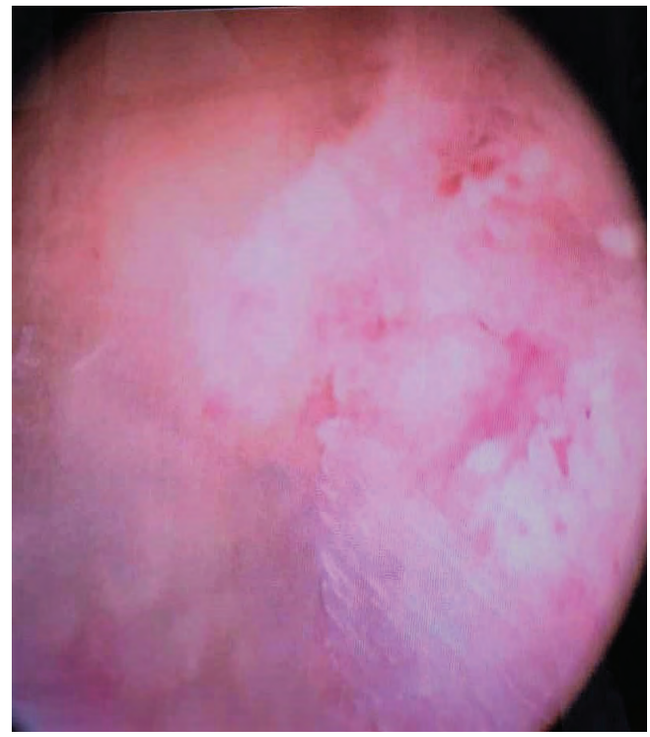

Picture 1. Bone Fragments (Hysteroscopy)

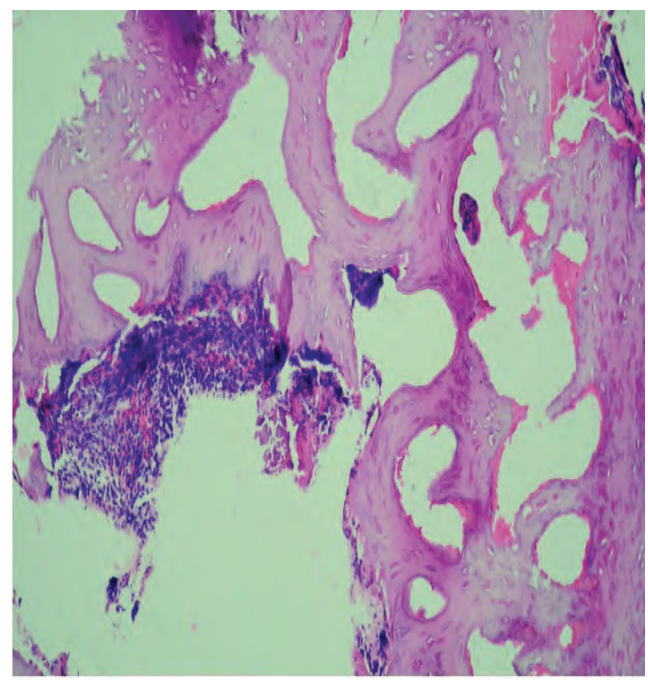

Picture 2. Bone trabeculae with a metaplastic mature appearance within the pseudostratified columnar epithelium

Competing interests

The authors declare that they have no competing interests.

References

1. Basu M, Mammen C, Owen E. Bony fragments in the uterus: an association with secondary subfertility. Ultrasound Obstet Gynecol 2003;22(4):402-6.
2. Garg D, Bekker G, Akselrod F, Narasimhulu DM. Endometrial osseous metaplasia: an unusual cause of infertility. BMJ Case Rep 2015; doi: 10.1136/bcr-2015-209523.
3. Tsai MC, Arunamata A, Tristan S, Randall HW. Endometrial osseous metaplasia mimicking retained intrauterine device: a case report. J Reprod Med

2008;53(11):877-80.
4. Coccia ME, Becattini C, Bracco GL, Scarselli G. Ultrasound-guided hysteroscopic management of endometrial osseous metaplasia. Ultrasound Obstet Gynecol 1996 ;8(2):134-6.
5. Garcia Leon F, KablyAmbe A. Osseous metaplasia of the endometrium as a cause of infertility. Hysteroscopic approach. Ginecol Obstet Mex 1999;67(1):37–41
6. Rodriguez BD, Adamson GD. Hysteroscopic treatment of ectopic intrauterine bone. A case report. J Reprod Med 1993;38(7):515–20.

How to cite this article:
Uyanık M, Erdemır M, Uyanık E, Atahan S. Endometrial Osseous Metaplasia and Infertility: Case Report. J Clin Anal Med 2017;8(suppl 3): 213-5.