Case Report
JCAM

A Leukocytoclastic Vasculitis Case Due to Tenofovir Use

Tenofovir Kullanımına Bağlı Gelişen Lökositoklastik Vaskülit Olgusu

Tenofovir Induced Leukocytoclastic Vasculitis

A Haykir Solay[1], F Civelek Eser[1], EE Tutuncu[1], B Gencler[2], E.Ozturk Onder[3]
[1]Department of Infectious Disease and Clinical Microbiology, [2]Department of Dermatology,
[3]Department of Pathology, Diskapi Yildirim Beyazit Training and Research Hospital, Ankara, Turkey

Öz

Asiklik bir nükleotid analoğu olan tenofovir disoproksil fumarat, hepatit B tedavisi için 2008 yılında onaylanan antiviral bir ilaçtır. Bilinen en sık yan etkileri; bulantı, kusma, diyare, nefrotoksisite ve hepatotoksisitedir. Fakat cilt tutulumu olan yan etkiler nadir görülür. Kutanöz lökositoklastik vaskülit ise birçok ilaca bağlı olarak görülebilmekle birlikte tenofovirin indüklediği olgu daha önce hiç bildirilmemiştir. Burada, kronik hepatit B tanısı ile başlanan tenofovir tedavisinin dördüncü haftasında kutanöz lökositoklastik vaskülit gelişen bir olgu sunulmuştur.

Anahtar Kelimeler

Tenofovir; Lökositoklastik Vaskülit; Yan Etki

Abstract

The antiviral agent tenofovir disoproxil fumarate is an acyclic nucleotide analogue, which has been approved in 2008 for the treatment of hepatitis B. The most common side effects are nausea, vomiting, diarrhea, nephrotoxicity, and hepatotoxicity. Nevertheless, side effects with dermal involvement are rare. Cutaneous leukocytoclastic vasculitis can be induced by many drugs, but the tenofovir-induced case has not been reported previously. To best of our knowledge, we present the first case of tenofovir induced cutaneous leukocytoclastic vasculitis at the 4th week of treatment of chronic hepatitis B.

Keywords

Tenofovir; Leukocytoclastic Vasculitis; Side Effect

DOI: 10.4328/JCAM.5166 Received: 24.07.2017 Accepted: 12.08.2017 Printed: 01.06.2017 J Clin Anal Med 2017;8(suppl 3): 231-3
Corresponding Author: Asli Haykir Solay, Department of Infectious Disease and Clinical Microbiology, Diskapi Yildirim Beyazit Training and Research Hospital, University of Health Sciences, Altindag, Ankara, Turkey. F.: +90 3125962793 E-Mail: aahaykir@hotmail.com

Introduction

Cutaneous leukocytoclastic vasculitis (LCV) is the inflammation of small blood vessels and may be secondary to drugs, infections, malignity, and connective tissue disorders [1].

Tenofovir is generally well tolerated. Most common side effects are related to the gastrointestinal system [2]. Nephrotoxicity and hepatotoxicity are less common. However, side effects, involving the skin, are rare [3]. In our knowledge, LCV case due to tenofovir has not been reported yet. Here, we present a case with LCV, which developed at the first month of tenofovir treatment.

Case Report

A 59 years-old male patient with chronic hepatitis B and cirrhosis admitted to our hospital with widespread itching, particularly at lower extremities. Medical history revealed that complaints of the patient started in the first month of tenofovir treatment, and no other medications were used. He had no complaint other than weakness, and itching; he had no fever, oral or genital ulcers, photosensitivity, arthralgia; and he did not take any herbal treatments. Physical examination revealed that heart beat was 82 bpm, blood pressure was 110/70 mmHg, respiratory rate was 16/min, and body temperature was 36.7 °C. There were no palpable lymph nodes. Hyperpigmented macular lesions of 0.5 cm in diameter were present in both lower extremities, particularly on anterior of tibias (Figure 1). Remaining physical examination findings were normal. Complete blood count, hepatic, renal and thyroid function tests, erythrocyte sedimentation rate and C-reactive protein were normal. Other laboratory findings are summarized in the table. Skin biopsy was performed after learning that previous antihistaminic treatment did not work, which was recommended by a dermatologist. Biopsy result was reported as mild, and partly moderate inflammatory infiltrate at perivascular localization in the subepidermal region beneath the epidermis, which included lymphocytes as well as high numbers of polymorphic nucleated leucocytes. Partial leukocytoclastic foci were observed, and capillary endothelium made explicit. Additionally, few numbers of extravasated erythrocytes were seen in the interstitium. These findings were compatible with LCV (Figure 2). Possible etiologies for LCV include infectious diseases, malignity, and collagen tissue disorders. Since he was on follow-up for chronic hepatitis B, HBV DNA was analyzed, but found negative. Other viral indicators were also negative (Table). Pathogen microorganisms were not found in stool, throat, and sputum cultures. Urine cultures were also negative. Thoraco-abdominal tomography did not reveal positive findings for infectious diseases or malignity. There were no pathological findings other than esophageal varices in upper gastrointestinal system endoscopy. Colonoscopy did not reveal findings of chronic inflammatory bowel disease or malignity. There was no finding regarding collagen tissue disorders. Serologic indicators for collagen tissue diseases and other vasculitis are presented in Table. Only cytoplasmic antinuclear antibody was found positive. The diseases that might be responsible for the etiology were all eliminated, and the only drug that patient used, tenofovir, was stopped and replaced with entecavir. Itching and cutaneous lesions regressed after two weeks of drug exchange, and no new lesions were observed.

Table. Laboratory findings, and viral and serologic markers after development of leukocytoclastic vasculitis due to tenofovir

	Value
Complete Urine Test	
Leukocyte, erythrocyte, protein	Negative
Viral Markers	
HBsAg (ELISA)	Positive
HBV DNA (PCR)	Negative
Anti-HCV (ELISA)	Negative
Anti-HIV (ELISA)	Negative
Anti-HAV IgM (ELISA)	Negative
Delta antibody (ELISA)	Negative
CMV IgM/IgG (ELISA)	Negative
Serologic Markers	
Rheumatoid factor (IU/L)	Negative
Anti-nuclear antibody	Negative
P-ANCA	Negative
C-ANCA	Positive

Discussion

Leukocytoclastic vasculitis is a small-vessel vasculitis that is characterized by neutrophilic infiltration in cutaneous superficial postcapillary venules. It may be idiopathic, and may also be related to infections, drugs, collagen tissue diseases, and malignities [1]. The case presented here had no suspected disease in the etiology.



Figure 1. Multiple palpable purpuras in both lower extremities

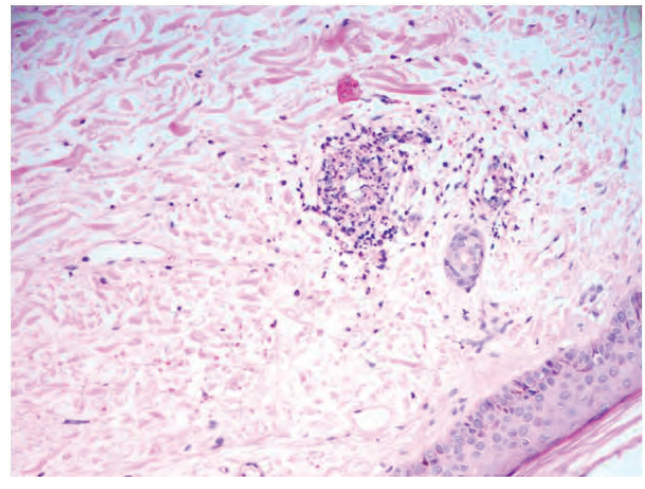

Figure 1. Lymphocytes and polymorphonuclear leukocytes in perivascular area releated to inflamation (HE X 200)

Small-vessel vasculitis are evaluated under two headings either antineutrophil cytoplasmic antibody (ANCA) positive or ANCA negative. These antibodies are autoantibodies that target lysosomal enzymes of neutrophils and grouped as c-ANCA that is against proteinase, and p-ANCA that is against myeloperoxidase [4]. ANCA positive small-vessel vasculitis are classified under four groups as microscopic polyangiitis, Wegener's granulomatosis, Churg-Strauss syndrome, and drug-induced vasculitis [5]. Drug-induced small-vessel vasculitis constitutes about 10%, and most commonly responsible drugs are penicillin, aminopenicillin, sulphonamides, allopurinol, quinolone, thiazides, hydantoin, and propylthiouracil [5]. They develop approximately after 7 to 21 days of drug initiation [6]. In our case, leukocytoclastic vasculitis has developed due to tenofovir, which has not been reported before and has developed one month after the initiation of the drug.

More commonly palpable purpura, especially in lower extremities, and less commonly urticarial, vesicular, nodular, and target-like lesions, livedoid pattern, and ulcerations are seen clinically [1]. Constitutional symptoms, arthralgia, myalgia, and other symptoms related to internal organ involvement are also seen in patients [7]. Itching is present rarely [8]. In this case, the main complaint of the patient was itching, and purpura. Tenofovir related leukocytoclastic vasculitis case has not been reported previously. Diagnose of this case was based on elimination of other causes, tenofovir being the only medication, and regression of lesions after changing this drug.

Tenofovir is a nucleotide analogue and widely used for chronic hepatitis B and antiretroviral treatment. It is a quite safe drug, but adverse events like nausea, vomiting, diarrhea, hepatotoxicity, nephrotoxicity, pancreatitis, Fanconi anemia, and diabetes insipidus were reported. Maculopapular rashes, urticarial rashes, vesiculopustular lesions, and lichenoid drug eruptions are rarely reported [3]. Also, tenofovir related itching is very rare [8]. The ideal way of treatment of cutaneous side effects related with tenofovir is not known. In a previous report of a case with skin eruptions, lesions were reported to regress ten days after the drug discontinuation [8]. In our case, no additional treatment was given, and itching complaint and lesions were resolved within two weeks after drug withdrawal. Increasing number or reports will help to constitute a common approach regarding the management of these cases.

Leukocytoclastic vasculitis is diagnosed by histopathological evaluation of the biopsy from the lesion, and additional laboratory tests should be performed for systemic involvement and its etiology.

Drugs might play a role in the etiology of LCV. Although it has not been reported before, LCV may develop on tenofovir use as can be seen in this case. One should be careful with the cutaneous lesions that develop during medication use and appropriate diagnostic methods, and the differential diagnoses should be kept in mind to manage the treatment.

Scientific Responsibility Statement

The authors declare that they are responsible for the article's scientific content including study design, data collection, analysis and interpretation, writing, some of the main line, or all of the preparation and scientific review of the contents and approval of the final version of the article.

Funding

The funders had no role in study design, data collection, and analysis, decision to publish, or preparation of the manuscript.

Competing interests

The authors declare that they have no competing interests

Ethical Responsibilities

No animal or human studies were carried out by the authors for this article.

References

1. Goeser MR, Laniosz V, Wetter DA. A practical approach to the diagnosis, evaluation, and management of cutaneous small-vessel vasculitis. Am J Clin Dermatol. 2014; 15:299-306.
2. Van Bommel F, Wunsche T, Schurmann D, Berg T. Tenofovir treatment in patients with lamivudine-resistant hepatitis B mutants strongly affects viral replication. Hepatology. 2002;36(2):507–8.
3. Gupta M, Gupta H, Gupta A. Tenofovir induced lichenoid drug eruption. Avicenna J Med. 2015;5(3):95–7.
4. Shikha D, Harris J, Resta C, Park P. Antineutrophilic Cytoplasmic Antibody Positive Vasculitis Associated with Methimazole Use. Case Rep Endocrinol. 2015;2015:530319.
5. Mansi IA, Opran A, Rosner F. ANCA-associated small-vessel vasculitis. Am Fam Physician. 2002;65(8):1615-20.
6. Jennette JC, Falk RJ. Small-vessel vasculitis. N Engl J Med 1997;337(21):1512-23.
7. Grau RG. Drug-Induced Vasculitis: New Insights and a Changing Lineup of Suspects. Curr Rheumatol Rep. 2015;17(12):71.
8. Jain P. A case of cutaneous reaction with tenofovir disoproxil fumarate. J Clin Exp Hepatol. 2013;3(3): 254-5.

How to cite this article:
Solay AH, Eser FC, Tutuncu EE, Gencler B, Onder EO. A Leukocytoclastic Vasculitis Case Due to Tenofovir Use. J Clin Anal Med 2017;8(suppl 3): 231-3.