Pseudoxanthoma Elasticum: Report of Two Cases

Psödoksantoma Elastikum: İki Olgu Sunumu

Common Eye and Skin Findings in the Pseudoxanthoma Elasticum

Suzan Demir Pektas[1], Omur Demirtas[2], Gulen Gul[3], Yelda Dere[4], Suphi Bulent Sarı[5], Gursoy Dogan[1], Aylin Karalezli[5]
[1]Department of Dermatology, Muğla Sıtkı Kocman University Faculty of Medicine, Mugla,
[2]Department of Ophthalmology, Aydin State Hospital, Aydın, [3]Department of Pathology, Tepecik Training and Researh Hospital, İzmir,
[4]Department of Pathology, Muğla Sıtkı Kocman University Faculty of Medicine, Mugla,
[5]Department of Ophthalmology, Muğla Sıtkı Kocman University Faculty of Medicine, Mugla, Turkey

This article accepted to 2017 EADV congress as e-poster.

Öz

Psödoksantoma elastikum (PKE), elastik bağ dokusunun patolojik kalsifikasyonu ile karakterize genetik geçişli, multisistemik bir hastalıktır. PXE, olguların %90'ında otozomal dominant kalıtım paternine sahip nadir görülen bir hastalıktır. Erkeklere göre kadınlarda daha sık görülür. PKE gelişiminde transmembran transporter proteinini kodlayan ABCC6 (ATP bağlayıcı kaset alt ailesi C elemanı 6) genindeki mutasyonun rol oynadığı gösterilmiştir. Klinik bulgular; genellikle deri, göz, mukoza, gastrointestinal sistem ve arterlerde ortaya çıkar. PXE'de asemptomatik cilt lezyonları, genellikle ilk klinik bulgudur. PXE'de peau d'orange, kuyruklu yıldız lezyonları, anjioid çizgileri, koroid neovaskülarizasyonu (KNV), kanamalar oftalmolojik tutulumla ilişkili başlıca bulgulardır. PXE'li hastalarda nadiren erken erken ateroskleroz, akut miyokard infarktüsü ve serebrovasküler olaylar gelişebilir. Bu makalede, PKE tanılı iki kadın olguyu sunarak hastalığın klinik özelliklerini, hastalıkla ilişkili komplikasyonları ve hastalığın etkin tedavisi için erken teşhisin önemini vurgulamayı amaçladık.

Anahtar Kelimeler

Deri; Göz; Psödoksantoma Elastikum

Abstract

Pseudoxanthoma elasticum (PXE) is an inherited multisystem disorder characterized by pathological calcification of the elastic connective tissue. PXE is a rare disease with an autosomal dominant inheritance pattern in 90% of the cases. Females are more commonly affected than males [2]. PXE is caused by mutations in the ABCC6 (ATP-binding cassette sub-family C member 6) gene that encodes a transmembrane ATP binding efflux transporter. Clinical manifestation occurs in skin, eyes, mucosa, gastrointestinal tract and the arteries. Asymptomatic skin manifestations, which are often the first clinical signs of PXE. Ophthalmological features of PXE include primarily peau d'orange, comet lesions, angioid streaks, choroidal neovascularization (CNV), hemorrhages. The patients of PXE can also develop premature atherosclerosis with early acute myocardial infarcts and cerebrovascular accidents. We reported two female cases of PXE, emphasizing its main clinical aspects and highlighting the importance of early diagnosis of the disease for an adequate therapeutical management of associated complications.

Keywords

Eyes; Pseudoxanthoma Elasticum; Skin

DOI: 10.4328/JCAM.5173 Received: 23.06.2017 Accepted: 09.08.2017 Printed: 01.06.2017 J Clin Anal Med 2017;8(suppl 3): 228-30
Corresponding Author: Suzan Demir Pektas, Department of Dermatology, Muğla Sıtkı Kocman University Faculty of Medicine, 48000, Mugla, Turkey.
T.: +90 2522115219 F.: +90 3123116768 E-Mail: suzandpektas@gmail.com

Background

PXE is a multisystem disease with an autosomal dominant inheritance pattern in 90% of the cases, or autosomal recessive [1]. Females are more commonly affected than males [2]. PXE is caused by mutations in the ABCC6 (ATP-binding cassette subfamily C member 6) gene [2]. Clinical manifestation occurs in skin, eyes, oral mucosa, gastrointestinal tract and the arteries [1]. We report two cases of PXE, emphasizing its main clinical aspects.

Case Report 1

Female patient, 48 years old reported the onset of asymptomatic yellowish-colored cobblestone-like papules and plaques in the cervical and axilla region. She had three intravitreal injections for treatment of choroidal neovascular membrane in ten years. She had a history of vision blurring. The patient did not have underlying diseases and denied familial cases of the same malady. At the dermatological examination, coalescent yellowish papules forming plaques distributed symmetrically in the cervical region and axilla were observed (Figure1A). The histopathological examination made evident calcified, distorted, and fragmented elastic fibers in the dermis with Verhoeff–van Gieson stain, compatible with the diagnosis of PXE (Figure 1 C, D). Fundus fluorescein angiography couldn't be performed due to patient's fluorescein allergy. BCVA was 0.2 (Snellen) in the right eye and counting fingers in the left eye. Slit-lamp examination of the anterior segment and intraocular pressures were within normal limits. Fundoscopic examination and optical coherence tomography examination revealed angioid streaks around the optic discs in both eyes and chorioretinal scar due to the choroid neovascularization in the left eye (Figure 2A, B). On other laboratory and cardiologic examination, were unremarkable. She has been made Dermatologic and Ophthalmologic monitoring.

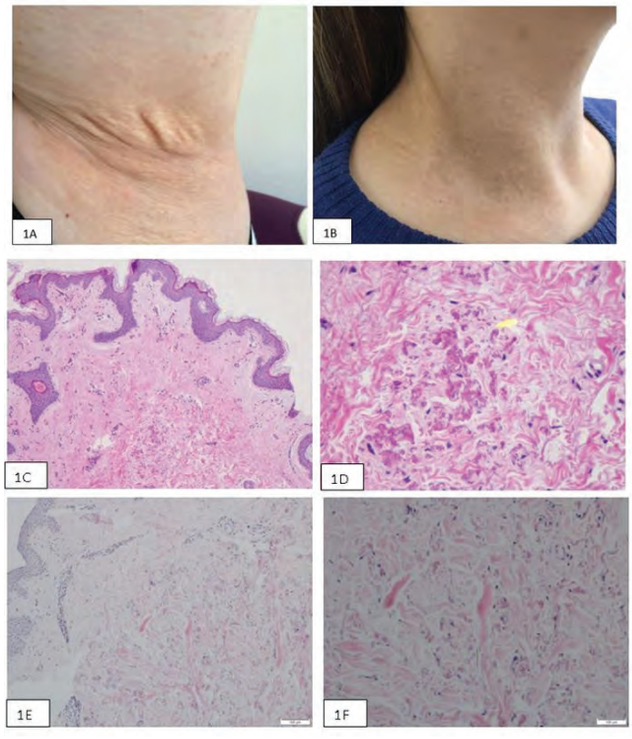

Figure 1. Coalescent yellowish papules forming plaques distributed symmetrically in the axilla of the first case (A); Coalescent yellowish papules forming plaques distributed symmetrically in the cervical region of the second case (B); At histological examination of the first case: Fragmented elastic fibers in the reticular dermis (x100) (C); Short, distorted basophilic elastic fibers (x400) (D); At histological examination of the second case: degenerative elastic fibers in subcutaneous tissue (X10) (E); Degenerative elastic fibers with elastic van Gieson stain (X200) (F).

Case Report 2

26 years old female patient presented to our clinic with asymptomatic yellowish-colored papules in her cervical region. At the dermatological examination, several brown colored macules and erythematous papules and coalescent yellowish papules in the cervical region were observed (Figure 1B). The patient did not have underlying diseases and denied familial cases of the same malady. The histological examination of papules revealed calcification and fragmentation of elastic fibers in the middle and deep dermal layers, confirming the diagnosis of PXE (Figure 1E, F).

BCVA was 1.0 in both eyes (Snellen). Slit-lamp examination of the anterior segment and intraocular pressures were within normal limits. Fundoscopic examination revealed AS around the optic discs and peau d'orange appearance in the temporal macula of both eyes (Figure 2C). Fluorescein angiography showed variable staining of the AS without leakage in any phase (window defect) and Comet signs in the mid-periphery of the retina (Figure 2D). Fundus autofluorescence showed distinct areas of hypo-autofluorescence corresponding to the AS with focal spots of increased autofluorescence alongside the AS (Figure 2E). SD-OCT showed breaks in Bruch's membrane with preservation of the overlying retina pigment epithelium (Figure 2F). Laboratory and cardiologic examination were unremarkable. Dermatologic and Ophthalmologic monitoring has been made.

Discussion

PXE is a genetic disorder of the connective tissue characterized by skin, ocular and vascular lesions [1, 2]. Asymptomatic skin manifestations, which are often the first clinical signs of PXE,

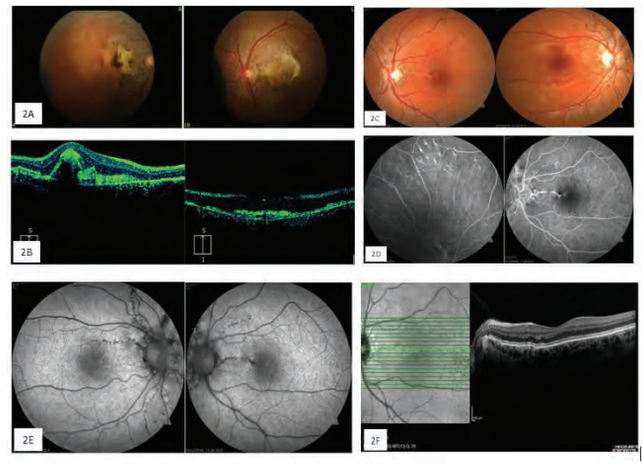

Figure 2. In ophthalmic examination of the first case: Color fundus photography of a patient with angioid streaks around the optic disc (A); chorioretinal scar due to the choroidoretinal neovascularization (B); In ophthalmic examination of the second case: Color fundus photo showing typical angioid streaks and peau d'orange appearance in the temporal of the macula (C); Window defect in fluorescein angiography due to atrophy of RPE adjacent to angioid streaks (D); Fundus autofluorescence (FAF) imaging shows areas of hypo-autofluorescence in the peripapillary area that are greater in size than the corresponding AS seen on color photography (E); SD-OCT findings of the patient showing breaks in Bruch's membrane with preservation of the overlying retina pigment epithelium. The yellow line indicates the location of the SD-OCT scan (F).

usually occur between the first and second decades of the patient's life [3]. The skin lesions typically consist of small, asymptomatic, yellowish, or skin-colored papules, which progressively coalesce into larger plaques and plaques due to cutaneous laxity [2, 3]. Skin alterations commonly appear during childhood and progress slowly and unpredictably during adulthood. They are initially located on the lateral and posterior regions of the neck. Flexural skin areas are frequently involved in the progression of the disease. Mucosal lesions of the oral cavity and genital area can also be detected and resemble cutaneous changes. Although the cutaneous lesions principally represent a cosmetic problem, they predict the risk for development of ocular and cardiovascular manifestations, with a considerable morbidity and occasional mortality [2, 3]. Because the lesions are thin and asymptomatic, the diagnosis is delayed [2]. In our two cases, the cutaneous lesions of PXE were asymptomatic. While the cutaneous lesions of PXE in the first patient were detected fourth decades of the patient's life, the cutaneous lesions of PXE in the second patient were detected second decades of the patient's life.

Ophthalmological features of PXE include primarily peau d'orange, comet lesions, angioid streaks, choroidal neovascularization (CNV), hemorrhages. Other ocular signs of PXE include chorioretinal atrophies, optic disk drusen and disciform scar [2, 3]. Peau d'orange is the earliest funduscopically visible alteration in patients with PXE, preceding the development of angioid streaks. Angioid streaks are the most obvious and consistent features of PXE fundus abnormalities. Approximately 85% of patients with PXE exhibit angioid streaks caused by dehiscence of the Bruch membrane, which appears thickened, calcified, and abnormally fragile. Angioid streaks are characteristic, but not pathognomonic. In later stages of the disease, an ingrowth of fibrovascular tissue through the defect may occur, giving way to secondary CNV and subsequent development of a disciform scar with subretinal fibrosis and atrophy [1, 2]. Secondary degenerative and hemorrhagic changes in the macula can frequently be found, leading to the severe reduction of visual acuity [1]. The vision blurring symptoms in our first case were due to the secondary CNV which was occurred as a complication of the dehiscence of the Bruch membrane. There were no visual complaints in our second case, where only angioid streaks, peau d'orange appearance, comet signs and breaks in Bruch's membrane which was visualized in OCT scans were detected. These patients, like in our case 2, should be examined much closely than other patients. Because Bruch membrane breaks may cause CNV and these membranes may cause severe vision blurring when untreated.

In the cardiovascular system, the calcification of artery walls of small and medium caliber is observed [1, 2]. The patients of PXE can also develop premature atherosclerosis with early acute myocardial infarcts [2, 3]. Alterations in lipoprotein composition and bleeding diathesis were found in plasma samples of PXE patients [2].

The diagnosis is clinical, associated with histopathological examination, which is characteristic and reveals fragmented and distorted elastic fibers in the reticular and deep dermis. These changes are more evident in the Verhoeff, Van Giesson and Calleja stains, specific for the elastic tissue [2, 3]. The clinic manifestation of skin lesions, ocular lesions, and histopathological findings in skin lesions in both of our cases were compatible with PXE.

Numerous systemic and dermatologic disorders could manifest clinical and histological features resembling classic PXE. Moreover, the absence of skin alterations does not exclude a diagnosis of PXE [2]. Cutaneous lesions of PXE-like phenotype have been described in association with vitamin-K dependent coagulation factor deficiency [4]. The histological finding is indistinguishable from classic PXE on light microscopy [4]. Other dermatologic disorders resembling PXE are cutis laxa, fibroelastolytic papulosis, PXE-like papillary dermal elastolysis, late-onset focal dermal elastosis, and perforating calcific elastosis [2]. The elastosis perforans serpiginosa, upper and mid-dermal elastolysis, papular elastorrhexis and linear focal elastosis, can manifest similar histological phenotypes as observed in PXE [2]. Clinical features are closely resembling PXE are also reported in association with inherited hemoglobinopathies [2].

Angioid streaks are also associated with a many of disorders, including Paget disease, hemoglobinopathies and Marfan [2]. These diseases should be considered in the differential diagnosis of the PXE patients with angioid streaks.

There is no specific or effective treatment in PXE. The therapeutical management is based on prevention and monitoring of complications associated with the disease [1]. Surgery for aesthetic improvement of cutaneous lesions is not routinely performed. However, significant progress has been made in the therapy of ocular complications [2, 5]. The diet supplemented with magnesium and vitamin K may extend the progression of the disease [1].

In conclusion, one must be aware of the need for early diagnosis, recognizing the typical cutaneous manifestations of the disease and better management of the associated complications when these are present [2].

Competing interests

No conflict of interest was declared by the authors.

References

1. Marques GF, Nakandakari S, Coelh APCP, Nigro MHMF, Sabage J. Pseudoxanthoma elasticum: report of two cases. A Bras Dermatol. 2014; 89(5): 812-5.
2. Marconi B, Bobyr I, Campanati A, Molinelli E, Consales V, Brisigotti V, et al. Pseudoxanthoma elasticum, and skin: Clinical manifestations, histopathology, pathomechanism, perspectives of Treatment. Intractable & Rare Diseases Research. 2015; 4(3):113-22.
3. Decani S, Varoni EM, Baruzzi E, Moneghini L, Lodi G, Sardella A. Pseudoxanthoma elasticum of the palate: a case report and a brief review of the literatüre. Oral Surg Oral Med Oral Pathol Oral Radiol. 2016; 121: e6-e9.
4. Hosen MJ, Lamoen A, De Paepe A, Vanakker OM. Histopathology of pseudoxanthoma elasticum and related disorders: Histological hallmarks and diagnostic clues. Scientifica (Cairo). 2012; 2012:598262.
5. Finger RP, Charbel Issa P, Ladewig MS, Götting C, Szliska C, Scholl HP, et al. Pseudoxanthomaelasticum: genetics, clinical manifestations, and therapeutic approaches. Surv Ophthalmol. 2009; 54:272-85.

How to cite this article:

Pektas SD, Demirtas O, Gul G, Dere Y, Sarı SB, Dogan G, Karalezli A. Pseudoxanthoma Elasticum: Report of Two Cases. J Clin Anal Med 2017;8(suppl 3): 228-30.