A Rare Cause of Renal Atrophy: Subcapsular Collection Presented as a Huge Perirenal Complex Cyst

Renal Atrofinin Nadir Bir Sebebi: Dev Perirenal Kompleks Kist Şeklinde Prezente Olan Subkapsüler Koleksiyon

Subcapsular Collection Presented as Perirenal Cyst

Abidin Kılınçer[1], Emre Ünal[2], Orhan Yıldız[3]
[1]Department of Radiology, Zile State Hospital, Zile, Tokat,
[2]Department of Radiology, Hacettepe University School of Medicine, Sıhhiye, Ankara,
[3]Department of Urology, Zile State Hospital, Zile, Tokat, Turkey

Öz

Renal subkapsüler koleksiyonlar tedavi edilmezse renal atrofi ile sonuçlanabilir. Tekrarlayan hemoraji epizodları koleksiyonun karmaşık görünümlü olmasına neden olduğu için kronik dönemde tanı koymak oldukça zor olabilir. Biz bu yazımızda 44 yaşındaki bir erkek olguda böbrek atrofisinin nadir bir sebebini sunuyoruz.

Anahtar Kelimeler

Atrofik Böbrek; Kompleks Kist; Subkapsüler Koleksiyon; MRG; BT

Abstract

If left untreated, renal subcapsular collections may result in renal atrophy. The diagnosis could be challenging at chronic stage due to recurrent episodes of hemorrhage which is the reason for the complex appearance of the collection. Herein we report a rare cause of renal atrophy in a 44-year-old man.

Keywords

Atrophic Kidney; Complex Cyst; Subcapsular Collection; MRI; CT

DOI: 10.4328/JCAM.5179 Received: 28.06.17 Accepted: 30.08.17 Printed: 01.06.2017 J Clin Anal Med 2017;8(suppl 3): 237-9
Corresponding Author: Abidin Kılınçer, Department of Radiology, Zile State Hospital, Zile, 60400, Tokat, Turkey.
T.: +90 3563175098 GSM: +905536591317 E-Mail: akilincer@yahoo.com

Introduction

The contents of the renal subcapsular collections may vary depending on the etiology [1,2]. Subcapsular collections may induce significant pressure on renal parenchyma due to boundary effect of renal capsule. In the setting of renal vessel compression, one may identify the new onset of increased blood pressure due to activation of the renin-angiotensin system, which is also called as Page kidney [2,3]. However, in the case of long standing compression, the kidney may undergo atrophy and imaging based evaluation could be challenging. Herein we report a rare case of chronic renal subcapsular collection presented as a huge complex cystic mass resulting in significant right kidney atrophy.

Case Report

A previously healthy 44-year-old man was admitted to our hospital with a two days history of right back pain radiating through to right inguinal region. He was afebrile, and his blood pressure was within the normal range. There was no history of trauma. The urinary test revealed lack of hematuria. Serum creatinine level was normal (0.76 mg/dL). Abdominal radiography demonstrated a calcified ovoid mass in right flank (Figure 1). Ultrasonography revealed the cystic nature of the lesion with fluid-fluid level (Figure 2). Abdominal CT examination demonstrated a peripherally calcified, huge (sized 10 x 13 cm) cystic mass in right renal fossa (Figure 3). The right kidney was absent however there was a non-specific soft tissue density with a few punctate calcifications between the cystic mass and inferior vena cava (Figure 3). The left kidney was unremarkable except for hypertrophy. The right adrenal gland and urinary bladder were normal. Contrast-enhanced MRI examination was suggestive of right renal atrophy, however, neither renal artery nor renal vein were apparent on postcontrast images. The extension of the cyst was indicative of subcapsular origin (Figure 4). The patient underwent surgery, and histopathological examination revealed collagenized and calcified cyst wall associated with atrophic renal parenchyma and pelvicalyceal system. There was no sign of granulomatous reaction in histopathological examination, and also acid-fast bacillus staining was negative for tuberculosis. Urine culture test and chest radiograph were also unremarkable.

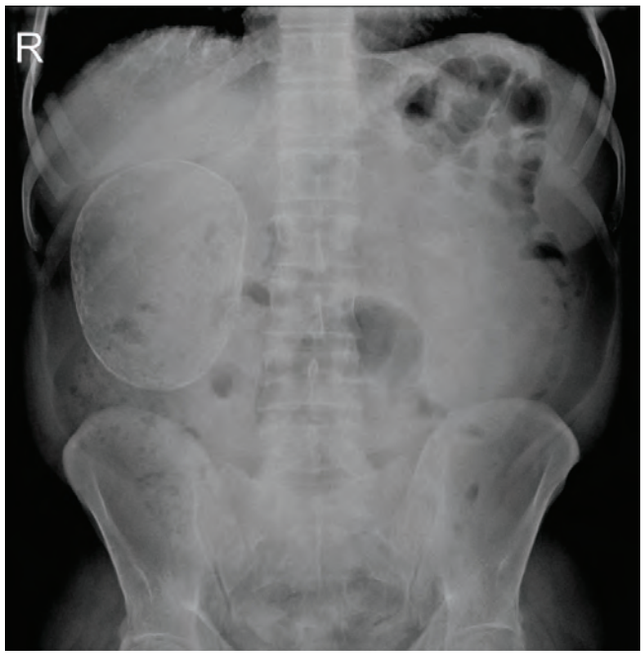

Figure 1. Abdominal radiography demonstrates a peripherally calcified ovoid mass in the right flank.

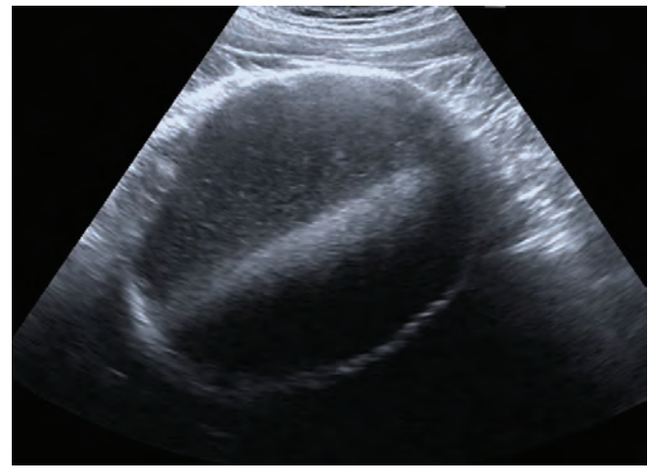

Figure 2. Gray scale sonogram reveals fluid-fluid level within the cyst lumen.

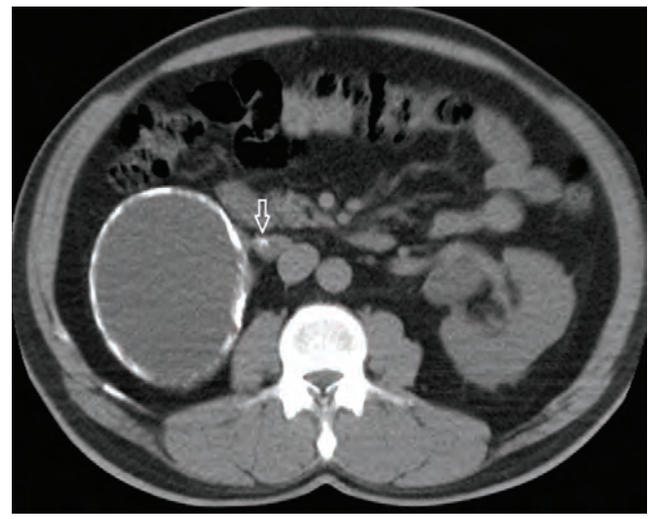

Figure 3. Axial unenhanced CT image shows nonspecific calcification containing soft tissue density located between the cystic mass and inferior vena cava (arrow).

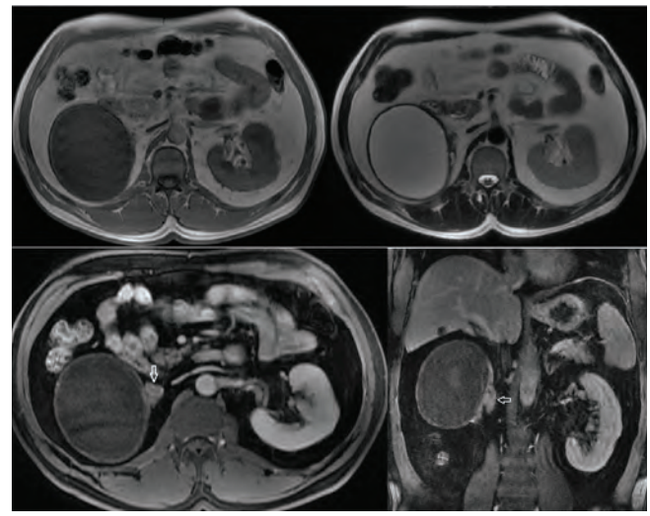

Figure 4. Axial T1 (a) and T2 (b) weighted MR images reveal lack of hemorrhage and debris within the cyst. Axial (c) and coronal (d) post-contrast fat saturated T1 weighted MR images demonstrate contrast enhancement adjacent to the cyst compatible with atrophic right kidney (arrows). The extension of the cyst indicates subcapsular origin (a-d).

Discussion

Herein reported case indicates that renal subcapsular collections may result in significant parenchymal atrophy at late stage. Compensatory hypertrophy of the contralateral kidney also suggests chronic state of the insult. The main limitation for further conclusion is that we were not able to evaluate previous radiological examinations of the patient. The patient's presenting symptom was newly onset of back pain. Although back pain is a nonspecific complaint that could be seen in various conditions, one may suggest complication of an existing cyst. However pathological examination revealed lack of hemorrhage and pus. Therefore, complication of a cyst was less likely the diagnosis. Also, the definition of "collagen-rich cyst wall" in pathologic report points out the renal capsule. Collagen is reported to be found in ultrastructure of the renal capsule as opposed to renal cysts which are collagen free. However, the underlying pathophysiology of our case remains unclear. Communication of subcapsular collection with the lymphatic system could be questioned as a triggering factor for fluid layering. However, pathological examination revealed lack of such association as well. The presenting symptom could be related to another cause (i.e., lumbar disc hernia or myalgia), and the renal atrophy could be incidentally diagnosed.

A hematoma is the most frequent type of renal subcapsular collection and may occur following trauma, anticoagulant therapy, and interventional procedures [1, 4-6]. Renal subcapsular pseudocyst may also be encountered as a complication of acute pancreatitis [3]. A urinoma can also be the underlying cause of subcapsular collection particularly in the setting of obstructive uropathy (i.e., ureteral stone, retroperitoneal fibrosis, bladder cancer) complicated by forniceal rupture [7,8]. On the other hand, trauma may also result in subcapsular urinoma as well [2]. In case of bilateral renal subcapsular collection presence of renal parenchymal diseases (i.e., membranoproliferative and focal-segmental glomerulonephritis) could be questioned [9,10]. In our case, neither imaging findings nor clinicopathological signs were able to reveal the underlying cause of renal subcapsular collection.

Lin et al. reported a case of tuberculosis autonephrectomy presented with a huge cystic mass with lack of normal appearing right kidney [11]. The cyst had calcified wall, and imaging findings were similar to our case. However, the urine culture test was positive for Mycobacterium tuberculosis in their case which is contrary to our findings. Moreover, the presence of compressed and atrophic kidney seen in our case is unusual for tuberculosis autonephrectomy.

In conclusion, renal subcapsular collections may result in renal atrophy, and the underlying cause may remain unknown particularly in patients presented at late stage. Presence of atrophic kidney adjacent to cystic mass indicates capsular-subcapsular origin of the cyst.

Acknowledgements

The authors thank Prof. Muşturay Karçaaltıncaba MD (Department of Radiology, Hacettepe University, School of Medicine) for his kind guidance.

Author contributions

Concept – A.K., E.Ü.; Design - A.K.; Supervision - A.K., E.Ü.; Resource - A.K., O.Y.; Materials - A.K., O.Y.; Data Collection and/or Processing - A.K., O.Y.; Analysis and /or Interpretation - A.K., E.Ü.; Literature Search - A.K.; Writing - A.K., E.Ü.; Critical Reviews - A.K., E.Ü.

Informed Consent

Written informed consent was obtained from the patient who participated in this study.

Conflict of Interest

No conflict of interest was declared by the authors.

Funding

The authors declared that this study has received no financial support.

References

1. Sherman SC, Dogon A. Subcapsular renal hematoma after shock wave lithotripsy. J Emerg Med. 2006;30(4):437-9.
2. Matlaga BR, Veys JA, Jung F, Hutcheson JC. Subcapsular urinoma: an unusual form of page kidney in a high school wrestler. J Urol. 2002;168(2):672.
3. Aswani Y, Anandpara KM, Hira P. Page kidney due to a renal pseudocyst in a setting of pancreatitis. BMJ Case Rep. 2015;2015.
4. Ferrando F, Budia A, Mira Y, Vaya A, Aznar J. Spontaneous renal subcapsular hematoma in an anticoagulated patient. Clin Appl Thromb Hemost. 2006;12(1):89-92.
5. Yi JS, Lee HJ, Lee HJ, Yang JH. Renal subcapsular hematoma after percutaneous transfemoral angiography. J Korean Neurosurg Soc. 2014;55(2):96-8.
6. Zhang P, Hu WL. Sudden onset of a huge subcapsular renal hematoma following minimally invasive ureteroscopic holmium laser lithotripsy: A case report. Exp Ther Med. 2015;10(1):335-7.
7. Goyal NK, Goel A, Singh V, Sankhwar SN. Bladder cancer presenting with spontaneous subcapsular urinoma of kidney. Indian J Cancer. 2015;52(3):473-4.
8. Sakai Y. A case of idiopathic retroperitoneal fibrosis with renal subcapsular urinoma resolved by steroid therapy. Hinyokika Kiyo. 1999;45(4):249-51.
9. Yalcin AU, Akcar N, Can C, Kasapoglu E, Sahin G. An unusual presentation for nephrotic syndrome. Bilateral perirenal subcapsular fluid collection. Nephron. 2002;92(1):244-5.
10. Aliasgari M, Atabak S, Lashay A, Amini E, Shahabi A. Bilateral perirenal subcapsular fluid collection: a rare presentation of renal parenchymal disease. Urol J. 2010;7(1):61-2.
11. Lin YL, Fan YC, Cheng CY, Sue YM, Hsu YH, Hou CC, et al. The case Sterile pyuria and an abnormal abdominal film. "Autonephrectomy" of right kidney. Kidney Int. 2008;73(1):131-3.

How to cite this article:

A Rare Cause of Renal Atrophy: Subcapsular Collection Presented as a Huge Perirenal Complex Cyst. Kılınçer A, Ünal E, Yıldız O. J Clin Anal Med 2017;8(suppl 3): 237-9.