The Case of Frontal Linear Scleroderma (En Coup De Sabre)

Frontal Lineer Skleroderma (En Coup De Sabre) Olgusu

En Coup De Sabre

Gülhan Gürel[1], Sevinç Şahin[2], Emine Çölgeçen[1]
[1]Department of Dermatology, [2]Department of Pathology, Bozok University School of Medicine, Yozgat, Turkey

*This study was presented as an e-poster in 12. Aegean Dermatology Days, held in Bodrum between May 10th-14th.

Öz

En coup de sabre terimi frontal ya da frontoparyetal bölgede özel bir görünüme sahip olan linear skleroderma'nın nadir bir varyantıdır. Etiyolojisi net olarak bilinmemekle birlikte otoimmün kaynaklı olabilir. Nörolojik ve oftalmolojik bulgularla beraber olabilen bu hastalık çocuklarda daha sık görülmektedir. On sekiz yaşında kadın hasta polikliniğimize yaklaşık 4 yıldır alın orta hatta çöküntü ve renk değişikliği şikayetiyle başvurdu. Dermatolojik muayenesinde frontal bölgede orta hattan saçlı deriye doğru uzanan atrofik, lineer , deprese plak lezyonu mevcuttu. Hastaya mevcut klinik ve histopatolojik bulgularla ' linear skleroderma (En coup de sabre)' tanısı konuldu. Hastanın yapılan göz muayenesinde patolojik bulguya rastlanmadı. Nörolojik muayenesi normal olan hastanın kranial magnetik rezonans incelemesinde beyinde patolojik bulguya rastlanmadı.

Anahtar Kelimeler

En Coup De Sabre; Skleroderma

Abstract

En coup de sabre is a rare variation of linear scleroderma, which has a special appearance in the frontal or frontoparietal region. Although the etiology is not clearly known, it can be an autoimmune origin. This disease, which may be associated with neurological and ophthalmological findings, is more common in children. An 18-year-old female patient was admitted to our polyclinic with complaints of collapse and discoloration on the forehead line for approximately four years. The dermatologic examination revealed an atrophic, linear, and depressed lesion on the frontal region extending to the scalp. The patient was diagnosed with 'linear scleroderma (En coup de sabre)' with clinical and histopathological findings. No pathological findings were found on the ophthalmic examination of the patient. Neurological examination was normal and cranial magnetic resonance imaging revealed no pathological findings in the brain.

Keywords

En Coup De Sabre; Scleroderma

DOI: 10.4328/JCAM.5206 Received: 06.07.2017 Accepted: 27.06.2017 Printed: 01.06.2017 J Clin Anal Med 2017;8(suppl 3): 222-4
Corresponding Author: Gülhan Gürel, Department of Dermatology, Medical Faculty, Bozok University, 66200 Yozgat, Turkey.
Tel: +90 3542127060 F.: +90 3542177150 E-Mail: gulhanozturkgurel@hotmail.com

Introduction

Morphea (localized scleroderma) is an inflammatory skin disease that causes sclerosis in the dermis and subcutaneous adipose tissue [1]. Linear scleroderma is the most common form of localized scleroderma in children and adults. The term en coup de sabre (ECDS) is used to describe a variant form of linear scleroderma, which has a special appearance in the frontal or frontoparietal region. ECDS emerges in the form of linear, erythematous bands, and gradually transforms into firm plaques. It is usually seen on the paramedian region on the forehead and is unilateral [2]. Here, we present a case of an 18-year-old female patient, who is diagnosed with ECDS after clinical and histological examinations.

Case Report

An 18-year old female patient was admitted to our clinic with collapse and discoloration on the forehead line. The patient's medical history showed that pink-purple color change started approximately four years ago, which was followed by a progressive collapse on the forehead line. The patient's family history did not show anyone with a similar disease. Systemic examination was normal, and physical examination did not show any pathological findings. Dermatologic examination showed that the patient had an atrophic, linear, and depressed lesion on the frontal region extending to the scalp [Figures 1 and 2]. The patient's routine laboratory tests results were within expected intervals. The patient underwent skin biopsy from the frontal region. A written informed consent form was obtained before the procedure.



Figures 1 and 2. Atrophic, linear, and depressed plaque lesion on the frontal region, extending from midline to the scalp.

Histopathological examination showed superficial orthokeratosis and irregular acanthosis in the epidermis. An increase in the number of thick, homogenized, collagen fibers, involving the whole dermis and affecting the subcutaneous adipose tissue, and intermittent atrophy in skin adnexa were present [Figure 3]. Verhoeff-Van Gieson staining (VVG) showed thick, fragmented, elastic fibers laying parallel to the dermis surface [Figure 4].

In light of clinical and histopathological findings, the patient was diagnosed with linear scleroderma (ECDS). The ophthalmic examination did not reveal any pathological findings. The patient's neurological examination was normal, and cranial magnetic resonance imaging (MRI) did not show any pathological findings in the brain.

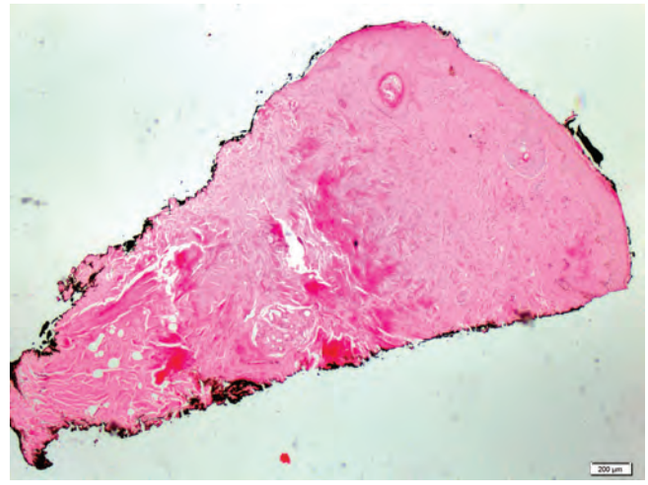

Figure 3. Punch skin biopsy showing loss of skin adnexa, and increased number of homogeneous, collagen fibers in the dermis and subcutaneous adipose tissue (H&E staining, x40).

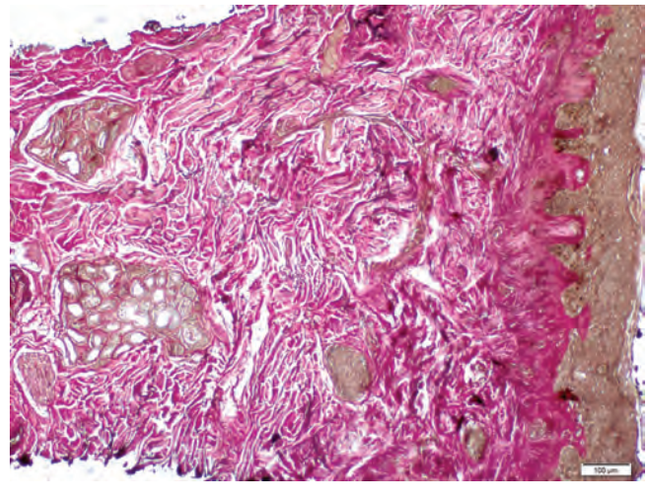

Figure 4. Thick, fragmented, elastic fibers laying parallel to the dermis surface (VVG staining, x100).

Discussion

ECDS is a rare variant of morphea. The disease is usually seen during childhood, and the average age at onset is ten years [2]. A retrospective study on 82 patients indicated that ECDS has an incidence of 0.13/100,000 [3].

Similar to other types of scleroderma, the exact etiology of ECDS remains unknown [2,4]. The disease is considered to have an autoimmune origin and triggered by environmental factors. The exact relationship between progressive facial hemiatrophy (Parry Romberg Syndrome), which is characterized by progressive atrophy on one half of the face, and ECDS is not known. Still, given the similarities in the pathogenesis of these diseases, they are considered to lie on different ends of the spectrum of the same disease [5]. In the present study, our patient did not have facial atrophy.

Neurological involvement with ECDS has been identified in 18-47% of the cases. Epileptic seizures are the most common symptoms, while hemiparesis, muscle weakness, headache, personality changes, and deterioration in intellectual functions have also been reported [6,7]. Our patient's neurological examination was normal, and cranial MRI did not reveal any pathological findings. It is also possible to detect ophthalmologic anomalies in ECDS; however, our patient did not have any

abnormal findings in the ophthalmic examination.

Methotrexate and systemic glucocorticoids represent the first line treatment for ECDS, and it is recommended to maintain treatment with UVA1, PUVA photochemotherapy, narrowband UVB or mycophenolate mofetil. Other treatment options include topical tacrolimus, topical vitamin D and glucocorticoid combinations, and imiquimod [8].

In conclusion, we wanted to present this case as ECDS represents a rare variant of morphea.

Ethical Responsibilities: All institutional and national guidelines for the care and use of laboratory animals were followed.

Conflict of Interest: No potential conflict of interest relevant to this article was reported.

Funding: The funders had no role in study design, data collection, and analysis, decision to publish, or preparation of the manuscript.

Competing interests

The authors declare that they have no competing interests.

References

1.Izol B, Sarıcaoglu H, Baskan EB, Toka SO, Adım SA, Aydogan K, et al. [Pediatric morphea (localized scleroderma)-Epidemiological, clinical and laboratory findings of 14 cases]. Turkderm. 2011;45(3):132-6.

2. Miller K, Lehrhoff S, Fischer M, Meehan S, Latkowski JA. Linear morphea of the forehead (en coup de sabre). Dermatol Online J. 2012;18(12):22.

3.Peterson LS, Nelson AM, Su WP, Mason T, O'Fallon WM, Gabriel SE. The epidemiology of morphea (localized scleroderma) in Olmsted County 1960-1993. J Rheumatol. 1997;24(1):73-80.

4. Katz KA. Frontal linear scleroderma (en coup de sabre). Dermatol Online J. 2003;9(4):10.

5. Tollefson MM, Witman PM. En coup de sabre morphea and Parry-Romberg syndrome: a retrospective review of 54 patients. J Am Acad Dermatol. 2007;56(2):257-63.

6.Polcari I, Moon A, Mathes EF, Gilmore ES, Paller AS. Headaches as a presenting symptom of linear morphea en coup de sabre. Pediatrics. 2014;134(6):1715-9.

7.Pinho J, Rocha J, Sousa F, Macedo C, Soares-Fernandes J, Cerqueira J, et al. Localized scleroderma en coup de sabre in the Neurology Clinic. Mult Scler Relat Disord. 2016;8:96-8.

8. Zwischenberger BA, Jacobe HT. A systematic review of morphea treatments and therapeutic algorithm. J Am Acad Dermatol. 2011;65(5):925-41.

How to cite this article:

The Case of Frontal Linear Scleroderma (En Coup De Sabre). Gürel G, Şahin S, Çölgeçen E. J Clin Anal Med 2017;8(suppl 3): 222-4.