Reliability of magnetic resonance imaging in rotator cuff and biceps tendon pathologies

Rotator manşet ve biseps uzun başı tendonu patolojilerinde manyetik rezonans görüntülemenin güvenirliği

Magnetic resonance imaging in shoulder tendons

Mehmet Hamdi Şahan[1], Sancar Serbest[2], Uğur Tiftikçi[2], Mikalil İnal[1], Veysel Burulday[1]
[1]Department of Radiology, [2]Department of Orthopedics and Traumatology,
Kırıkkale University School of Medicine, Kırıkkale, Turkey

The Turkish Magnetic Resonance Society has been presented as an oral presentation for the 22nd annual scientific meeting to be held on May 25-27, 2017.

Öz

Amaç: Biz bu çalışmada omuz ağrısı ve disfonksiyonun en önemli nedenlerinden olan rotator manşet lezyonları ve biseps uzun başı tendonu patolojilerinde, artroskopi ile karşılaştırmalı olarak manyetik rezonans görüntülemenin tanısal performansını incelemeyi amaçladık. Gereç ve Yöntem: Artroskopik cerrahi uygulanmış 180 hasta tespit edildi. Bu hastalardan öncesinde tanısal manyetik rezonans görüntüleme tetkiki olan ve çalışma kriterlere uyan 17'si erkek, 47'si kadın toplam 64 hasta çalışmaya dahil edildi. Artroskopik cerrahi öncesi 6 hafta süre içerisinde çekilen manyetik rezonans görüntüleme bulguları ile artroskopik omuz eklem muayene bulguları retrospektif olarak incelendi. Bulgular: Supraspinatus tendonu tam kat yırtıklarında sensitivite %89.1, spesifisite %94.4, parsiyel yırtıklarda sensitivite % 93.8, spesifisite %87.5, biseps uzun baş tendonu tam kat yırtıklarında sensitivite %33.3, spesifisite %98.4, parsiyel yırtıklarda sensitivite %58.3, spesifisite %80.8 saptandı. Artroskopide 24 (%37.5) hastada, manyetik rezonans görüntülemede 32 (%50) hastada birden fazla tendonda yırtık saptandı. Ayrıca rotator manşet yırtıklarında artroskopide 15 (%23.4), manyetik rezonans görüntülemede 19 (%29.6) hastada biseps uzun başı tendon yırtıklarının birlikteliği tespit edilmiştir. Tartışma: Manyetik rezonans görüntüleme rotator manşet tendonu patolojilerinde, artroskopi ile karşılaştırmalı olarak, özellikle supraspinatus tendonu yırtıklarında yüksek doğruluk, kappa değeri (kappa değeri: 0,78) ile güçlü tutarlılık aralığında sensitivite ve spesifisitesi yüksek bulunmuştur. Ancak biseps uzun başı tendon patolojilerinde sensitivite düşük tespit edilmiştir. Manyetik rezonans görüntüleme günümüzde, omuz tendonu patolojilerinde özellikle rotator manşet tendonu patolojilerinde güvenilir tanı yöntemi olarak yerini korumaktadır.

Anahtar Kelimeler

Rotator Manşet; Biseps Uzun Başı; Tam Kat Yırtık; Parsiyel Yırtık; Manyetik Rezonans Görüntüleme

Abstract

Aim: In the study, we aimed to evaluate the diagnostic performance of magnetic resonance imaging in comparison with arthroscopy in rotator cuff lesions and pathologies of the long head of the biceps tendon, which are one of the most important causes of shoulder pain and dysfunction. Material and Method: 180 patients treated with arthroscopic surgery were identified. Sixty-four patients (17 males, 47 females) who had undergone diagnostic magnetic resonance imaging and met the study criteria were enrolled in the study. The magnetic resonance imaging within the last 6 weeks preoperatively and arthroscopic shoulder joint examination findings during the operation were reviewed retrospectively. Results: Sensitivity was found to be 89.1% and specificity was found to be 94.4% in the full thickness tears, and sensitivity was found to be 93.8% and specificity was found to be 87.5% in the partial tears of the supraspinatus tendon; sensitivity was found to be 33.3% and specificity was found to be 98.4% in the full-thickness tears, and sensitivity was found to be 58.3% and specificity was found to be 80.8% in the partial tears of the long head of the biceps tendon. 24 (37.5%) patients in arthroscopy and 32 (50%) patients in magnetic resonance imaging had more than one tear in the tendon. Furthermore, the combination of the tears of the long head of the biceps tendon was found in the rotator cuff tears' arthroscopy of 15 patients (23.4%) and magnetic resonance imaging of 19 (29.6%) patients. Discussion: In comparison with arthroscopy, magnetic resonance imaging in rotator cuff tendon pathologies, especially in the supraspinatus tendon tears, demonstrated high accuracy, the kappa value (kappa value: 0.78), high sensitivity and specificity in the strong consistency range. However, sensitivity was low in pathologies of the long head of the biceps tendon. Magnetic resonance imaging remains to be a reliable diagnostic method in shoulder tendon pathologies, especially in rotator cuff tendon pathologies.

Keywords

Rotator Cuff; Biceps Long Head; Full Thickness Tear; Partial Tear; Magnetic Resonance Imaging

DOI: 10.4328/JCAM.5035 Received: 25.04.2017 Accepted: 23.05.2017 Printed: 01.12.2017 J Clin Anal Med 2017;8(suppl 4): 310-5
Corresponding Author: Mehmet Hamdi Şahan, Department of Radiology, Kırıkkale University School of Medicine, 71450, Kırıkkale, Turkey.
GSM: +905056480687 E-Mail: drmehmetsahan@hotmail.com

Introduction

Shoulder pain is the third most common clinical complaint of the musculoskeletal system, and it is observed in 7-26% of adults [1]. Among the causes of shoulder pain and dysfunction, rotator cuff lesions are among the leading causes according to their prevalence. The rotator cuff tear is observed in 65-70% of cases and its prevalence increases with age [1-2]. Moreover, pathologies of the long head of the biceps tendon are mostly associated with rotator cuff tears and are among the most important causes of anterior shoulder pain [3]. Therefore, it is very important that the rotator cuff and the long head of the biceps show integrity in patients consulting with complaints of shoulder pain and dysfunction [3].

Nowadays, many imaging methods such as ultrasonography, computed tomography (CT), CT-arthrography, Magnetic Resonance Imaging (MRI), and magnetic resonance- arthrography are used for this purpose. In recent years, the fact that intraarticular and periarticular structures can be displayed in more detail with the increased spatial resolution in MRI has made MRI one of the most preferred diagnostic methods in the evaluation of shoulder joint pathologies nowadays [1,2].

In the study, we aimed to examine the diagnostic performance of MRI in comparison with arthroscopy in pathologies of the rotator cuff and the long head of the biceps tendon, which are among the most important causes of shoulder pain and dysfunction.

Material and Method

Study Population and inclusion criteria

180 patients, who had undergone arthroscopic surgery due to shoulder pain, dysfunction, and rotator cuff pathology between January 2014 and November 2016, were retrospectively identified. 64 patients who had undergone the diagnostic MRI examination and matched the criteria were included in the study. Among the patients, 17 were male, 47 were female, the age average was 56.1+9.8 years, the age range was 37-74 years. The MRIs of all the patients taken within 6 weeks before arthroscopic surgery were examined retrospectively. The local ethics committee approval was received before starting the study (Kırıkkale University clinical research ethics committee, decision no: 10/01, date 11.04.2017).

Exclusion Criteria

Furthermore, patients with adhesive capsulitis, who had undergone a surgical operation on the same side of the shoulder, having massive rotator cuff tear with pseudoparalysis, advanced osteoarthritis, large-scale (bigger than 2 cm) retracted tears associated with atrophy in the rotator cuff muscles and fatty degeneration were not included in the study. The MRI taken at the external center, cases whose MRIs had been taken 6 weeks before the arthroscopic surgery, and patients whose MRI records could not be accessed were excluded from the study.

Arthroscopy

The patients were operated under general anesthesia and in the sitting position called the beach chair position. Initially, the acromion, distal clavicle, acromioclavicular joint, coracoid, and portals were marked with a surgical marker. The posterior portal was opened approximately 2 cm medial and 2 cm inferior of the posterolateral corner of the acromion. The anterior portal was opened approximately 2-3 cm anterior of the anterolateral corner of the acromion, and the lateral portal was opened approximately 2-4 cm lateral of the posterior of the acromioclavicular joint. An arthroscopic examination of the glenohumeral joint was performed through the posterior portal. The tendons forming the rotator cuff and the tear in the long head of the biceps tendon were displayed fully, and their sizes and shapes were recorded.

Magnetic resonance imaging protocol and interpretation

MRI was performed with 1.5 Tesla MR device (Philips MRI Systems, Achieva Release 3.2 Level 2013-10-21, Philips Medical Systems Nederland B.V) using the surface shoulder coil. In the examination, T1 weighted; T1-TSE (Turbo Spin-Echo) axial, T1-TSE oblique coronal (780/15; FOV 14 cm; cross-sectional thickness 3.5 mm; intersection gap 0.4 mm; matrix 320 × 256), T2 weighted; T2-FFE (Fast-Field Echo) axial, T2-TSE oblique sagittal, T2 weighted fat-suppressed, T2-SPAIR (spectral attenuated inversion recovery) axial and oblique coronal (3400/50; FOV, 14 cm; cross-sectional thickness 3.5 cm; intersection gap 0.4 mm; matrix, 256 × 256) images were obtained. All MRIs were retrospectively examined by two radiologists experienced in the musculoskeletal subject (MHŞ, MI).

The pathologies of the rotator cuff tendons, partial and full-thickness tears were examined. The absence or discontinuity of the tendon in the supraspinatus muscle was evaluated as a full-thickness tear (Figure 1a,b), and the limited focal defect on the articular or bursal surface of the tendon was evaluated as a partial tear. The absence or discontinuity of the tendon in the subscapularis and infraspinatus muscles was evaluated as a full-thickness tear (Figure 2), and the focal discontinuity, loss of integrity, and fluid increase in the tendon were evaluated as a partial tear. The pathologies in the long head of the biceps tendon, a supporter of the rotator cuff tendons, were evaluated as a full-thickness tear, partial tear, and tendon subluxation. The dislocation of the long head of the biceps tendon was not included in our study because it was not present in our patients. While the discontinuity of the tendon fibers in the long head of the biceps tendon and an empty bicipital groove in the axial and oblique sagittal sections were evaluated as a full-thickness tear, and the thinning, irregularity, fragmentation, signal increase in the tendon and liquid around the tendon and in the bicipital groove were evaluated as a partial tear (Figure 3a,b,c), the displacement of the long head of the biceps tendon from the bicipital groove to the medial was evaluated as a subluxation.

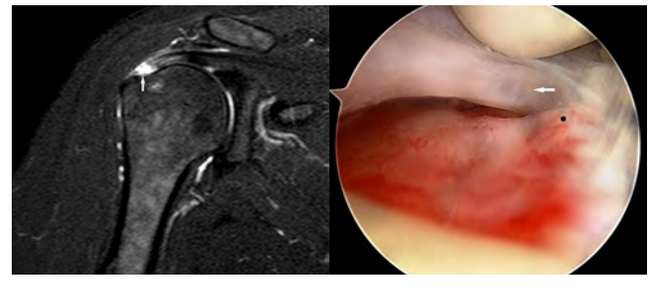

Figure 1. (a) The full-thickness tear in the supraspinatus tendon in oblique coronal T2-SPAIR (spectral attenuated inversion recovery) images in MRI (white arrow), (b) The full-thickness tear in the supraspinatus in the arthroscopy image in the same patient (white arrow), (* Tuberculum majus).

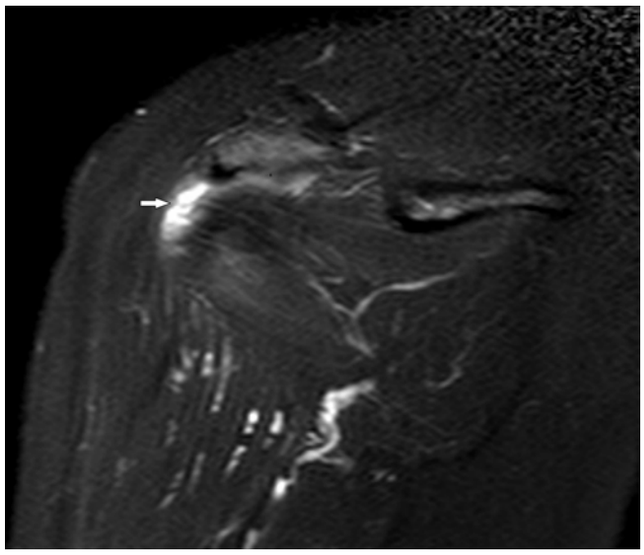

Figure 2. The full-thickness tear in the subscapularis tendon in oblique coronal T2-SPAIR (spectral attenuated inversion recovery) images in MRI (white arrow).

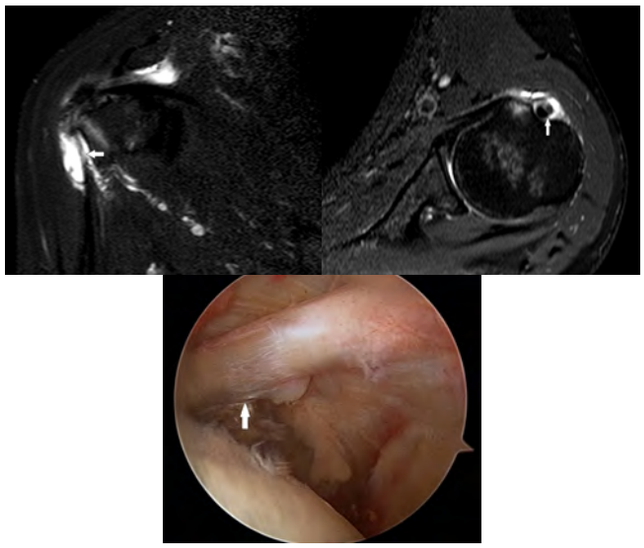

Figure 3. (a, b) The partial tear and the liquid in the tendon circumference in the long head of the biceps tendon in oblique coronal, axial T2-SPAIR (spectral attenuated inversion recovery) images in MRI, (c) The biceps tendon in the arthroscopic image of the same patient (white arrow).

Statistical analysis

The compatibility between the operation and MRI findings of the patients was compared statistically using the IBM SPSS 20.0 program with sensitivity, specificity, positive predictive and negative predictive values, accuracy, p-values, and the kappa analysis test. $p < 0.05$ was considered to be statistically significant. The receiver operating characteristic curves (ROC) were used for the efficacy of full-thickness and partial tear diagnosis of the supraspinatus and the long head of the biceps tendons of MRI.

Results

In arthroscopy, a full-thickness tear of the supraspinatus tendon was detected in 46 patients (71.9%) and a partial tear of the supraspinatus tendon was detected in 16 (25%) patients, and no tear was detected in the supraspinatus tendon in 2 patients (3.1%). There were a full-thickness tear in 4 patients (6.3%) and a partial tear in 6 patients (9.4%) in the subscapularis tendon, a full-thickness tear in 2 patients (3.1%) and a partial tear in 3 patients (4.7%) in the infraspinatus tendon, a full-thickness tear in 3 patients (4.7%) and a partial tear in 12 patients (18.8%) in the long head of the biceps tendon (Table 1). There was no tear in the teres minor tendon. Only full-thickness/partial tear was detected in 39 patients (60%) in the supraspinatus tendon, and no tear was detected in the supraspinatus tendon in 1 patient. Multiple tendon tears were detected in 24 patients (37.5%) (Table 2).

In the MRI examinations, a full-thickness tear of the supraspinatus tendon was detected in 43 (67.2%) patients and a partial tear of the supraspinatus tendon was detected in 20 (31.3%) patients, and no tears were detected in the supraspinatus tendon in 1 patient (1.6%). There were full-thickness tears in 2 patients (3.1%) and partial tears in 8 patients (12.5%) in the subscapularis tendon, full-thickness tears in 2 patients (3.1%) and partial tears in 5 patients (7.8%) in the infraspinatus tendon, full-thickness tears in 2 patients (3.1%) and partial tears in 17 patients (26.6%) in the long head of the biceps tendon, and subluxation in 3 patients (4.7%) (Table 1). No tear was detected in the teres minor tendon. Partial tear was determined in the tendon in the arthroscopy of patients with subluxation in the long head of the biceps tendon in MRI. While only full-thickness/partial tears were determined in 32 patients (50%) in the supraspinatus tendon, tears in other tendons together with

Table 1. The comparison of the sensitivity, specificity, positive predictive values (PPV), negative predictive values (NPV), accuracy, p-values, and kappa analysis test between the findings of arthroscopy and MRI.

Pathological findings	Arthroscopy(n)	MRI (n)	Sensitivity	Spesificity	PPV	NPV	Kappa values	Accuracy	P values
Full-thickness tears in supraspinatus tendon	46	42	89.1	94.4	97.6	77.3	0.78	90	0
Partial tears in supraspinatus tendon	16	21	93.8	87.5	71.4	97.7	0.73	89	0
Full-thickness tears in subscapularis tendon	4	2	50	100	100	96.8	0.65	96.8	0
Partial tears in subscapularis tendon	6	8	66.7	93.1	50	96.4	0.52	90	0.001
Full-thickness tears in infraspinatus tendon	2	2	100	100	100	96.9	1	100	0
Partial tears in infraspinatus tendon	3	5	100	96.7	60	100	0.73	96.8	0
Full-thickness tears in LHBT	3	2	33.3	98.4	50	96.8	0.37	95.3	0.02
Partial tears in LHBT	12	17	58.3	80.8	41.2	89.4	0.33	76.5	0.06
Subluxation in LHBT	Partial tears	3	-	-	-	-	-	-	-

The Long Head of the Biceps Tendon(LHBT), Magnetic Resonance Imaging (MRI), Negative Predictive Values (NPV), Positive Predictive Values (PPV)

Table 2. The comparison of the association of the pathologies of rotator cuff tendons and the long head of the biceps tendon.

Pathological findings	Arthroscopy (n=64)	MRI (n=64)
Full-thickness/partial tears in supraspinatus tendon	62 (96.8%)	63 (98.4%)
Full-thickness/partial tears in the other rotator cuff tendons	15 (23.4%)	15 (23.4%)
Full-thickness/partial tears in LHBT	15 (23.4%)	19 (29.6%)
Full-thickness/partial tears in supraspinatus tendon + LHBT	14 (21.8%)	17 (26.6%)
Full-thickness/partial tears in supraspinatus tendon + the other rotator cuff tendons	10 (15.6%)	15 (23.4%)
Full-thickness/partial tears in the rotator cuff tendons + LHBT	24 (37.5%)	32 (50%)

The Long Head of the Biceps Tendon(LHBT)
Magnetic Resonance Imaging (MRI)

supraspinatus tendon tears were determined in 32 patients (50%) (Table 2).

In MRI, sensitivity was 89.1% and specificity was 94.4% in full-thickness tears and sensitivity was 93.8% and specificity was 87.5% in partial tears of the supraspinatus tendon; sensitivity was 33.3% and specificity was 98.4% in full-thickness tears and sensitivity was 58.3% and specificity 80.8% in partial tears of the long head of the biceps tendon. The tears of the long head of the biceps tendon were determined to be associated with rotator cuff tears in 19 patients (29%) (Table 2).

The reliability of the rotator cuff tendons in MRI, and the kappa value, especially in the supraspinatus tendon tears (kappa value: 0.78), were found to be high and interpreted within the strong consistency range. Sensitivity was found to be low in the full-thickness/partial tears of the long head of the biceps tendon (Table 1).

In the MRI examinations, the area under the ROC curve was calculated to be 0.918 in the diagnosis of full-thickness tears of the supraspinatus tendon (Figure 4). The area under the ROC curve was calculated to be 0.906 in the diagnosis of partial tears of the supraspinatus tendon. The area under the ROC curve was calculated to be 0.696 in the diagnosis of partial tears of the long head of the biceps tendon (Figure 5).

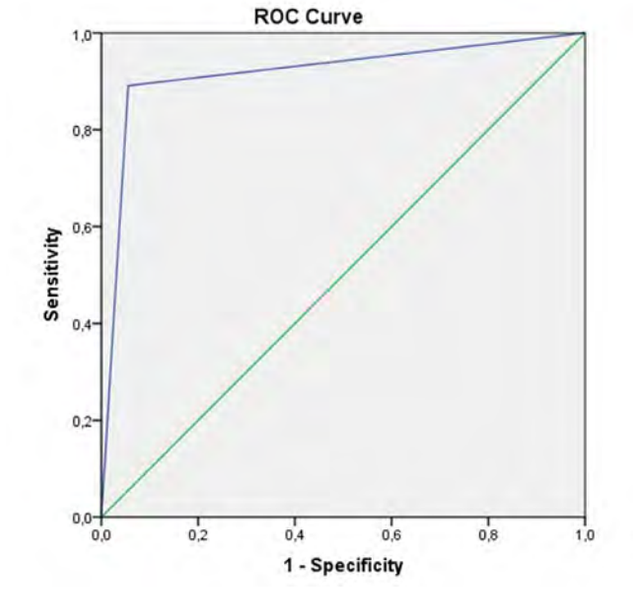

Figure 4. The ROC curve showing the MRI diagnostic performance in the supraspinatus tendon full-thickness tears compared with arthroscopy (The area under the ROC curve in the confidence interval of 0.837-0.999 is 0.918).

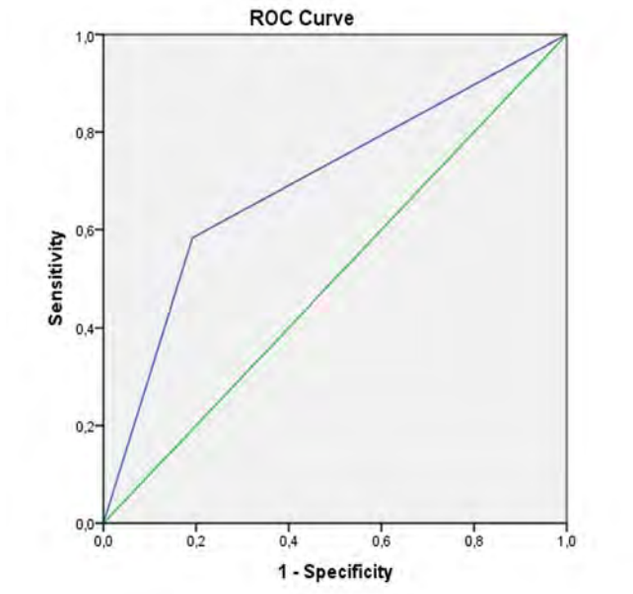

Figure 5. The ROC curve showing the MRI diagnostic performance in the partial tears of the long head of the biceps tendon compared with arthroscopy (The area under the ROC curve in the confidence interval of 0.517-0.874 is 0.696).

Discussion

MRI is an extremely important diagnostic tool in displaying the anatomy and pathologies of the shoulder joint and especially in displaying the rotator cuff lesions [5,6]. Arthroscopy is an invasive method for the diagnosis and treatment that directly shows the internal structures of the shoulder joint [5]. The correct diagnosis of pathologies is necessary to select medical or surgical treatment as well as to plan the specific surgical procedure. Furthermore, preoperative imaging reduces the duration of arthroscopy [6].

The rotator cuff consists of the supraspinatus, infraspinatus, subscapularis, and teres minor tendons. The most common tendon tear is observed in the supraspinatus tendon as it is in our study [1,2]. The tendon tear observed most rarely is the tear of the teres minor tendon, which was not detected in our cases.

In a study conducted by Owen et al. [5] on 31 cases, the accuracy of MRI was found to be 90% without making a distinction between full-thickness and partial tears of the supraspinatus tendon. While Magee et al. [6] determined the sensitivity of MRI to be 100% and specificity to be 87% in the diagnosis of the supraspinatus tendon tear, they determined the sensitivity of MRI to be at a low value of 56% in the detection of partial tears. In our study, the accuracy was found to be 90% in the full-thickness tears and 89% in the partial tears of the supraspinatus tendon, and the sensitivity and specificity values were found to be high.

The second most common rotator cuff tear after the supraspinatus tendon tear is the subscapularis tendon tear. In the study conducted by Malavolta et al. [7], 78% sensitivity and 86% specificity were obtained at 82% accuracy in 93 cases compared with arthroscopy in subscapularis tears. Pfirrmann et al. [8]. reported 91% sensitivity in subscapularis tears. In a

study of Choo et al. [9], 92.5% sensitivity and 64% specificity were found in subscapularis tears. Recent studies have reported 25-80% sensitivity and 91-100% specificity in MRI in the subscapularis tear [10,11]. In our study, the sensitivity and specificity findings in full-thickness/partial tears of the subscapularis tendon were found to be consistent with the literature.

No specific studies have been conducted on other tendons forming the rotator cuff, and studies including all the tendons forming the rotator cuff have been conducted in the literature. In a study conducted by Torstensen et al. [12], sensitivity was found to be 96% and specificity was found to be 49% in 24 cases in the distinction of partial/full-thickness tears of the rotator cuff and sensitivity was found to be 89% and specificity was found to be 41% in the distinction of full-thickness/partial tears of the rotator cuff. Kautzner et al. [13]. reported that the most effective diagnostic tool was MRI and that sensitivity was 92% and specificity was 100% in rotator cuff tears. In a study conducted with 56 patients, Vlychou et al. [14] found that the diagnostic performance of MRI in partial tears was at 97.7% sensitivity, 63.6% specificity, and 91% accuracy. In a study conducted by Bhatnagar et al. [15], 91% sensitivity and 100% specificity were found in the diagnosis of rotator cuff tears, without making a distinction between full-thickness and partial tears.

Among the meta-analysis studies conducted, 73% sensitivity and 74% specificity were found in a meta-analysis study conducted by Roy et al. [16] on the diagnostic accuracy of rotator cuff tears. 84-96% sensitivity and 84-95% specificity were found in full-thickness tears, and 50-82% sensitivity and 88-99% specificity were found in partial tears. De Jesus et al. [17] obtained 85.5% sensitivity and 94.5% specificity in a meta-analysis study conducted on the studies on the MRI's distinction of rotator cuff tears. In another analysis, Smith et al. [18] found 91% sensitivity and 97% specificity of full-thickness tears and 80% sensitivity and 95% specificity of partial tears. MRI is a reliable diagnostic method for full-thickness tears, with quite a high sensitivity of 100% reported [19]. In partial tears, sensitivity is in the range of 35-92% [19,20]. In our study, the sensitivity and specificity values were found to be high, in consistency with the literature.

In a study conducted by Malavolta et al. [21], they found that sensitivity was 67% and specificity was 98% in the diagnosis of the tears of the long head of the biceps tendon with MRI. In a study conducted by Razmjou et al. [22], sensitivity was found to be 54% and specificity was found to be 98% in full-thickness tears of the long head of the biceps tendon and sensitivity was 27% and specificity was 86% in partial tears. Similarly, in the study of Dubrow et al. [23], sensitivity was found to be 56.3% and specificity was found to be 98% in full-thickness tears of the long head of the biceps tendon and sensitivity was found to be 27.7% and specificity was found to be 84.2% in partial tears. Mohtadi et al. [24] found that sensitivity was 100% and specificity was 94% in full-thickness tears of the long head of the biceps tendon and sensitivity was 50% and specificity was 69.82% in partial tears of the long head of the biceps tendon. In a study conducted with 23 patients, Beall et al. [25] determined 79% accuracy, 52% sensitivity, and 86% specificity in full-thickness/partial tears of the long head of the biceps. In our study, sensitivity was found to be low in the tears of the long head of the biceps tendon, especially in partial tears, in a consistent way with the literature. We think that this is due to the fact that the number of full-thickness tears is low and that in partial tears, the fluid in the bicipital groove around the tendon causes mistakes in the interpretation of the partial tear in MRI. Tears of the long head of the biceps tendon accompany rotator cuff tears and serve as supporters of the rotator cuff tendons [25]. Our study supports this, and the partial tears of the long head of the biceps tendon accompany rotator cuff tears.

There are a few limitations in our study. Firstly, arthroscopy was considered to be the reference method in our study. There may be traps and misdiagnoses during arthroscopy. For example, intratendinous tears of the rotator cuff tendons, when the tendons do not contact with any surface, are not visible during arthroscopy [24]. At the same time, it may cause limitations in the distinction between full-thickness and partial tears [24]. Secondly, although arthroscopy was performed blindly, MRI images were taken by the musculoskeletal system radiologist knowing that the study was conducted on tendons. Thirdly, the number of the studies is relatively low, especially in terms of tears other than supraspinatus tendon tears. Finally, our study includes the routine shoulder MRI protocol with a 1.5 Tesla MRI device used retrospectively at our hospital. The specific position for the tendons does not include invasive assessments such as different sequences and MR arthrography. However, we believe that the current study we have conducted can be suitable for the evaluation.

A lot of different studies and meta-analyses have been carried out on the diagnosis of the pathologies of the rotator cuff tendons with MRI. Our study supports this. Differently, in our study, the update of the information was performed together with the evaluation of the pathologies in the long head of the biceps tendon, which is the supporter of the rotator cuff tendons. The association of single tendon or multiple tendon pathologies was compared (Table 2).

Conclusion

In magnetic resonance imaging, high accuracy, high sensitivity and specificity in the strong consistency range with the kappa value (kappa value: 0.78) were found in rotator cuff tendon pathologies, especially in supraspinatus tendon tears. However, sensitivity was determined to be low in the pathologies of the long head of the biceps tendon. These values can be observed at higher levels in studies to be conducted with developing technological MRI techniques and high-resolution (3 tesla) MR devices. Nowadays, MRI remains to be a reliable diagnostic method in shoulder tendon pathologies, especially in rotator cuff tendons.

Competing interests

The authors declare that they have no competing interests.

Ethical Responsibilities

No animal or human studies were carried out by the authors for this article.

Funding

The funders had no role in study design, data collection and analysis, decision to publish, or preparation of the manuscript.

References

1. Hermans J, Luime JJ, Meuffels DE, Reijman M, Simel DL, Bierma-Zeinstra SM. Does this patient with shoulder pain have rotator cuff disease?: The Rational Clinical Examination systematic review. Jama 2013;310 (8):837-47.
2. Nazarian LN, Jacobson JA, Benson CB, Bancroft LW, Bedi A, McShane JM, et al. Imaging algorithms for evaluating suspected rotator cuff disease: Society of Radiologists in Ultrasound consensus conference statement. Radiology 2013;267(2):589-95.
3. Ditsios K, Agathangelidis F, Boutsiadis A, Karataglis D, Papadopoulos P. Long head of the biceps pathology combined with rotator cuff tears. Adv Orthop 2012; 405472.
4. Joshi UP, Puri S. Clinical, MRI and arthroscopic correlation in anterior and posterior shoulder instability. Int J Res Med Sci. 2014; 2(3):857-60.
5. Owen RS, Iannotti JP, Kneeland JB, Dalinka MK, Deren JA, Oleaga L. Shoulder after surgery: MR imaging with surgical validation. Radiology 1993;186(2):443-7.
6. Magee TH, Gaenslen ES, Seitz R, Hinson GA, Wetzel LH. MR imaging of the shoulder after surgery. AJR Am J Roentgenol 1997; 68:925-8.
7. Malavolta EA, Assunção JH, Guglielmetti CL, de Souza FF, Gracitelli ME, Bordalo-Rodrigues M, et al. "Accuracy of preoperative MRI in the diagnosis of subscapularis tears." Archives of orthopaedic and trauma surgery 2016;136(10):1425-30.
8. Pfirrmann CW, Zanetti M, Weishaupt D, Gerber C, Hodler J. Subscapularis Tendon Tears: Detection and Grading at MR Arthrography 1. Radiology 1999 ;213(3):709-14.
9. Choo HJ, Lee SJ, Kim OH, Seo SS, Kim JH. Comparison of three-dimensional isotropic T1-weighted fast spin-echo MR arthrography with two-dimensional MR arthrography of the shoulder. Radiology 2012;262(3):921-31.
10. Adams CR, Brady PC, Koo SS, Narbona P, Arrigoni P, Karnes GJ, et al. A systematic approach for diagnosing subscapularis tendon tears with preoperative magnetic resonance imaging scans. Arthroscopy: The Journal of Arthroscopic & Related Surgery. 2012 ;28(11):1592-600.
11. Gyftopoulos S, O' Donnell J, Shah NP, Goss J, Babb J, Recht MP. Correlation of MRI with arthroscopy for the evaluation of the subscapularis tendon: a musculoskeletal division's experience. Skeletal radiology 2013;42(9):1269-75
12.Torstensen ET, Hollinshead RM. Comparison of magnetic resonance imaging and arthroscopy in the evaluation of shoulder pathology. J Shoulder Elbow Surg. 1999;8(1):42-5.
13. Kautzner J, Smetana P, Krotka I, Kos P, Frei R, Trc T. [Shoulder joint disorder: correlation of findings by arthroscopy and magnetic resonance imaging]. Acta Chir Orthop Traumatol Cech. 2008;75(3):190-5.
14. Vlychou M, Dailiana Z, Fotiadou A, Papanagiotou M, Fezoulidis IV, Malizos K. Symptomatic partial rotator cuff tears: diagnostic performance of ultrasound and magnetic resonance imaging with surgical correlation. Acta Radiol. 2009 ;50(1):101-5.
15. Bhatnagar A, Bhonsle S, Mehta S. Correlation between MRI and arthroscopy in diagnosis of shoulder pathology. J Clin Diagn Res. 2016;10(2):18-21.
16. Roy JS, Braën C, Leblond J, Desmeules F, Dionne CE, MacDermid JC, et al. Diagnostic accuracy of ultra-sonography, MRI and MR arthrography in the characterisationof rotator cuff disorders: a meta-analysis. Br J Sports Med. 2015;49(20):1316-28.
17. De Jesus JO, Parker L, Frangos AJ, Nazarian LN. Accuracy of MRI, MR arthrography, and ultrasound in the diagnosis of rotator cuff tears: a meta-analysis. AJR Am J Roentgenol. 2009;192(6):1701-7.
18. Smith TO, Daniell H, Geere JA, Toms AP, Hing CB. The diagnostic accuracy of MRI for the detection of partial-and full-thickness rotator cuff tears in adults. Magnetic resonance imaging 2012;30(3):336-46.
19. Balich SM, Sheley RC, Brown TR, Sauser DD, Quinn SF. MR imaging of the rotator cuff tendon: interobserver agreement and analysis of interpretive errors. Radiology 1997;204(1):191-4.
20. Malavolta EA, Assunção JH, Guglielmetti CL, de Souza FF, Gracitelli ME, Bordalo-Rodrigues M, et al. Accuracy of preoperative MRI in the diagnosis of subscapularis tears. Arch Orthop Trauma Surg. 2016;136(10):1425-30.
21. Malavolta EA, Assunção JH, Guglielmetti CL, de Souza FF, Gracitelli ME, Ferreira Neto AA. Accuracy of preoperative MRI in the diagnosis of disorders of the long head of the biceps tendon. Eur J Radiol. 2015;84(11):2250-4.
22. Razmjou H, Fournier-Gosselin S, Christakis M, Pennings A, ElMaraghy A, Holtby R. Accuracy of magnetic resonance imaging in detecting biceps pathology in patients with rotator cuff disorders: comparison with arthroscopy. J Shoulder Elbow Surg. 2016;25(1):38-44.
23. Dubrow SA, Streit JJ, Shishani Y, Robbin MR, Gobezie R. Diagnostic accuracy in detecting tears in the proximal biceps tendon using standard nonenhancing shoulder MRI. J Sports Med. 2014;5: 81-7.
24. Mohtadi NG, Vellet AD, Clark ML, Hollinshead RM, Sasyniuk TM, Fick GH, et al. A prospective, double-blind comparison of magnetic resonance imaging and arthroscopy in the evaluation of patients presenting with shoulder pain. J Shoulder Elbow Surg. 2004;13(3):258-65.
25. Beall DP, Williamson EE, Ly JQ, Adkins MC, Emery RL, Jones TP, et al. Association of biceps tendon tears with rotator cuff abnormalities: degree of correlation with tears of the anterior and superior portions of the rotator cuff. American Journal of Roentgenology 2003;180(3): 633-9.

How to cite this article:
Şahan MH, Serbest S, Tiftikçi U, İnal M, Burulday V. Reliability of Magnetic Resonance Imaging in Rotator Cuff and Biceps Tendon Pathologies. J Clin Anal Med 2017;8(suppl 4): 310-5.