Late-diagnosed penetrating stab Wounds in diaphragm and herniation

Delici-kesici alete bağlı geç tanı almış diyafragma yaralanmaları ve herniasyon

Penetrating stab wounds in diaphragm and herniation

Mehmet Tolga Kafadar[1], Mehmet Ali Gök[1], Volkan Öter[2]
[1]Clinic of General Surgery, [2]Clinic of General Surgery Division of Gastrointestinal Surgery,
Mehmet Akif İnan Training and Research Hospital Şanlıurfa, Turkey

Öz

Amaç: Travmatik diyafragma rüptürü, künt veya kesici-delici yaralanmaların iyi bilinen, ancak kolaylıkla gözden kaçabilen önemli bir komplikasyonudur. Bu çalışmanın amacı, delici-kesici alete bağlı geç tanı almış diyafragma yaralanmaları konusunda merkezimizin deneyimlerini aktarmaktır. Gereç ve Yöntem: Ocak 2016- Mayıs 2017 tarihleri arasında kliniğinimizde tedavi edilen, travmatik diyafragma rüptürü sonrası diafragmatik herniasyon saptanan yedi hastanın kayıtları retrospektif olarak incelendi. Bulgular: Hastaların 6'sı erkek, 1'i kadın ve yaş ortalamaları 28.2 (20-45) idi. Geç tanı alan hastaların travmatik yaralanma sonrası hastaneye başvuru ortalama süreleri 3.8 (2-6) aydı. Hastaların tümünde diyafragmanın sol tarafında yaralanma vardı. Diafragmatik yaralanmalarda ortalama defekt genişliği 6.9 (3-10) cm idi. Dört hastaya laparatomi, 3 hastaya ise laparoskopi ile fıtık kesesi eksizyonu ve diafragma onarımı uygulandı. Ameliyat esnasında ve sonrasında morbidite ve mortalite gözlenmedi. Tartışma: Delici kesici alete bağlı diyafragma yaralanmalarında ameliyat öncesi tanı koymak zordur. Özellikle abdomino-torakal bölgenin künt ya da penetran yaralanmalarından sonra diyafragma rüptürünün olabileceğinin akla getirilmesi erken tanı ve tedavi için önemlidir.

Anahtar Kelimeler

Penetre Travma; Diafragma; Geç Tanı

Abstract

Aim: Traumatic diaphragm rupture is a well known, but easily overlooked, complication of blunt or sharp injuries. The aim of this study was to convey our experience of traumatic diaphragm injuries with delayed diagnosis. Material and Method: Between January 2016 and May 2017, the records of a total of seven patients with diaphragmatic herniation after traumatic diaphragmatic rupture treated in our clinic were retrospectively reviewed. Results: Six of the patients were male, one patient was female and the mean age was 28.2 (20-45). The mean follow-up period of patients with delayed diagnosis after traumatic injury was 3.8 (2-6) months. All of the patients had an injury on the left side of the diaphragm. The mean defect width in diaphragmatic injuries was 6.9 (3-10) cm. Four patients underwent laparotomy and 3 patients underwent laparoscopy with hernia excision and diaphragm repair. No morbidity and mortality were observed during or after the operation. Discussion: It is difficult to diagnose penetrating diaphragm injuries before surgery. It is especially important for early diagnosis and treatment to remember that diaphragm rupture may occur after blunt or penetrating injury of the abdominal- thoracic region.

Keywords

Penetrating Trauma; Diaphragm; Late Diagnosis

DOI: 10.4328/JCAM.5103 Received: 23.05.2017 Accepted: 04.06.2017 Printed: 01.12.2017 J Clin Anal Med 2017;8(suppl 4): 367-9
Corresponding Author: Mehmet Tolga Kafadar, Mehmet Akif İnan Training and Research Hospital Clinic of General Surgery, 63300, Şanlıurfa, Turkey.
T.: +90 4143186000 F.: +90 4143186707 E-Mail: drtolgakafadar@hotmail.com

Introduction

Three out of four cases of traumatic diaphragm ruptures (TDR) that arise from thoraco-abdominal injuries are related to non-penetrating injuries, while one out of four is related to penetrating injuries [1]. In the immediate post-trauma period TDR is very hard to diagnose if there are no specific symptoms or radiologic findings. Some cases may not be diagnosed until many years later. Increasing morbidity and mortality due to rupture is related to late diagnosis of such cases. The cases that are not initially diagnosed may lead to complications of gastrointestinal herniation, strangulation, or sepsis [2]. In this study we provide the experiences of our center with regard to late-diagnosed penetrated diaphragm injuries.

Material and Method

In this study, the records of seven cases of herniation that arose from late-diagnosed TDRs were examined retrospectively. This study differs from other studies because it examines the records of late-diagnosed cases between 2016 January – 2017 May at the General Surgery Clinic of Health Sciences University Mehmet Akif İnan Training and Research Hospital. The demographic features of patients such as age and gender, chest x-ray, tomography results, diagnosis duration, surgery duration, amount of bleeding in the surgery operation, post-operative monitoring. and rate of morbidity and mortality were noted. Informed consents were obtained from the patients who participated in this study.

Results

Six male patients and 1 female patient were examined; the mean age was 28.2 (20-45). These patients had been followed up conservatively in various centers because no sharp object wounds were found on the diaphragm. Subsequently, they applied to the emergency service or general surgery polyclinic of our hospital with the complaints of respiratory distress, hematemesis, stomach ache, and chest pain. All the patients were monitored for diagnosis by chest x-ray and thoracic abdominal tomography, which are routinely performed when there is a suspicion of TDR. The mean duration between trauma and application to our hospital was 3.8 (2-6) months. All of the patients had injuries on the left side of the diaphragm. Three patients had thoracic herniation at the stomach and omentum, while four patients had thoracic herniation only at the omentum (Fig. 1a,b,c,d). The average width of the defect at the diaphragm wounds was 6.9 cm (Fig. 1e). Four patients received laparotomy and three patients received laparoscopic hernia sac excision and diaphragm repair (Fig. 1f). Five patients received primary diaphragm repair, and dual mesh was used for two patients after diaphragm repair. The average surgery period was 95 (60-140) minutes. During the surgery the amount of bleeding averaged 120 (25-400) ml. The average hospitalization duration was 3.4 (2-5) days. No morbidity or mortality were recorded during or after the surgery.

Discussion

The serious complications of diaphragm rupture in the late period are associated with herniation of the abdominal visceral organs [3]. TDRs are usually accompanied by injuries. In some cases the diagnosis is made immediately after the trauma, while in some it may only be diagnosed after many years [4]. In a meta-analysis of 980 cases, Shah et al. found that the rate of the late diagnosis was 14.6%. Early diagnosis can be done only if there is a suspicion of diaphragm rupture [5]. Therefore, when there are sharp object injuries at the lower chest and sides of the upper abdomen, diaphragm wounds should be suspected [6]. As a result of elective thoracoscopy performed 6 months after the trauma, Uribe RA et al. found that 9 (32%) of 28 patients with left thoraco-abdominal injuries had diaphragm

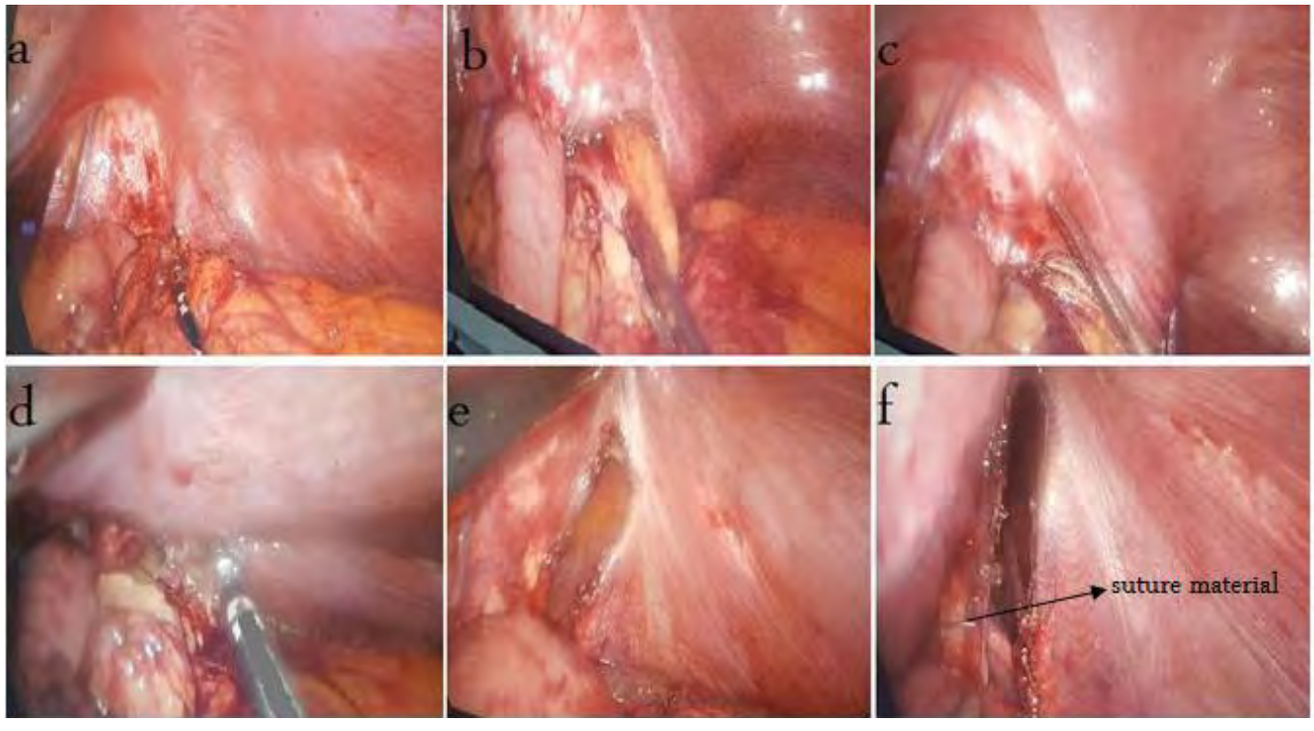

Figure 1. View of the left diaphragm with laparoscopic approach. (a,b,c,d) Omentum and stomach fundus in the diaphragmatic hernia sac (e) defect area after the hernia sac excision (f) repair of the diaphragm

wounds that weren't found during the pre-operative examinations [7]. The diagnosis was not made within the first injury trauma period for any of our seven patients.

Traumatic diaphragm rupture diagnosis can be made through complaints of the patient, findings of physical examinations, serial chest x-rays, baric gastrointestinal system x-ray, thoracoabdominal x-ray, magnetic resonance, thoracoscopy, or laparoscopy [8]. If a nasogastric tube is bent at the thorax, this finding helps the diagnosis. Direct radiology can reveal the following: the integrity of the diaphragm is lost, plural haustra of intestine and gas areas are observed in the thorax, the diaphragm is observed above its normal anatomic position, pleural effusion, atelectasis, bulk observation in the lungs, mediastinal shift, pneumothorax, and hydro pneumothorax [9].

According to its clinical presentation, the herniation of traumatic diaphragm has three phases: acute phase, latent phase, and obstructive phase. The acute phase starts just after the injury and continues until the stab wound recovers. In this period the injuries of the diaphragm may not be noticed due to hemodynamic instability related to injuries of the visceral organs and vascular tissues. Latent phase or interval phase is a period when the thoraco-abdominal injuries are asymptomatic after the recovery of the injuries. In this period the ruptured area of the diaphragm is covered by the abdominal organs, which slowly herniate toward the thorax. Ischemia, obstruction, and strangulation findings are observed in this chronic obstructive period. Most of the diagnosis and treatment plans of the patients whose problems couldn't be diagnosed at the acute phase are completed in this period [10]. In our study, all of our patients were diagnosed and treated in the chronic obstructive period after the patients became symptomatic.

It is inevitable to have herniation of the abdominal organs at the unnoticed ruptures in the acute period following the trauma. During the Valsalva maneuver the pressure difference between abdomen and thorax, which is normally 2-10 mmHg, increases to 100 mmHg [11]. The herniated organs may vary depending on the diameter of the defect on the diaphragm and features of the adjacent organs of the defected area. Mostly the stomach, small intestine, and colon, and rarely the liver and spleen, are herniated [12]. After the TDR it is possible to observe stomach or colon herniation together with strangulation or intra-thoracic perforation. This situation leads to increasing morbidity and mortality in the following period [13]. In our patients we observed incarceration at the herniated organs of our patients, but no strangulation.

The optimal treatment for TDR is the repair of defects for the cases of early diagnosis. In this phase the abdominal surgery methods must be chosen considering the possibility of the injury of adjacent organs. When such a method is not applied, then thoraco-abdominal or separate thoracic incision may be required. In recent years the laparoscopic approaches also have been widely applied. The primary repair of the diaphragm with unabsorbed sutures is generally the preferred method. In cases with big defects that are not suitable for primary closure, using an appropriate non-absorbable polypropylene graft or dual graft to close the defect is suggested [14,15].

Conclusion

The most important tool for the diagnosis of traumatic diaphragm injury is to suspect rupture of the diaphragm after the obtuse or penetrating injury of the abdominal thoracic area. During the abdominal surgery of such patients, both hemi-diaphragms must be explored carefully. For patients receiving conservative treatment, diagnostic laparoscopy must be performed before discharge. The diaphragm must be repaired through primary suture and/or by using graft for the patients found to have diaphragm rupture.

All procedures performed in this study involving human participants were in accordance with the ethical standards of the institutional and/or national research committee and with the 1964 Helsinki declaration and its later amendments or comparable ethical standards.

Informed Consent

Informed consents were obtained from patients who participated in this study.

Competing interests

No conflict of interest was declared by the authors.

Financial Disclosure

The authors declared that this study has received no financial support.

References

1. Mihos P, Potaris K, Gakidis J, Paraskevopoulos J, Varvatsoulis P, Gougoutas B, et al. Traumatic rupture of the diaphragm: experience with 65 patients. Injury 2003;34(3):169-72.
2. Lu J, Wang B, Che X, Li X, Qiu G, He S, et al. Delayed traumatic diaphragmatic hernia: A case-series report and literature review. Medicine (Baltimore) 2016;95(32):e4362.
3. Christophi C. Diagnosis of traumatic diaphragmatic hernia: analysis of 63 cases. World J Surg 1993;7(2):277-80.
4. Leiva Flores JR, Ramírez Rivera JI, Ramírez Rivera ME. Late presentation of traumatic diaphragmatic hernia. Cir Pediatr 2016;29(2):82-4.
5. Shah R, Sabanathan S, Mearns AJ, Choudhury AK. Traumatic rupture of diaphragm. Ann Thorac Surg 1995;60(5):1444-9.
6. Thiam O, Konate I, Gueye ML, Toure AO, Seck M, Cisse M, et al. Traumatic diaphragmatic injuries: epidemiological, diagnostic and therapeutic aspects. Springerplus 2016;5(1):1614.
7. Uribe RA, Pachon CE, Frame SB, Enderson BL, Escobar F, Garcia GA. A prospective evaluation of thoracoscopy for the diagnosis of penetrating thoracoabdominal trauma. J Trauma 1994;37(4):650-4.
8. Selman S, Küpelioğlu R, Aydemir D, Karahan S, Doğan Y. Traumatic diaphragmatic hernias. Ulusal Travma Derg 1995;1(2):155-7.
9. Hammer MM, Raptis DA, Mellnick VM, Bhalla S, Raptis CA. Traumatic injuries of the diaphragm: overview of imaging findings and diagnosis. Abdom Radiol (NY) 2017;42(4):1020-7.
10. Apaydın B, Zengin K, Göziş G, Taşkın M. Traumatic diaphragmatic ruptures. Ulusal Travma Derg 1997;3(2):142-7.
11. Athanassiadi K, Kalavrouziotis G, Athanassiou M, Vernikos P, Skrekas G, Poultsidi A, et al. Blunt diaphragmatic rupture. Eur J Cardiothorac Surg 1999;15(4):469-74.
12. Petrone P, Asensio JA, Marini CP. Diaphragmatic injuries and post-traumatic diaphragmatic hernias. Curr Probl Surg 2017;54(1):11-32.
13. Özoğul B, Kısaoğlu A, Öztürk G, Atamanalp SS, Aydın Y, Aydınlı B, et al. Does a penetrating diaphragm injury have an effect on morbidity and mortality? Turkish Journal of Trauma & Emergency Surgery 2013;19(1):45-8.
14. Ercan M, Aziret M, Karaman K, Bostancı B, Akoğlu M. Dual mesh repair for a large diaphragmatic hernia defect: An unusual case report. Int J Surg Case Rep 2016;28(2):266-9.
15. Mjoli M, Oosthuizen G, Clarke D, Madiba T. Laparoscopy in the diagnosis and repair of diaphragmatic injuries in left-side penetrating thoracoabdominal trauma: laparoscopy in trauma. Surg Endosc 2015;29(3):747-52.

How to cite this article:
Kafadar MT, Gök MA, Öter V. Late-Diagnosed Penetrating Stab Wounds in Diaphragm and Herniation. J Clin Anal Med 2017;8(suppl 4): 367-9.