Original Research
JCAM

An MRI study of various parts of pons

MRI study

Mohammad Reza Salahshoor[1], Shiva Roshankhah[1], Cyrus Jalili1, Farzad Rajaei[2]
[1]Department of Anatomical Sciences, Medical School, Kermanshah University of Medical Sciences, Kermanshah,
[2]Department of Anatomy, Faculty of Medicine, Qazvin University of Medical Sciences, Qazvin, Iran

Abstract

Aim: In the field of neuroanatomy, morphometric studies on many parts of the brain are still not accessible. The appearance of magnetic Resonance Imaging (MRI) method has made it possible to reply many questions in this field. Material and Method: The dimensions of target parts were calculated by the MRI-associated measuring system and recorded along with the height of the patients. Results: The data showed a significant correlation between diverse parts of pons and the height in men ($p<0.05$). Among women, except for the length of tegmentum and the height of basal part of pons, significant correlations were found between height and the dimensions obtained for other parts of the pons ($p<0.05$). Discussion: The dimensions of different parts of pons in tall men and women were bigger than those in short ones.

Keywords

Magnetic Resonance Imaging; Pons; Height

DOI: 10.4328/JCAM.5469 Received: 18.03.2017 Accepted: 26.05.2017 Printed: 01.12.2017 J Clin Anal Med 2017;8(suppl 4): 412-6
Corresponding Author: Farzad Rajaei, Department of Anatomy, Faculty of Medicine, Qazvin University of Medical Sciences, Qazvin, Iran.
GSM: 0098-9122817421 E-Mail: Rajaei@qums.ac.ir

Introduction

With the advent of MRI and the possibility of producing precise and wonderful images from human brain at different planes, it is now possible to reply many unclear questions related with the effect of various factors such as height on human brain [1]. In the field of anatomy, mainly neuroanatomy, morphometric studies on many parts of the body are still not accessible and this maybe has been associated with the absence or unavailability of such equipments to previous scientists. Present data in neuroanatomy texts regarding the dimensions of different parts of the brain is restricted to major parts and usually one dimensional and little information on details of different sizes is available [2]. As the previous morphometric studies were done on cadavers through open brain surgeries and because of postmortem changes especially atrophy, and also inaccessibility to many parts of the brain in three-dimensional form in a live person, it is essential the current information attained from alive and healthy individual using new method to be compared with previously recorded cases. Hence, in present study effort has been made to study different dimensions of some parts of the pons in more details. This leads to generation of data associated with the size of these parts and further comparison of these values with height will give rise to results which can help broadening the horizon of the knowledge of anatomy. Since many pathologic cases including, syndromes, drugs and toxic agents can cause alterations in size of these parts [3], the present study could be helpful in identifying the racial difference regarding the size of target parts, difference in size of pons in live and dead humans and lastly, determining the size of different parts of pons in accordance with height. Previous works has mostly focused on the volume of pons [4 and 5] without reference to dimensions of several parts of this organ and only concentrated on the volume of some parts of the pons in men and women at different ages [6,7,8 and 9]. Considering the functions of pons, the importance of lesions involving this organ [10 and 11], and lack of information, it seems that performing morphometric studies on pons to determine and record the dimensions of different parts and also the effect of height on dimensions of these parts, to be crucial in enlightening such information.

Material and Method

This was an experimental study carried out on three hundred peoples referred to MRI center at Imam Reza hospital in Kermanshah (Iran). Forms were used to collect data from patients with demands for brain MRI. The data including height, history of earlier diseases were documented. However, only the patients with no history of any kind of diseases and with normal state of health were included in our study. The patient was located in a supine position while the subject's jaw was as close as possible to the chest and the Orbito Metal Base Line (OMBL) in a position vertical to bed surface. This is of major importance to make comparable investigations in different people. The MRI tool used in our study was a Phillips product (Netherlands), version 2009, a 20-inch LCD monitor, with an intensity of 2 Tessla, 4mm thickness at posterior cavity and 0.7 mm GAP. Following imaging process, morphometric studies were carried out using images with no rotation and artifacts selected based on evidence obtained through forms and also the report of MRI specialist on health state of brain for each patient. At next step, following the preparation of various sagittal, coronal, and axial views, the best T1 views, based on standard researches were selected for anatomical studies [11 and 12]. Using the device measuring system and also marking the image ends at two different points, the measurements were measured in mm (Fig1).



Figure 1. The axial view for morphometric study of transverse length of pons.

Regarding the lack of symmetry and regular geometric shape in parts under study, measurements were done at diverse directions and the biggest value was taken as the actual length. Repeating this procedure on other sections gave rise in generation of values, among those, the largest ones were adopted as real height, length, and width for the structure under study (Fig 2).

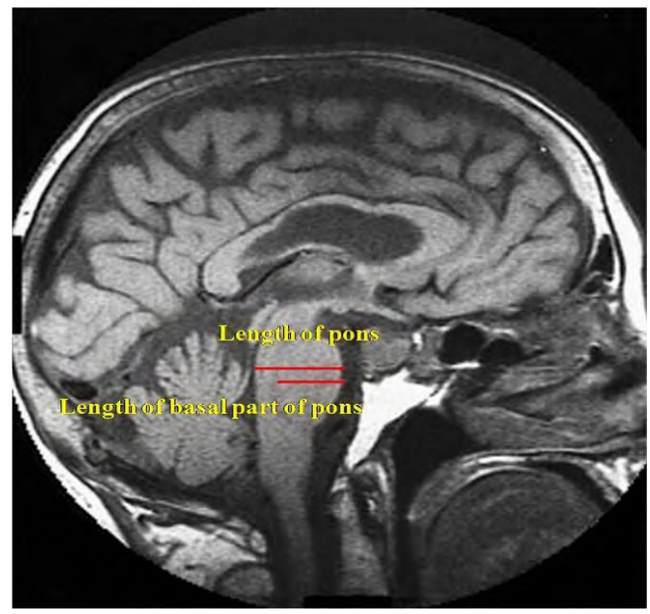

Figure 2. The Midsagital view for morphometric study of length of pons and basal part of pons.

Efforts were made to perform the same type of study on different persons using clear anatomical sections such as midsagital ones particularly in morphometric studies of pons (Fig 3).

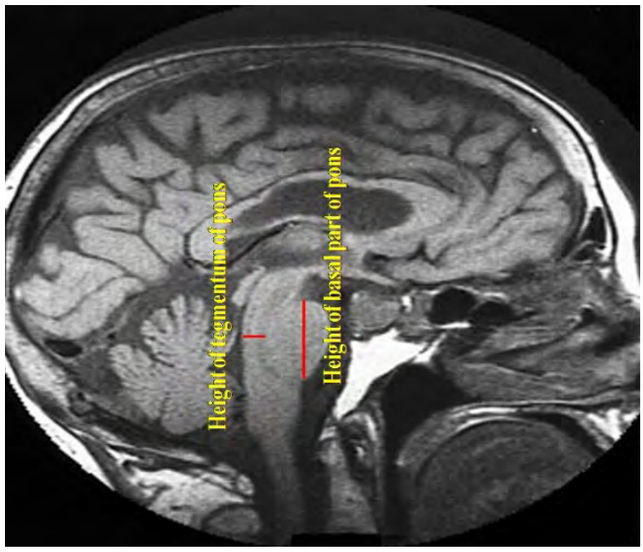

Figure 3. The Midsagital view for morphometric study of the height of basal and tegmentum part of pons.

Considering all preconditions, the patient was allowed to be included in our study. Thus, out of many patients, three hundred cases meeting all the requirements were involved in our study. Regarding the ethical considerations, special codes were used instead of actual names when filling forms or studying MRI images. Furthermore, all patients provided the study group with individually signed consensus forms while no obligation or extra costs were imposed.

Statistical examines were performed by using t test, Pearson's correlation coefficient and regression. Differences between groups with P value of 0.05 or less to be considered as significant.

Results

A total of three hundred healthy peoples including 124 males (41.3%) and 176 females (58.7%) aged between one and eighty-five years, were studied. The patients were divided into five groups Based on their height (table 1).

Table 1. Distribution of study groups based on their height

Height (cm)	49-149	150-159	160-169	170-179	180-200
Number of people	27	54	102	87	30
Percentage	8.7	18	34	29	10.3

Following the necessary investigations on study groups, the dimensions of different parts were obtained in millimeter. The size of various parts in five height groups is presented in table 2.

The information showed that there was significant correlation between different parts of pons and the height in men ($p<0.05$). Among women, except for the length of tegmentum and the height of basal part of pons, significant correlations were found between height and the dimensions obtained for other parts of the pons ($p<0.05$). Correlation and regression coefficients for those parts of the pons showing significant relationship with height were as follows: Height of tegmentum of pons: 15.10+0.03× (body height). Length of pons: 15.16+0.04× (body height). Length of basilar of pons: 11.55+0.03× (body height). Transverse length of pons: 17.84+0.06× (body height). Length of tegmentum of pons: 3.76+0.00× (body height). Height of basal of pons: 16.59+0.05× (body height). It means that when height increases by 1 mm, a value of 0.03 mm will be added to the Height of tegmentum of pons.

Discussion

The current study which was aimed to morphometrically investigate the pons and evaluating the effects of height on dimensions of pons, resulted in determination of sizes of different parts of the pons in accordance with height; a set of information unavailable in current reference anatomical texts so far. Furthermore, our data are suggestive of the presence of a size-associated correlation between the dimensions of various parts of pons with height as shown by the greater values for totally parts of pons in tall men compared to short ones. This relationship was only significant in few parts of pons in women and no significant correlation between the length of tegmentum, height of basilar of pons and the height of body was recognized. In general, the size of pons in tall individuals is bigger than that of shorter ones. Studies on healthy people pons using MRI only equated the volume of basilar of pons between two sexes considering the effect of age with no refer-

Table 2. Dimensions of different parts of pons in mm in different height groups (figures in brackets stand for standard deviation)

Height (cm)	Part of pons	49-149	150-159	160-169	170-179	180-200
Transverse length of pons	Male	23.94 (2.689)	26.83 (1.185)	26.99 (1.259)	27.51 (1.375)	27.91 (1.240)
	Female	22.45 (2.834)	26.34 (1.564)	26.89 (1.234)	27.11 (1.98)	27.26 (1.321)
Length of tegmentum of pons	Male	4.33 (0.485)	4.51 (0.621)	4.41 (0.574)	4.58 (4.70)	4.70 (0.47)
	Female	4.13 (0.53)	4.11 (0.78)	4.151 (0.186)	4.08 (4.66)	4.50 (0.12)
Length of basal part of pons	Male	14.83 (1.043)	16.85 (1.318)	17.01 (1.242)	17.8 (1.114)	17.43 (0.992)
	Female	13.13 (1.145)	16.56 (1.225)	16.88 (1.170)	17.63 (1.112)	17.03 (0.920)
Length of pons	Male	19.33 (1.495)	21.15 (1.122)	21.35 (1.367)	21.68 (1.233)	22.09 (1.164)
	Female	18.73 (1.528)	20.34 (1.409)	21.11 (1.225)	21.41 (1.175)	21.55 (1.99)
Height of basal part of pons	Male	22.06 (2.287)	23.81 (1.056)	24.42 (1.190)	24.65 (1.277)	25.7 (1.490)
	Female	21.12 (2.342)	21.01 (1.112)	22.22 (1.576)	21.05 (1088)	23.22 (1.481)
Height of tegmentum of pons	Male	19.06 (1.862)	20.43 (1.098)	20.81 (1.123)	20.96 (1.050)	21.65 (1.369)
	Female	18.22 (1.155)	19.78 (1.132)	20.34 (1.170)	20.86 (1.070)	20.98 (1.144)

ence to sizes of pons [11, 12 and 13], while the present study bears such information. In agreement with the study mentioned above, following morphometric study of different parts of pons by MRI and further comparison of results according to age and sex in healthy people, showed that some parts of pons such as transverse length, length of tegmentum, height of basilar, and height of tegmentum were larger than those of women with a significant correlation between some parts of pons and age increase [14], but no reference to possible relationship between dimensions of different parts of pons and height of individuals was made. A study of Koh et al, on Korean healthy youths, revealed that there is a direct relationship between the volume of brain and their height, confirmed by the data obtained in our study [15]. Also, they emphasized on lack of an obvious relationship between height and the volume of brain in women, consistent with data found in present work. The result of Raz et al., show that effect of body size, in particular the height, on different parts of pons, completed and supported by our findings [16]. In studies on basketball players by MRI, stressed on volume increase in some parts of their brains compared to normal people which could be attributed to higher height among those players supporting our data [17]. Several other studies related with pons have been carried out using MRI in which evaluations were made between healthy people and those with pathologic lesions such as multiple sclerosis [18 and 19], and further diseases [20 and 21], thus, the outcomes of present study due to its characteristics could help diagnosing such diseases more efficiently mainly those producing changes in dimension of pons [22]. The reason for changes in size of pons in accordance with age among men and lack of such effects in women is not clear as there are many uncertainties regarding the precise function of different parts of pons and also the association of these parts with genetic, sex and hormonal and hence needs further investigations. Finally, according to the findings of this study, it seems that the current study to be a distinctive work in which regardless of different factors including, genetic, hormonal, and environmental conditions not only provides information on sizes of diverse parts of pons, but also investigates the possible relationship between sizes of pons and height increase among two sexes. Moreover, concerning enormous ambiguities on exact function of different parts of pons and also the role and diversity of effectors, further studies are of prime urgency and the present work could be regarded as an opening to such investigations.

Conclusion

The sizes of different parts of pons in tall men were bigger than those in short ones. Among females, except for the length of tegmentum and the height of basal part of pons, the dimensions for other parts of pons in tall women were bigger that those obtained for short women.

Acknowledegment

We would like to thank the Deputy to Research Department of Qazvin University of Medical Sciences for funding the present study and also Dr Jahani Hashemi for statistical analysis and Dr Nazari, for his sincere cooperation.

Scientific Responsibility Statement

The authors declare that they are responsible for the article's scientific content including study design, data collection, analysis and interpretation, writing, some of the main line, or all of the preparation and scientific review of the contents and approval of the final version of the article.

Animal and human rights statement

All procedures performed in this study were in accordance with the ethical standards of the institutional and/or national research committee and with the 1964 Helsinki declaration and its later amendments or comparable ethical standards. No animal or human studies were carried out by the authors for this article.

Funding

This study was founded by the Deputy of Research Department of Qazvin University of Medical Sciences.

Conflict of interest

None of the authors received any type of financial support that could be considered potential conflict of interest regarding the manuscript or its submission.

References

1. Jong LW, Vidal JS, Forsberg LE, Zijdenbos AP, Haight T, Sigurdsson S, et al. Allometric scaling of brain regions to intra-cranial volume: An epidemiological MRI study. Human Brain Mapping. 2017;38(1):151-64.
2. Lerch JP, van der Kouwe AJ, Raznahan A, Paus T, Johansen-Berg H, Miller KL, et al. Studying neuroanatomy using MRI. Nature Neuroscience. 2017;20(3):314-26.
3. Liu RS, Lemieux L, Bell GS, Sisodiya SM, Bartlett PA, Shorvon SD, et al. Cerebral Damage in Epilepsy: A Population-based Longitudinal Quantitative MRI Study. Epilepsia. 2005;46(9):1482-94.
4. Lambert C, Chowdhury R, FitzGerald TH, Fleming SM, Lutti A, Hutton C, et al. Characterizing aging in the human brainstem using quantitative multimodal MRI analysis. Front. Hum. Neurosci. v7 i462. 2013.
5. Wu D, Chang L, Akazawa K, Oishi K, Skranes J, Ernst T, et al. Mapping the critical gestational age at birth that alters brain development in preterm-born infants using multi-modal MRI. NeuroImage. 2017; 149: 33-43.
6. Wu YT, Shyu KK, Jao CW, Liao YL, Wang TY, Wu HM, et al. Quantifying cerebellar atrophy in multiple system atrophy of the cerebellar type (MSA-C) using three-dimensional gyrification index analysis. Neuroimage. 2012;61(1):1-9.
7. Vannucci RC, Barron TF, Lerro D, Antón SC, Vannucci SJ. Craniometric measures during development using MRI. Neuroimage. 2011;56(4):1855-64.
8. Belkhiria C, Driss T, Habas C, Jaafar H, Guillevin R, de Marco G. Exploration and Identification of Cortico-Cerebellar-Brainstem Closed Loop During a Motivational-Motor Task: an fMRI Study. The Cerebellum. 2016;7:1-4.
9. Zeng H, Wen F, Huang W, Gan Y, Zeng W, Chen R, et al. New Findings, Classification and Long-Term Follow-Up Study Based on MRI Characterization of Brainstem Encephalitis Induced by Enterovirus 71. PloS one. 2016;11(10):e0162877.
10. Shah SA, Doraiswamy PM, Husain MM, Figiel GS, Boyko OB, McDonald WM, et al. Assessment of posterior fossa structures with midsagittal MRI: the effects of age. Neurobiology of aging. 1991;2(4):371-4.
11. Raz N, Gunning-Dixon F, Head D, Williamson A, Acker JD. Age and sex differences in the cerebellum and the ventral pons: a prospective MR study of healthy adults. American Journal of Neuroradiology. 2001;22(6):1161-7.
12. Monteith SJ, Medel R, Kassell NF, Wintermark M, Eames M, Snell J, et al. Transcranial magnetic resonance–guided focused ultrasound surgery for trigeminal neuralgia: a cadaveric and laboratory feasibility study: Laboratory investigation. Journal of neurosurgery. 2013;118(2):319-28.
13. Sullivan EV, Rosenbloom M, Serventi KL, Pfefferbaum A. Effects of age and sex on volumes of the thalamus, pons, and cortex. Neurobiology of aging. 2004 Feb 29;25(2):185-92.
14. Rajaei F, Salahshoor MR, Hashemi HJ, Haghdoost-Yazdi H, Pahlevan AA. Morphometric study on dimensions of various parts of pons and comparison of data in accordance with age and sex of healthy people by MRI. Neurological research. 2009;31(10):1075-8.
15. Koh I, Lee MS, Lee NJ, Park KW, Kim KH, Kim H. Body size effect on brain volume in Korean youth. Neuroreport. 2005;16(18):2029-32.
16. Raz N, Rodrigue KM, Kennedy KM, Dahle C, Head D, Acker JD. Differential age-related changes in the regional metencephalic volumes in humans: a 5-year follow-up. Neuroscience letters. 2003;349(3):163-6.
17. Park IS, Han JW, Lee KJ, Lee NJ, Lee WT, Park KA, et al. Evaluation of morphological plasticity in the cerebella of basketball players with MRI. Journal of Korean

medical science. 2006;21(2):342-6.
18. Hagiwara A, Hori M, Yokoyama K, Takemura MY, Andica C, Tabata T, et al. Synthetic MRI in the Detection of Multiple Sclerosis Plaques. American Journal of Neuroradiology. 2017;38(2):257-63.
19. Filippi M, Rocca MA, Ciccarelli O, De Stefano N, Evangelou N, Kappos L, et al. MRI criteria for the diagnosis of multiple sclerosis: MAGNIMS consensus guidelines. The Lancet Neurology. 2016;15(3):292-303.
20. Fujii Y, Aida N, Niwa T, Enokizono M, Nozawa K, Inoue T. A small pons as a characteristic finding in Down syndrome: A quantitative MRI study. Brain and Development. 2017 Apr 30;39(4):298-305.
21. Budhram A, Pelikan JB, Kremenchutzky M, Sharma M. The 'across the pons' sign: A possible novel radiographic finding in natalizumab-associated progressive multifocal leukoencephalopathy. Journal of the Neurological Sciences. 2017;375:304-6.
22. Sullivan EV, Rosenbloom MJ, Serventi KL, Deshmukh A, Pfefferbaum A. Effects of alcohol dependence comorbidity and antipsychotic medication on volumes of the thalamus and pons in schizophrenia. American Journal of Psychiatry. 2003;160(6):1110-6.

How to cite this article:
Salahshoor MR, Roshankhah S, Jalili C, Rajaei F. An MRI study of various parts of pons. J Clin Anal Med 2017;8(suppl 4): 412-6.